I—Reproduction in the Common Shrew (*Sorex araneus* Linnæus)

I—The Œstrous Cycle of the Female

By F. W. Rogers Brambell

(*From the Department of Zoology, University College of North Wales, Bangor*)

(Communicated by A. S. Parkes, F.R.S.—Received August 1—Read November 13, 1934)

[Plates 1–8]

CONTENTS

VOL. CCXXV.—B 518 with INDEX TO VOL. CCXXIV. (Price 15*s.*) [Published May 22, 1935.

I—INTRODUCTION

This paper describes the reproductive processes of the Common Shrew so far as they can be determined from animals caught in the wild state. No account seems to have been given of the œstrous cycle of this species and existing knowledge regarding its life history and breeding habits is far from adequate. This is remarkable since shrews can be obtained readily in almost any rural district on the mainland of Great Britain. An admirable summary of the earlier work is given by BARRETT-HAMILTON (1911), and little further information, except that provided by MIDDLETON (1931), has been added. The embryology up to the formation of the geminal layers and the development of the placenta have been described by HUBRECHT (1890, 1894). The anatomy of the shrew has been described by ÄRNBÄCK-CHRISTIE-LINDE (1907), but little attention is paid to the female reproductive organs.

II—TECHNIQUE

The major part of the material was obtained by trapping, chiefly with break-back mouse traps of the " Nipper " type baited with shelled hazel nuts, and set in runs or near holes in grass and undergrowth. They were visited once or twice a day. Box traps were also employed, but were not found to be satisfactory as shrews live only a very short time when caught in them and the percentage catch is much lower than with the other type. Shrews were found to be plentiful in every site where trapping was carried out. In addition to trapping, a few animals were caught alive by hand and others were picked up dead in the course of the field work. The number, date, body-weight, sex, locality, and fixative employed were recorded for each animal. The material was also graded as " alive," " fresh dead," or " dead." Any other particulars revealed by dissection were also recorded. The histological technique was standardized throughout to obtain uniformity. The reproductive organs were removed whole as soon as possible and fixed in the alcoholic modification of Bouin's fluid. A few animals were fixed whole in the field in 10% formalin after an incision had been made in the abdominal wall. The mammary glands of adult animals during the breeding season were preserved except when damaged or dissected under field conditions. The fur was removed with barium sulphide and the skin and mammary glands were dissected off, stretched on cork and fixed in alcoholic Bouin's fluid.

The material remained in the fixative overnight and was then transferred to 70% alcohol. The ovaries with the Fallopian tubes attached were severed from the uteri. The uterine cornua were separated from the vagina at the cervix and the bladder was removed. The ovaries, uteri, and vagina of each animal were then upgraded and embedded in one block. Uteri which were visibly pregnant were not embedded, but were stored in 70% alcohol until the embryos could be weighed. It was found that the weight of the uterus together with the contained embryos, divided by the number of embryos, provided a satisfactory criterion for seriating these stages of pregnancy. The weights of the embryos with the membranes removed and the head-rump length were also recorded when the embryos were sufficiently large to be removed from the uterus without damage.

Complete serial sections were made of both ovaries, together with the attached Fallopian tubes, of all animals which were not definitely immature and also of a number of immature animals selected as representing those obtained during each month. Complete serial sections were made of the uteri of all animals which had corpora lutea in the ovaries but in which neither tubal ova nor visible uterine pregnancies were observed. This was done to determine early uterine stages of pregnancy. Transverse sections of the uteri and of the upper and lower regions of the vagina were made of almost all adults and many immature animals. All sections were cut at 10 μ and were stained with Mayer's hæmalum and eosin.

The mammary glands were stained in Borax Carmine, differentiated in acid alcohol, upgraded, and cleared in xylol and phenol and then in pure xylol. Each gland was kept flat between plates of glass during this process. The glands were dissected off the skin after clearing in most cases, and were mounted whole, the smaller ones in balsam on a slide, the rest between pieces of glass in xylol in museum jars. The covers of the museum jars were sealed with "Durofix."

The larger follicles and the corpora lutea in the ovaries of all adult animals were counted and measured. This was done by making outline drawings of them by means of a vertical projection apparatus working at × 125 diameters. The outline of each follicle or corpus luteum was then measured in two directions at right angles and the mean was taken as the diameter × 125. The measurements for the growth of the ovum and follicle (p. 26) were made in this way, but a greater magnification was employed for the smaller follicles.

III—MATERIAL AND CLASSIFICATION

The total material consisted of 1064 Common Shrews of which 487 were females. It was obtained between May, 1931, and August, 1933, from a number of localities in Wales and England.

Collecting was carried out continuously in the vicinity of Bangor from the middle of May, 1931, until the end of June, 1932, and afterwards intermittently. The numbers obtained each month from each locality are given in Table I.

TABLE I

Month	Anglesey	Caernarvon-shire	Denbigh-shire	Dorset	Hertford-shire	Kent	Middle-sex	Total
1931								
May	—	20	—	—	—	—	—	20
June	—	12	—	—	—	—	—	12
July	2	39	—	—	—	—	—	41
August . . .	—	41	—	3	—	118	—	162
September .	—	45	—	—	—	5	—	50
October . .	—	43	—	—	—	—	—	43
November .	—	6	—	—	—	—	—	6
December .	—	10	—	—	—	—	1	11
1932								
January . .	—	33	—	—	—	—	5	38
February . .	4	64	—	—	—	—	2	70
March . . .	21	50	2	—	—	—	1	74
April	42	102	12	—	—	—	—	156
May	29	110	4	—	—	—	—	143
June	—	117	—	—	—	—	—	117
September .	—	11	—	—	19	—	—	30
October . .	—	19	—	—	10	—	—	29
November .	—	10	—	—	7	—	—	17
December .	—	10	—	—	—	—	—	10
1933								
May	—	8	—	—	—	—	—	8
July . . .	5	—	—	—	—	—	—	5
August . . .	7	15	—	—	—	—	—	22
Totals . .	110	765	18	3	36	123	9	1,064

It can be seen that 893 animals were obtained in North Wales, most of which were taken within a radius of 2 miles from Bangor. The remainder of the material, with the exception of 3 animals from Dorset, was obtained in the Home Counties.

The 36 animals obtained during the autumn of 1932 in Hertfordshire require special mention. They were all obtained on one farm near Hitchin. Of these 9, all of which were adult, were caught by hand in barley stubble when the stooks were being carted ; 16 adults and about 10 immature animals, of which all the adults and 2 immature animals were preserved and are recorded, were caught in clover stubble. About 15 animals were trapped of which 1 was adult and the others immature. The adult and 8 of the immature animals were preserved and are recorded above. Elsewhere during the months of September, October, and November, 4 adults and 135 immature animals were trapped and 1 adult was picked up dead. Thus a great preponderance of immature animals were trapped during these months both in Hertfordshire and elsewhere. The fact that of approximately 35 animals caught in barley and clover stubbles 25 were adults clearly indicates that for some obscure reason this method of obtaining material favoured the taking of adults as compared with trapping.

The numbers of each sex obtained each month are given in Table II. The upper part of the table contains animals taken in the year in which they were born, the lower part animals in their second year.

TABLE II

Month	♂'s	♀'s	%
June	14	18	44
July	19	19	50
August	85	84	50
September	41	25	62
October	32	28	53
November	9	9	50
December	10	11	48
January	18	20	47
February	32	37	46
March	33	40	45
April	104	52	67
May	106	65	62
June	50	47	51
July	2	6	44
August	8	7	
September	6	8	
October	6	6	
November	2	3	
December	—	—	—
January	—	—	—
February	—	1	—
March	—	1	—
Total	577	487	54

The sex-ratio in shrews, if the total material is to be taken as a random sample, is 54 ± 1·03 males %. Middleton (1931) records 192 males and 119 females which represents a sex-ratio of 62 ± 1·86 males %, and Adams (1910) records 104 males and 97 females, a ratio of 52 ± 2·38 males %. Examination of the monthly ratios discloses high values, over 60%, in September of the first season and in April and May of the second season. Since the sex-ratio of the population can scarcely be supposed to change to this extent it must be assumed that trapping resulted in differential selection of the sexes. Consequently it is evident that female shrews are more difficult to catch than are males in April and May. This period is characterized by the onset of the first œstrus in the female.

The classification of the material did not present much difficulty in the majority of cases. The animals approaching and during the first œstrus in spring were easily identified by the vaginal cornification, the non-parous condition of the uterus and the absence of corpora lutea in the ovaries.

The adult animals after the first œstrus fell into two groups according to whether or not corpora lutea were present in the ovaries. The former were by far the more numerous and all except four were found to be pregnant. The later uterine stages of pregnancy were identified macroscopically by the swellings on the uterus and were arranged approximately in order according to the mean weight of these swellings. In the latest stages the weight of the embryos with the membranes removed and their head-rump lengths were also taken into account. The tubal stages were identified microscopically, and were arranged in order. Complete serial sections were made of both uterine cornua of those animals with corpora lutea which did not fall into either of these two categories. All, except the four already mentioned, were found to contain unimplanted uterine blastocysts and were arranged approximately in order according to the diameter of the blastocysts. Eighty-eight of the ninety-nine pregnant animals were classified as either parous or non-parous from the condition of either the mammary glands or uteri or of both. The uteri could not, of course, be employed for this purpose in the late uterine stages and in these animals the mammary glands alone were relied upon. Unfortunately the mammary glands were not preserved in eleven of these, and they could not therefore be classified with certainty. Three of the eleven were obtained late in the season and were presumably parous. The other eight were obtained on or before May 25 and were probably non-parous since the earliest pregnancy in a definitely parous animal was obtained on May 18 and no others were obtained until May 29.

Three animals with old corpora lutea in an advanced stage of retrogression, large follicles and uteri showing unmistakable signs of very recent parturition were obviously in post-partum œstrus.

One animal (S. 4) presented difficulties, as it had fully developed corpora lutea showing no signs of retrogression, but no embryos were found. The condition of the uterus showed this animal to be non-parous. The active condition and stage of development of the corpora lutea was comparable with a stage of pregnancy with uterine blastocysts prior to implantation. Unfortunately, owing to an accident, the serial sections of the uterus and tubes were not complete and it is possible, therefore, that the animal was pregnant and that the blastocysts were lost with the missing sections. Otherwise this animal would have to be classified as diœstrus or pseudo-pregnant and in either group it would constitute the only example.

Adults which were parous, but in which corpora lutea were not present, were classified primarily according to the condition of the mammary glands. Eleven of these either were or had been recently lactating ; four were not lactating.

The inactive condition of the reproductive organs of two of these, obtained in February (S. 646), fig. 32, Plate 4, and fig. 56, Plate 8, and March (S. 559), fig. 36, Plate 5, enabled them to be classified as anœstrous animals, surviving until their second winter. One animal (S. 1257) which was obtained on August 1, although obviously parous, was neither lactating nor in post-partum œstrus. It had, however, large follicles up to 320 μ in diameter and the vagina was large with a thick nucleated epithelium and only epithelial cells in the lumen. It might therefore be regarded as either pro-œstrous or entering upon an œstrus, although the organs had not yet become atrophied. The remaining animal was obtained on November 2 (S. 1214). It had large uteri and ovaries with follicles up to 256 μ in diameter. The mammary glands were completely retrogressed, but the vaginal epithelium was thick and was definitely cornified next the lumen, fig. 49, Plate 7. Cornified material and leucocytes composed the vaginal contents. The vagina indicates that this animal was metœstrus, and both the size of the follicles and condition of the uteri are compatible with this. The absence of corpora lutea and of sperms shows that it did not ovulate and probably did not mate.

The mammary glands of one other animal (S. 240) were not preserved and consequently it could not be identified although the condition of the other organs was compatible with lactation anœstrus.

Most of the young animals in their first season were easily identified by their weight and the obviously undeveloped condition of the reproductive organs. A few in which the reproductive organs were unusually well developed were sectioned and were then easily identified as prepubertal by the small size of the largest follicles in the ovaries and the non-parous condition of the uteri.

Apart from those partial exceptions mentioned it was possible to classify all the material.

IV—STRUCTURE OF THE REPRODUCTIVE ORGANS

The ovary of the immature shrew or of the anœstrous adult is very small and smoothly oval in shape. That of the breeding animal is much larger and mulberry-like with the large follicles and corpora lutea projecting from its surface. It is attached by a broad base, or hilum, to the extremities of the broad ligament and of the suspensory ligament of the ovary. Rudiments of the mesonephric tubules of the parovarium and epovarium are situated in this region and the ovarian vessels enter here. The ovary is completely surrounded by a capsule, as noted by ÄRNBÄCK-CHRISTIE-LINDE (1907), which shuts off the periovarian cavity from the peritoneal cavity, figs. 12 and 13, Plate 1. This capsule is formed by a thin peritoneal membrane stretched between the convolutions of the Fallopian tube, which embrace the ovary, and united to the hilum. The ovarian portion of the tube is in the form of an S, the two extremities of which are bent at right angles to one another and which lap round the ovary, figs. 12 and 13, Plate 1. The opening into the periovarian cavity is funnel-shaped. This region is relatively thin walled, but its epithelial lining is thrown into a series of deep folds and crypts, figs. 37 and 38, Plate 5. The external diameter of the ovarian part of the tube is much greater than that of the uterine part, which retains a relatively simple lumen with the epithelium thrown into only a few shallow longitudinal folds, figs. 33-36, Plate 5. Its wall is much thicker than that of the ovarian part and is not convoluted. It runs along one side of the ovary to join the uterine cornu, which it enters near the tip on the mesometrial side. The Fallopian tube passes diagonally through the uterine wall and projects slightly into the uterine lumen, fig. 14, Plate 1. The uterine horns are nearly cylindrical in the non-pregnant shrew. The lumen in transverse section is roughly T-shaped, the " cross " of the T being on the mesometrial side, fig. 23, Plate 3, as has been described by Hubrecht (1894). The uterine glands are localized in the thickened pads of mucosa on each side of the slit-like anti-mesometrial part of the lumen. The two horns of the uterus, figs. 10 and 11, Plate 1, join to form the top of a T, of which the vagina is the stem, the lumen being continuous. The cervical canal is short and single and opens into the vaginal lumen by a deep external os uteri. The upper end of the vagina is bent back upon itself ventrally, figs. 10 and 11, Plate 1. This flexure is especially well marked in non-pregnant adult animals, and is necessitated by the relative shortness of the round ligaments and uteri on the one hand and the length of the vagina on the other. The nature of the vaginal wall changes abruptly at the level of the neck of the bladder, where its lumen is constricted by a circular fold of the mucosa, which is evidently homologous with the " hymen " described in the rabbit (1933) and the pig (1934) by Baxter. This author found that the " hymen " in these forms marked the lower limit of the müllerian component of the vagina. The curious fibrous connective tissue zone (see p. 40) between the muscularis and mucosa in non-parous animals, which corresponds with that found in the uteri, is present, fig. 43, Plate 6, in the vaginal wall above this " hymen " and absent below it. This suggests that the upper part of the vagina is of müllerian origin and that the lower limit of this component is defined by the " hymen " in the shrew also.

Posterior to the " hymen " the vaginal wall is thinner, fig. 44, Plate 6, the lumen is wider and the mucosa is arranged in more irregular folds which tend to be oblique or even transverse. The lower part of the vagina is flattened dorso-ventrally and the urethra runs in the tissues of its ventral wall. It merges with the urinogenital sinus, into which the urethra opens ventrally, without any abrupt change in the structure of its wall. The opening of the urethra is situated about half-way between the " hymen " and the external vulval orifice so that the urinogenital sinus is deep and tubular. The clitoris is small and inconspicuous.

There are three pairs of nipples in the inguinal region, fig. 53, Plate 8. The glands belonging to the anterior pair extend laterally around the side of the body immediately in front of the thigh. Their upper margins, when fully developed during lactation, lie close on each side of the vertebral crests. The glands of the second pair are bilobed. The larger lobes extend forward from the anterior margin of the vulva, almost meeting each other in the mid-ventral line. The smaller lobes are situated in the groin. Thus the nipple is situated between the two lobes of the gland. The posterior pair of glands are situated dorso-laterally to the nipples, each gland extending, when fully developed, from the lateral margin of the anus around the side of the body behind the thigh to the dorsal middle-line above the root of the tail. No thoracic mammary glands are developed.

V—Growth, Duration of Life, and Breeding Season

The body weights of 451 female shrews are plotted against the days of the year in fig. 1. The small dots represent non-parous non-pregnant animals, the large dots pregnant animals, and the circles non-pregnant parous animals. It can be seen that almost all the non-parous animals weigh between 5 and 7 gm during the first three months of the year. During April and May they increase in weight, the majority of pregnant or parous females in summer weighing 10 to 13 gm. The lightest pregnant or parous animals were over 6 gm and the heaviest, a late pregnancy, was 15 gm. There is thus considerable variation in the weights of adult females in summer. Both Adams (1910) and Middleton (1931) noticed the rapid increase in size during the spring months. Barrett-Hamilton (1911), quoting Adams, records that 18 adult females taken in May, June, and July, averaged 13·1 gm and ranged from 9 to 16 gm. Middleton (1931) provides data of 22 pregnant shrews taken during May, June, July, and August, ranging from 9 to 15 gm (exclusive of the weight of the embryos when these were 1 gm or over), which averaged 11 gm.

The lightest young animal obtained in summer was just over 4 gm but the majority were between 6 and 9 gm. The smallest obtained by Middleton (1931) was 5 gm and by Adams (1910) 6 gm. The weights of the young animals fall off during the last three months of the year. Middleton (1931) noticed a similar drop in the weight of the young animals in autumn. Adults can usually be distinguished by weight from the beginning of July till the following April. Only four parous or pregnant animals weighing less than 9 gm were obtained during this period ; one in July, two in August, and one in March. Four young animals weighing more than 9 gm were obtained ; two in August, one in November, and one in December.

Fig. 1 shows the decrease in the number of adult animals towards the close of the season and their scarcity after November (only two adults were obtained subsequently ; one in February and one in March). It is probable that the adults normally die off in late summer and autumn and only exceptionally live after November. There is no evidence that any ultimately survive and breed again.

It appears probable that the shrews normally die off earlier in the autumn in N. Wales than they do in S. England where the three adults obtained in November and the single one in February were obtained. Adams (1910) first put forward the theory that the adults all die off in the autumn of the season following that in which they are born, and believed that this accounts for the well-known " autumnal epidemic " among shrews, when large numbers of them are to be found dead, and to explain which many theories have been advanced. He bases this suggestion on the fact that between December and April he obtained immature animals only. He

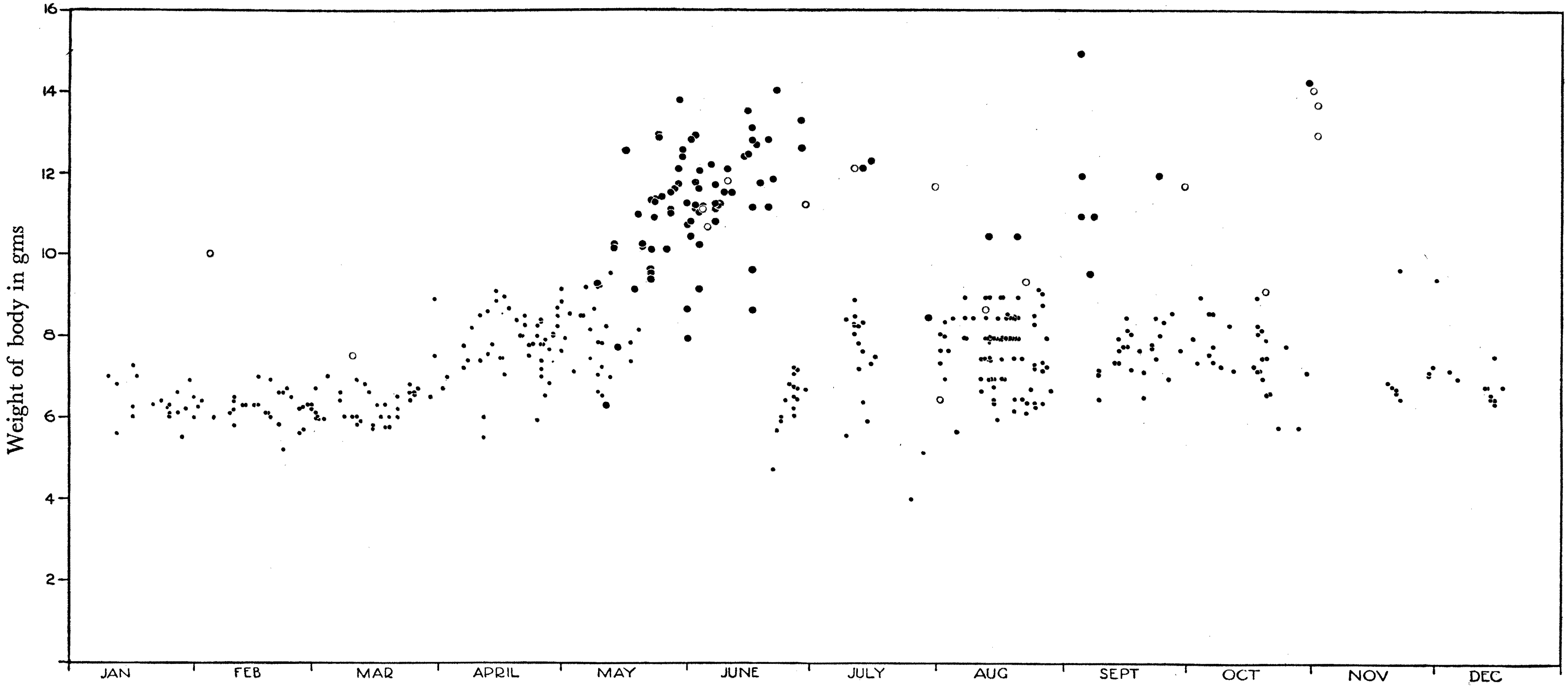

FIG. 1—Scatter diagram of the body-weights of females according to the days of the year

● = non-parous non-pregnant animals, ⬤ = pregnant animals, ○ = non-pregnant parous animals distinguished mature and immature animals by their size, condition of the reproductive organs, and by the scarring of the tail and feet and absence of hair on the former in adult males. MIDDLETON (1931) suggests that " after the short but prolific breeding season the old shrews gradually die out, so that none are left by the following winter," but no reference is made to the earlier work of ADAMS (1910).

Some young animals, presumably born earlier in the season, exhibit towards its close prepubertal development of the reproductive organs but there is no evidence that they attain œstrus. Since no non-parous œstrous animals were obtained after June and only one pregnant for the first time (S. 1143, see p. 45), there is ample evidence that females do not normally breed in the season in which they are born. BARRETT-HAMILTON (1911) says " there is as yet no evidence that the young breed during their first summer," and MIDDLETON (1931) suggests that " neither male nor female shrews become sexually mature and breed during the year of their birth." But ADAMS (1910) captured females on July 5 and November 21, 1909, which he states " though recently impregnated, had not previously littered." It may be concluded that female shrews live normally 15 to 18 months, surviving one winter and one breeding season only.

The breeding season, as shown by the occurrence of pregnant animals, extends from May to October inclusive. The total number of adults obtained each month is shown in Table III, together with the number of pregnant animals. All females are included under January to April, since all will presumably breed as soon as the season begins. Only adults from the previous year, and which are consequently parous, are included in November.

TABLE III

Month	Total No. of adults	No. of pregnancies
January	20	—
February	38	—
March	41	—
April	52	—
May	63	39
June	47	42
July	5	3
August	8	5
September	8	7
October	6	3
November	3	—
December	0	—

The earliest pregnant animal, if one with unsegmented tubal ova and spermatozoa in the vagina may be included in this category, was obtained on May 9 ; the latest on October 31. It should be noted, however, that all the pregnant animals obtained in October were from Hertfordshire, the latest pregnancy obtained in N. Wales being on September 24.

Two of the three adult animals obtained in November were either lactating or had been lactating very recently as shown by the mammary glands. Since these two animals were obtained during the first week of November in Hertfordshire they provide further evidence that breeding continues in this part of England until October.

The onset of the breeding season in the female, as indicated by pregnancies, takes place with remarkable suddenness, so that on and after May 20 all animals are either pregnant or parous. This is shown in Table IV of animals obtained in May.

TABLE IV

Date	Non-pregnant	Pregnant
May 1 to 8 inclusive	9	—
May 9 to 19 inclusive	15	8
May 20 to 31 inclusive	—	31

According to BARRETT-HAMILTON (1911), "The genital organs begin to become functional in February, and the rutting season commences in March," and "the young are born in every month from April, though rarely in that month, to late November." MILLAIS (1904) also gives the breeding season as extending from April till November and states that nests are found about the middle of April. ADAMS (1910) states that the breeding season lasts from the beginning of May till late November, with which statements the results of this investigation are in accord. Moreover, there are several records of nest young having been found in November. Recently MIDDLETON (1931) states that "No breeding takes place after August," which assertion is not supported by the present work.

The results obtained from the incidence of pregnancy are confirmed by the appearance of young animals in June, of which the first was obtained on 21st and many subsequently, as shown by Table V.

TABLE V

Date	Adults	Young
June 1 to 20 inclusive	38	—
June 21 to 30 inclusive	9	18

There is thus an interval of one month approximately between the time when all the animals were found to be pregnant and the appearance of young animals in the traps. Since the smallest animals trapped were almost certainly weaned this period corresponds well.

VI—FERTILITY

The total number of pregnant shrews obtained was 99. Only one other animal (S. 4) had corpora lutea which appeared to be functional and it is possible (see p. 6) that this was pregnant also. Thus ovulation results in pregnancy in 99 to 100% of cases and must therefore always be accompanied by copulation.

Between May 20 and July 31 when all animals have presumably had their first œstrus, 78 adult females were obtained of which 71, or almost 90%, were pregnant. Consequently during the earlier part of the breeding season they must become pregnant normally at the post-partum œstrus and both gestation and lactation must normally proceed *pari passu* in parous animals.

It must be concluded that the female shrew normally produces several successive litters in a season. Barrett-Hamilton (1911) suggests that two or even three litters are produced in a season, and Adams (1910) obtained pregnant females which had suckled previously. Middleton (1931) considers it uncertain whether females have more than one litter. The average size of litter is not known directly as no nests with young were obtained. The fact that the shrew has six nipples indicates that the litter size will not be much in excess of this number. It can be estimated with reasonable accuracy from the number of maturing follicles, of corpora lutea, and of embryos *in utero* in post-implantation stages of pregnancy.

A group of maturing follicles, clearly defined from the small follicles, can be identified in the ovaries of about one-third of the adult animals available for this purpose. In the other animals the largest follicles are not defined as a group owing to the presence of follicles of a size intermediate between them and the smaller follicles. A difference of at least 32 μ between the diameter of the largest of the smaller follicles and the smallest of the larger ones was taken as sufficient to define the group of maturing follicles. Using this criterion it was found that the number of follicles maturing together varied from 4 to 16 in the 48 animals available while the mean number was 8·35.

The number of corpora lutea in 97 complete sets is given in Table VI. The mean number of corpora lutea in a set is 7·35 and the most frequent number is 7. The mean corresponds well with the mean number of maturing follicles, viz., 8·35. Thus approximately 12% of the maturing follicles fail to ovulate. Five animals included in this table each contained one atretic corpus luteum in the centre of which the ovum was retained.

TABLE VI

No. of corpora lutea in set	No. of examples observed
4	1
5	3
6	13
7	40
8	29
9	8
10	2
11	—
12	1
Total	97

Data of 51 pregnancies were available for this purpose, ranging from stages in which implantation had taken place recently to stages approaching full time. The mean number of healthy embryos *in utero* in these 51 animals was 6·45. The actual numbers of healthy embryos varied from 1 to 9 and were distributed as shown in the second column of Table VII. The data, shown as compiled, in column three were derived from BARRETT-HAMILTON (1911), quoting ADAMS, MIDDLETON (1931), and HUBRECHT (1890, 1894) for comparison.

TABLE VII

No. of embryos in litter	No. of litters	
	Observed	Compiled
1	1	—
2	—	1
3	—	—
4	4	4
5	5	3
6	12	9
7	18	14
8	10	12
9	1	4
10	—	3
Total	51	50
Mean	6·45	6·94

Examination of the mean number of embryos *in utero* month by month shows that it is slightly higher in June than in May and that it falls off considerably in the later months of the season. This is brought out in Table VIII, where the number of embryos is given together with the number of corpora lutea, which were known in 49 animals, for each month. MIDDLETON (1931) observed a falling-off in the average size of litter in May, June, and July, and his data are given for comparison in the last two columns.

Comparison of the number of embryos with the number of corpora lutea provides a means of estimating the embryonic mortality. This will be an under-estimate since the pregnancies were not at full time. The percentage mortality calculated from these data is lower in June than in May, and is highest in August to October, whereas the mean number of corpora lutea found at each œstrus is approximately constant throughout the season. Embryonic mortality in this sense will include all loss of ova between ovulation and the stage of pregnancy attained by each animal when it was captured ; it will therefore include loss through lack of fertilization as well as loss of developing embryos. Thus the falling-off in the litter size, as shown by the mean number of embryos *in utero*, towards the end of the season is probably due to an

TABLE VIII

							Data from MIDDLETON (1931)	
Month	No. of pregnancies available	Total number of embryos	Mean number of embryos	Total number of corpora lutea	Mean number of corpora lutea at each ovulation	% mortality of ova ovulated	Number of pregnancies available	Mean number of embryos
May	22	150	6·8	159	7·2	5·7	11	7·4
June	17	119	7·0	125	7·4	4·8	6	6·8
July	—	—	—	—	—	—	4	6·0
August . . .	3	14	5·1	20	6·9	26·1	1	(5)
September . .	6	31		43			—	—
October . . .	1	6		6			—	—
Total . . .	49	320	6·5	353	7·2	9·3	22	6·9

increase in the embryonic mortality and not to a decrease in the number of ova ovulated. The mortality was confined to 18 of the 49 pregnancies available. There was a total discrepancy of 33 between the number of corpora lutea and the number of healthy embryos, seven of these being accounted for by reabsorbing embryos present in three animals as follows :— S. 954 obtained on May 24 with 8 corpora lutea, 1 reabsorbing and 7 healthy embryos ; S. 1161 on September 8 with 8 corpora lutea, 5 reabsorbing and 1 healthy embryo ; and S. 1254 on August 8 with 5 corpora lutea, 1 reabsorbing and 4 healthy embryos. The remaining ova have been lost without leaving macroscopically visible signs and must therefore either not have been fertilized or have been reabsorbed completely. It should be noted that reabsorption of pre-implantation stages would be undetected macroscopically. The mortality is shown according to the number of ova ovulated in Table IX. It can be seen that the mortality is very much greater when 8 or more ova are ovulated than it is with 7 or less.

TABLE IX

No. of ova ovulated	No. of pregnancies available	No. of pregnancies showing mortality	Total No. of ova lost	% mortality of ova ovulated
5	2	1	1	6·3
6	8	1	1	
7	21	7	11	
8	15	7	17	13·5
9	2	1	1	
10	1	1	2	
Total . . .	49	18	33	9·3

VII—General Nature of the Œstrous Cycle

a. Œstrus

The changes which lead up to the first œstrus are gradual and accompany the rapid growth in body size which is observed in all the animals in April and May. During this period the reproductive organs develop from very small dimensions to the normal size in non-parous adults. Whether these changes should be regarded as pubertal or pro-œstrous is uncertain. This distinction is purely academic since all the animals were non-parous. The vaginal cornification appears a long time before the œstrous condition is attained and gradually becomes more intense. At the same time the uterus develops and the follicles exhibit active growth. Prior to œstrus many of the growing follicles degenerate. The pro-œstrous condition merges into œstrus. The largest follicles in animals which had copulated, as shown by the presence of sperms, varied greatly in size. One animal which had copulated had no follicles larger than 232 μ in diameter, while another had follicles up to 328 μ in diameter. Other animals which had apparently not copulated, since no sperms could be found in them, had follicles as large as 296 μ. Sperms were present in some of the animals on and after April 29 and by May 20 all were pregnant. The sizes of the largest follicles in animals which had copulated and those which had not are shown in fig. 2. In view of the fact that the follicles of none of these animals contained ova exhibiting polar-body formation it is impossible to estimate the maximum size of the follicles at the first ovulation. It is probable that they frequently

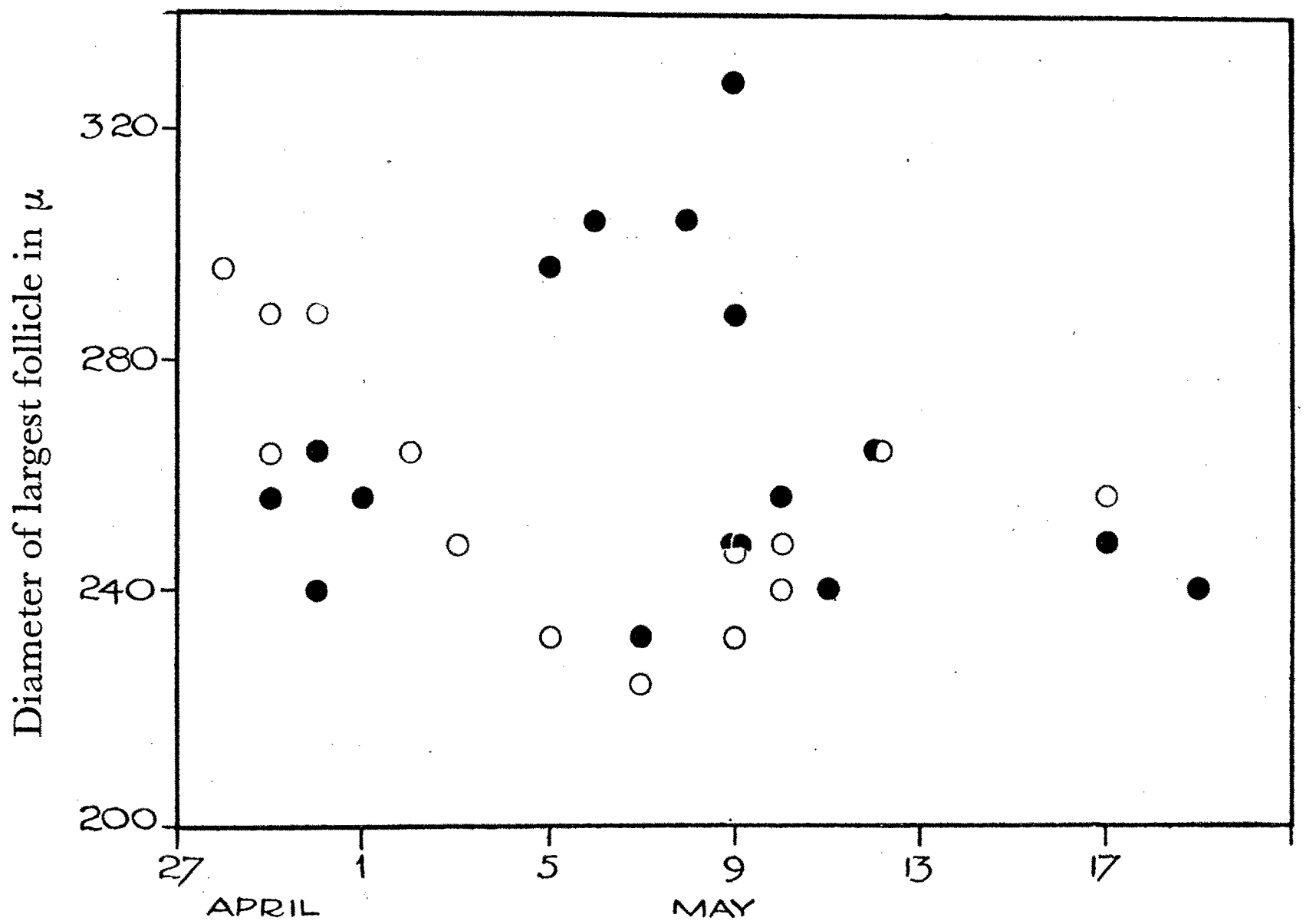

Fig. 2—The diameters of the largest follicles in non-pregnant non-parous animals obtained from April 28 to May 19 are shown. Animals which had copulated are shown as dots and those which had not as circles

increase considerably in size after copulation and prior to the formation in the ova of the first polar spindles.

There is an œstrous period in the shrew following quickly after parturition as shown by the condition of the uterus and the old corpora lutea. The vagina, unlike that of an animal in its first œstrus, is not cornified but its epithelium is thick, squamous and with all the cells nucleated, fig. 45, Plate 6. Three post-partum œstrous animals were available ; viz. S. 40, 1030, and 1033, which were obtained in the first half of June. The largest follicles in these animals were respectively 304, 320 and 328 μ in diameter. The oocytes in the group of large follicles about to ovulate in S. 40 and 1030 contained vesicular nuclei which had not yet entered upon polar-body formation. The oocytes in the maturing follicles, fig. 39, Plate 5, of S. 1033 exhibited first polar spindles and were therefore approaching ovulation. S. 40 had not copulated, but the two other animals had done so recently, as shown by the masses of spermatozoa in the vaginæ and uteri and their absence from the Fallopian tubes, which evidently they had not had time to ascend. The semen in the vagina of S. 1030 formed a solid plug distending its walls. This vaginal plug, the only one found, was not hard like that of the mouse, but sectioned easily without special treatment.

Apart from these three post-partum animals no other parous animals, which could be definitely identified as œstrous, were obtained.

Copulation normally precedes ovulation. All animals with recent corpora lutea were pregnant with the single possible exception of S. 4. It is remarkable, if ovulation occurs spontaneously, that non-pregnant animals with corpora lutea in the ovaries were not found. This and the occurrence of non-pregnant lactating animals without corpora lutea in the ovaries, since such animals presumably had a post-partum œstrus, suggests that ovulation may not be spontaneous.

The high rate of fertility, which results apparently in copulation being followed by pregnancy in 100% of cases, accounts for the fact that no pseudo-pregnant animals, with the possible but very doubtful exception of S. 4, were obtained. The absence of such animals, however, clearly does not provide evidence that sterile copulation would not result in pseudo-pregnancy, but merely indicates that sterile copulation is extremely rare.

The fact that only 3 animals in post-partum œstrus were obtained as compared to 53 parous pregnant animals, a ratio of 1 : 18, suggests that the duration of the post-partum œstrus is approximately 1/18th of the period of gestation.

b. Pregnancy

(i) *Passage of ova through the Fallopian tubes*—The early development of the shrew has been described by Hubrecht (1890), but the earliest stages (Cat. No. 16) which he obtained were blastocysts free in the uterus. Since, in the present work, 18 animals with tubal ova were available it seems desirable to outline their passage through the tubes. The first polar spindle is formed in the ovum before ovulation.

Fertilization takes place in the ovarian part of the tube while the ova are still surrounded by the cumulus of cells of the discus proligerus. This cumulus is retained for a variable time, being present in some 4-cell stages and absent from others. It is absent from the ova in both the animals with 2-cell stages. Five animals containing 4-cell stages were obtained, in all of which some of the ova were in the ovarian parts of the Fallopian tubes, but in three some of the ova were in the uterine portions. The 8-cell and subsequent stages were all in the uterine parts of the tubes and were all without any traces of a cumulus. The embryos when they pass from the Fallopian tubes into the uterine cornua are early blastocysts about the stage of those figured by HUBRECHT (1890, Cat. No. 16). Since 18 of the 99 pregnancies were tubal stages it would appear that approximately 2/11 of the period of gestation elapses before the ova reach the uterus. Blastocysts were present free in the uterine lumen in 29 pregnant animals. It is probable, from the number of animals in which the ova were found grouped together in the uterine lumen at the distal extremity close to the opening of the Fallopian tube, that they remain in this region for some time. Later they become spread throughout the length of the cornua. Soon the blastocysts become located in spherical chambers formed by local distensions of the uterine lumen and, owing to their increasing size, cannot escape from these by passing through the relatively narrow portions connecting the chambers.

The most advanced blastocysts, the presence of which could not be determined macroscopically by the swellings which appear on the uterus, were at the stage described by HUBRECHT (Cat. No. 52). They were beginning to adhere in places to the uterine mucosa lining the walls of the chambers in which they were situated ; obviously the initial stage of implantation. Thus half of the pregnant animals contained embryos prior to implantation, which process may therefore be supposed to take place about the middle of the period of gestation.

(ii) *Effect of lactation on implantation*—The difference in the relative frequency of the various stages in the animals gestating their first litters and in the parous animals which were pregnant is remarkable. It may be assumed for this purpose, in view of the dates on which they were obtained, that the 8 late stages obtained on or before May 25 and the 2 obtained in August, which could not be classified owing to the mammary glands not being available, were respectively non-parous and parous. The numbers of tubal, pre-implantation and post-implantation uterine stages in the first and subsequent pregnancies are summarized in Table X.

TABLE X

Stage	Pregnancies 1st	Pregnancies Subsequent
Tubal ova	7	11
Blastocysts free in lumen of uterus	3	26
Implanted embryos	32	20
Total	42	57

Comparison of these numbers suggests that implantation is delayed in second and subsequent pregnancies relative to first pregnancies. It is well known that in the mouse and the rat the period of gestation is considerably lengthened in lactating animals. KIRKHAM (1916 and 1918) has shown that this is due to delay in the implantation of the embryos, which occurs normally on the 5th day of gestation (19 days), but which takes place in lactating animals about the 14th day.

Parturition in lactating mice is correspondingly delayed from 8 to 16 days (MIRSKAIA and CREW, 1931) and in lactating rats from 2 to 14 days (HAIN, 1934). The data given here are insufficient to warrant too much reliance being placed upon them, but they suggest that implantation may be delayed by lactation, as it is in the mouse, since the majority of shrews pregnant for the second or subsequent time were suckling simultaneously.

(iii) *Duration of pregnancy*—It is possible to estimate the actual period of gestation from the times when non-parous and parous pregnant animals and young ones were obtained. These data are represented graphically in fig. 3. Thus 34 of the 99 pregnant animals were known to be non-parous and were obtained between May 9 and June 3 inclusive with a single exception, S. 1143 (see p. 45). The 54 animals which were known to be parous and pregnant were obtained on or after May 29, with one exception obtained on 18th. It can be seen that there is a period of 15 days between the last occurrence of non-pregnant animals and the last occurrence of animals gestating their first litters. There is a comparable period of 20 days between the first non-parous pregnant and the first parous pregnant animals excepting that obtained on May 18. There is no doubt that the period of lactation must coincide closely with that of gestation. This is shown by the fact that the active mammary glands in lactating pregnant animals reach a maximum development during the latter part of pregnancy and begin to retrogress before parturition. This is supported

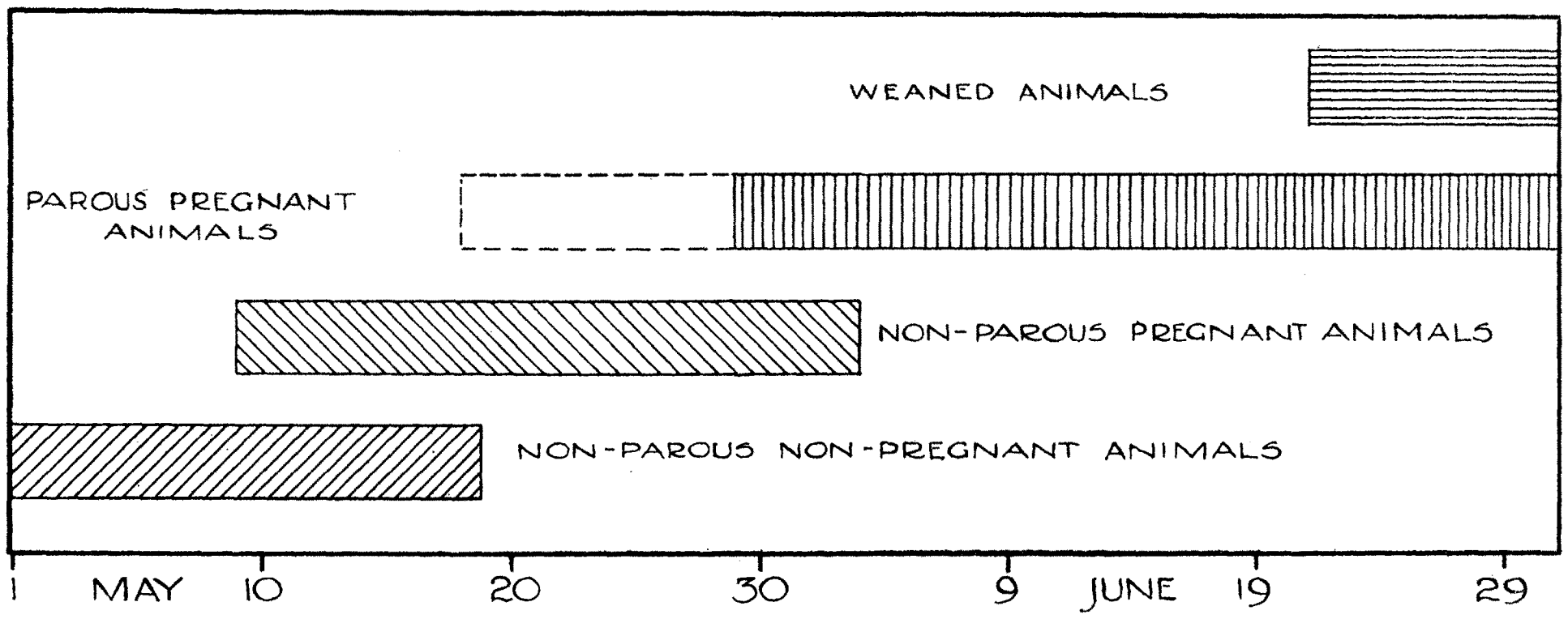

FIG. 3—Diagrammatic representation of the dates when non-parous non-pregnant, non-parous pregnant, parous pregnant and young animals were obtained during May and June. The hatched areas indicate the occurrence of numerous examples throughout the period indicated. The area outlined by the dotted line indicates the occurrence of a single parous pregnant animal on May 18, no others being obtained until May 29

by the consideration that suckling of the previous litter would have to be completed before the next litter started to suckle unless the latter were sacrificed. If it is assumed that the young appear in the traps soon after weaning begins then the period of 18 days between the last occurrence of non-parous pregnant animals and the first appearance of young in the traps is comparable. In view of the close correspondence of these three periods it is clear that the duration of the post-partum œstrus and of gestation together does not exceed 20 days and is probably 18 days or less.

Evidence of the minimum length of gestation is provided by an animal (S. 1254) which was caught alive and kept in captivity for 10 clear days. It then died and was found to be in a late stage of pregnancy. The stage of pregnancy attained was approximately later than 76 and earlier than 22 of the other pregnancies obtained. It may thus, on the assumption that the 99 pregnancies provide a random sample of stages, be 7/9ths of the time to full term. Since it was kept in solitary confinement for 10 clear days full term must be at least 13 days. This is a minimum estimate since the animal may have been pregnant some days before capture. It is possible that in the later stages of pregnancy animals do not tend to move about so much and are consequently not caught in the traps so easily as in the early stages. This would result in differential selection of the pregnancies with a consequent apparent shortening of the later part of gestation relative to the earlier part. The evidence available therefore indicates that the period of gestation is between 13 and 19 days and that the period of lactation corresponds.

(iv) *Transference of embryos between right and left uterine cornua*—The distribution of maturing follicles and of corpora lutea between the two ovaries of a pair was examined ; the observations and values expected on the assumption of a random distribution and the divergence are given in Table XI. It can be seen that there is no tendency in either case towards equality of distribution between the two ovaries and it may be assumed in consequence that the distribution is fortuitous.

The distribution of the implanted embryos between the two uterine cornua in 44 of the 52 post-implantation stages of pregnancy available is given in Table XII.

Since the difference of one between the number of embryos in the right and left cornua is only possible when the total number is uneven and represents the nearest approach to equality possible in them, there are only eight cases with a difference which was avoidable without loss and these all had the minimum avoidable difference of two. There is thus a very marked tendency to equality of distribution of embryos between the two uterine cornua. Since this tendency is not shown in the distribution of the corpora lutea or follicles, see Table XI, it must be due to transference of ova after ovulation. Since the ovarian capsules are completely closed this transference must take place via the junction of the two uterine cornua at the place where the common cervical canal opens into them.

The eight post-implantation pregnancies not included in Table XII all possessed one embryo implanted in a median position at the junction of the two uterine cornua

Table XI

Difference of number of corpora lutea or of follicles in the two ovaries of a pair	Maturing follicles			Corpora lutea		
	Expected	Observed	Divergence of observed from expected values	Expected	Observed	Divergence of observed from expected values
10+	0·1	1	+ 0·9	0·4	0	– 0·4
9	0·1	0	– 0·1			
8	0·4	1	+ 0·6			
7	0·5	0	– 0·5	0·9	1	+ 0·1
6	1·7	2	+ 0·3	2·6	2	– 0·6
5	2·5	4	+ 1·5	5·7	3	– 2·7
4	5·7	9	+ 3·3	9·8	12	+ 2·2
3	6·8	7	+ 0·2	16·6	19	+ 2·4
2	11·7	10	– 1·7	20·6	18	– 2·6
1	11·1	10	– 1·1	27·3	28	+ 0·7
0	7·4	4	– 3·4	13·1	14	+ 0·9
Total . .	48·0	48	0·0	97·0	97	0·0

Table XII

Difference of number of embryos in the two uterine cornua	Expected	Observed	Divergence of observed from expected values
9	0·0	—	– 0·0
8	0·1	—	– 0·1
7	0·3	—	– 0·3
6	1·0	—	– 1·0
5	1·9	—	– 1·9
4	4·8	—	– 4·8
3	6·2	—	– 6·2
2	11·5	8	– 3·5
1	10·6	19	+ 8·4
0	7·6	17	+ 9·4
Total	44·0	44	0·0

and opposite the opening of the common cervical canal. The possibility of implantation in this site shows that the anatomical structure is such as to render transference of ova possible. The details of these eight examples are given in Table XIII.

There is, in addition to strong presumption for transference, definite evidence that it has occurred on 27 specific occasions. The two ovaries were imbedded and cut together in most specimens to save labour, and in consequence it was not possible

TABLE XIII

Reference No.	No. of embryos in right cornu	No. of embryos in left cornu	No. of median embryos
1098	4	3	1
958	3	3	1
1009	3	3	1
954	3 (and 1 reabsorbing)	3	1
1000	3	3	1
1140	2	3	1
1008	1	3	1
1254	1 (and 1 reabsorbing)	2	1

to identify the right and left ovaries of a pair. If, for example, one ovary contained 2 and the other 5 corpora lutea and one uterine cornu 3 and the other 4 embryos, then, obviously, transference of at least one ovum must have taken place. The examples in which transference can be demonstrated in this way are given in Table XIV.

TABLE XIV

Reference No.	Date		Stage		Distribution of corpora lutea	Distribution of embryos	Minimum transference
1074	June	15	Before implantation		1 + 7	2 + 6	1
1094	„	21	„	„	4 + 5	(?) + 6	1
19	May	31	„	„	2 + 6	3 + 5	1
1083	June	16	„	„	5 + 3	6 + 1 (?)	1
1086	„	17	„	„	3 + 6	4 + 4 (?)	1
1095	„	21	„	„	5 + 1	3 + 3	2
1073	„	14	„	„	5 + 2	6 + 1	1
1075	„	15	„	„	1 + 2^{+}	3^{+} + 3^{+}	2
1081	„	16	„	„	3 + 5	4 + 4	1
1129	„	28	„	„	5 + 2	3^{+} + 3	1
1090	„	20	After implantation		2 + 6	3 + 4	1
1189	October	1	„	„	6 + 0	3 + 3	3
962	May	27	„	„	6 + 2	4 + 3	1
956	„	24	„	„	5 + 3	4 + 4	1
1142	September	5	„	„	4 + 2	3 + 3	1
1087	June	18	„	„	6 + 2	4 + 4	2
372	August	20	„	„	6 + 1	4 + 2	1
1242	May	15	„	„	4 + 4	5 + 3	1
967	„	27	„	„	1 + 4	2 + 3	1
1254	August	8	„	„	1 + 4	2 + 2 + 1	1
1020	June	3	„	„	1 + 6	3 + 4	2
1007	„	2	„	„	2 + 5	3 + 4	1
1000	„	1	„	„	2 + 5	3 + 3 + 1	1
989	May	30	„	„	7 + 0	4 + 3	3
957	„	25	„	„	2 + 5	3 + 3	1
939	„	20	„	„	2 + 4	3 + 3	1
1243	„	21	„	„	2 + 6	4 + 4	2

It was known that several of these animals were non-parous and it follows that transference is therefore not confined to parous animals. Transference must take place before implantation and the fact that it has done so in at least 10 of the 28 available examples with pre-implantation stages in the uterus indicates that it takes place fairly soon after the ova reach the uterus. It does not take place immediately, however, since in the earliest uterine stages the blastocysts are always grouped together in the uterus in the vicinity of the opening of the Fallopian tube. The blastocysts are about 125 μ in diameter when they reach the uterus from the Fallopian tube and those of the earliest stage in which transference has been found are 170 μ in diameter approximately.

c. Anœstrus

During the months of June to November 11 parous females were obtained which were lactating but not pregnant. No corpora lutea were present and the largest follicles attained a size of 290 μ in diameter. Sperms were found in one only (S. 1066). They may therefore be considered to be in lactation anœstrus, having failed to ovulate after parturition.

Since the corpora lutea of pregnancy disappear completely soon after parturition, traces of them being discernible in the ovaries of only one animal (S. 1133) in lactation anœstrus, it is clear that lactation in the shrew is maintained in the absence of corpora lutea. It has been shown in other animals that corpora lutea are not necessary for the maintenance of lactation, but we are unaware of any other species in which they are normally absent from the ovaries throughout lactation in non-pregnant animals. Animals in lactation anœstrus appeared to be met with relatively more frequently at the end of the season than at the beginning as can be seen from Table XV.

TABLE XV

Month	Second and subsequent pregnancies	Post-partum œstrus	Lactation anœstrus	Non-lactating and non-pregnant adults
June	33	2	3	—
July	3	1	1	—
August	5	—	2	1
September	6	—	1	—
October	3	—	2	—
November	0	—	2	1

There is little direct evidence that any animals, having entered upon lactation anœstrus, subsequently develop œstrus at the end of lactation. It is likely, however, from analogy with other species that this is the case, at least during the early part of the season. Some slight evidence in support of this view is provided by the fact that sperms were present in the Fallopian tubes of S. 1066 which was obtained on June 10 and which was evidently at the height of lactation, as judged by the development of the mammary glands. But this animal might be classified equally well as having copulated but failed to ovulate at the post-partum œstrus, the sperms having persisted in the tubes but disappeared from the uteri and vagina. Eight parous animals, which were pregnant but were not lactating, may have become pregnant at a post-lactation, not a post-partum, œstrus. Otherwise these animals could be interpreted as having lost the litters they should have been suckling. It has been suggested (p. 7) that one animal (S. 1257) might be in post-lactation pro-œstrus.

Two non-pregnant parous animals (S. 646 and 559) were obtained which showed no signs of recent lactation. These must be considered to have stopped breeding and to have entered upon a winter anœstrus. That obtained in February (S. 646) weighed 10 gm and had only small follicles, but S. 559, obtained in March, weighed only 7·5 gm and showed signs of follicular growth.

It seems probable that at the end of the season animals in lactation anœstrus pass directly into winter anœstrus when the young are weaned. The fact that three of the lactating anœstrous animals contain only small follicles and that several exhibit intense follicular degeneration supports this suggestion.

The general character of the reproductive cycle in the shrew is illustrated diagrammatically in fig. 4.

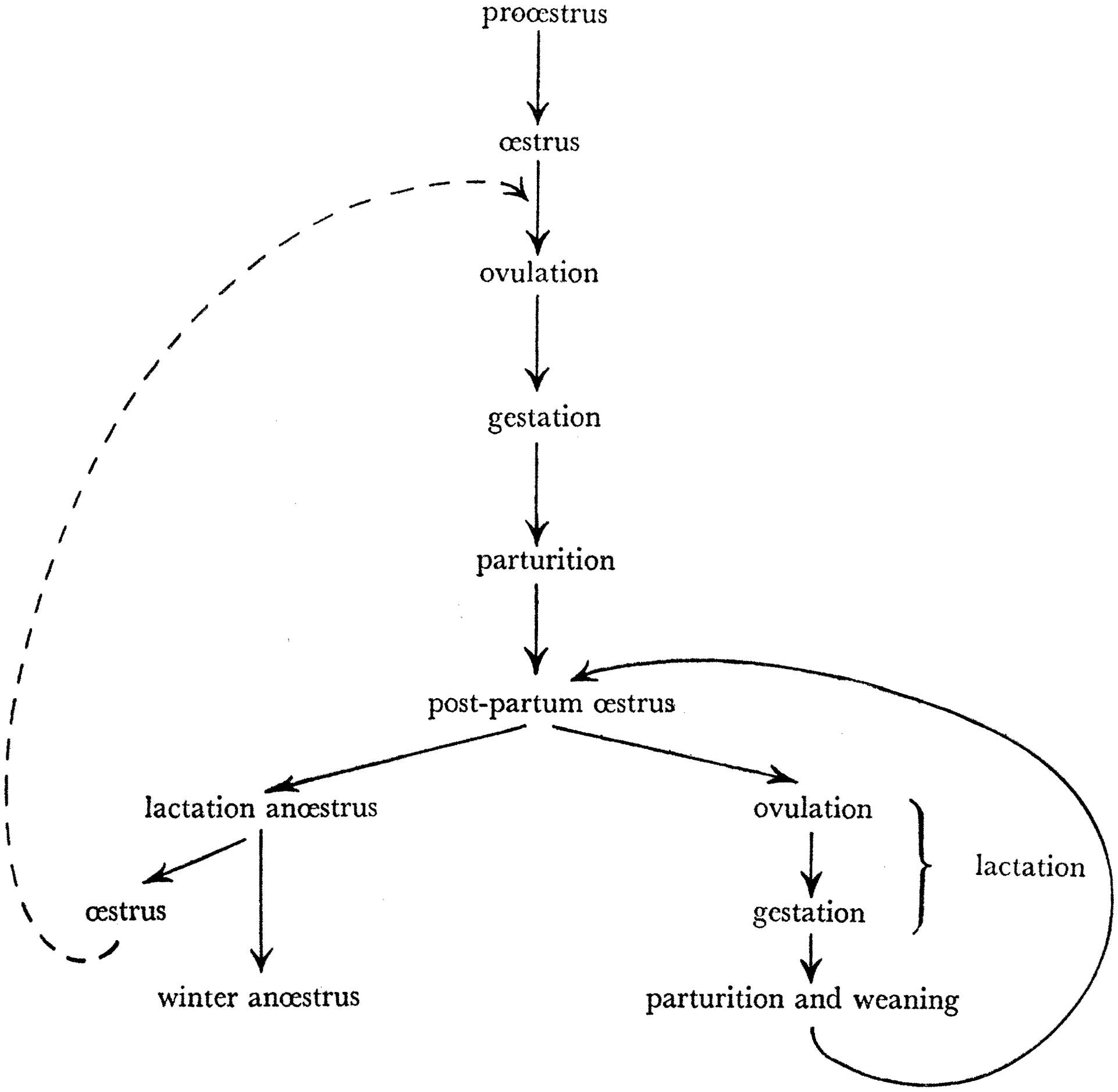

FIG. 4

VIII—The Ovarian Cycle

a. The prepubertal ovary

The ovaries of the young animals during the later part of the summer exhibit some signs of activity, although they remain very small. Some of the oocytes in them enter upon the growth phase and follicles of all sizes up to about 160 μ in diameter can be found. This growth of the follicles always appears to lead to degeneration, and several degenerating follicles are usually present as well as the normal ones. The degeneration of follicles containing oocytes which have entered upon the growth phase becomes more pronounced as autumn sets in, and by the middle of October involves them all. At this stage the ovaries present a very characteristic appearance, the cortical region being crowded with healthy primordial follicles and with cavities each containing a crumpled eosinophil remnant of the zona pellucida of an oocyte, all that remains of those follicles which entered upon the growth phase. Subsequently most of these traces of degenerated follicles disappear, and during the months of November, December, January, and February the small ovaries contain only a few cavities representing degenerating follicles as well as the clusters of healthy primordial follicles in the cortical region, fig. 55, Plate 8. Towards the middle of March signs of renewed activity become apparent, many follicles entering upon the growth phase and the whole ovary in consequence becoming larger. Some of these follicles degenerate. By the end of March or the beginning of April the ovaries have enlarged considerably and follicles over 200 μ in diameter are present as a rule. This prepubertal or pro-œstrous development continues until the œstrous condition is attained at the end of April or early in May. The final growth of the follicles prior to ovulation, which results in the ovaries attaining adult size, takes place after copulation.

b. The mature ovary

The mature ovary of the shrew owes most of its size to the large follicles which it contains. After ovulation its size is increased still further by the development of the corpora lutea. The ovary contains no interstitial cells, apart from the undifferentiated epithelial cells of the cortex, comparable to those found in the ovaries of many mammals, such as the rabbit. Follicular abnormalities are rare ; only a few biovular follicles were found. Some degenerating follicles are almost always present. True follicular atresia, resulting in the formation of corpora lutea atretica, is also rare and appears to occur only in large follicles following ovulation of other follicles. Sometimes such atretic follicles, presumably when not quite mature at the time of onset of atresia, fail to develop into fully formed corpora lutea but retain the antrum, the membrana granulosa becoming luteanized and slightly thickened in the process without filling the cavity. More often such follicles give rise to corpora lutea atretica indistinguishable from those of ovulation except for the crumpled zona pellucida of the oocyte in the centre. There was no evidence of the neo-formation of oocytes during adult life in any of the ovaries, although search was made for nuclei exhibiting the characteristic stages of the heterotypic division.

c. The growth of the ovum and follicle

The smallest oocytes in the ovary of an adult shrew measure slightly over 11 μ in diameter and are surrounded, as in other mammals, by a primordial follicle composed of a few flattened epithelial cells applied to the surface of the oocyte. These follicles measure as little as 16 μ in diameter. Thus the smallest oocytes and their primordial follicles are smaller than those of the white mouse, which were found to be respectively 13 μ and 17·5 μ in diameter. The subsequent growth of the ovum and follicle can be divided into two well-marked phases, the first in which both grow concurrently, and the second in which the ovum grows very slightly but the follicle becomes much larger, as happens in the mouse (BRAMBELL, 1928), the baboon (ZUCKERMAN and PARKES, 1932), the rat, ferret, rabbit and pig (PARKES, 1931). Measurements were made of a large number of oocytes and follicles from eight adult ovaries by means of a micro-projection apparatus and the results were treated statistically by the methods previously described (BRAMBELL, 1928). The data are given in the form of a correlation table in Table XVI and the calculated regression lines are represented in fig. 5.

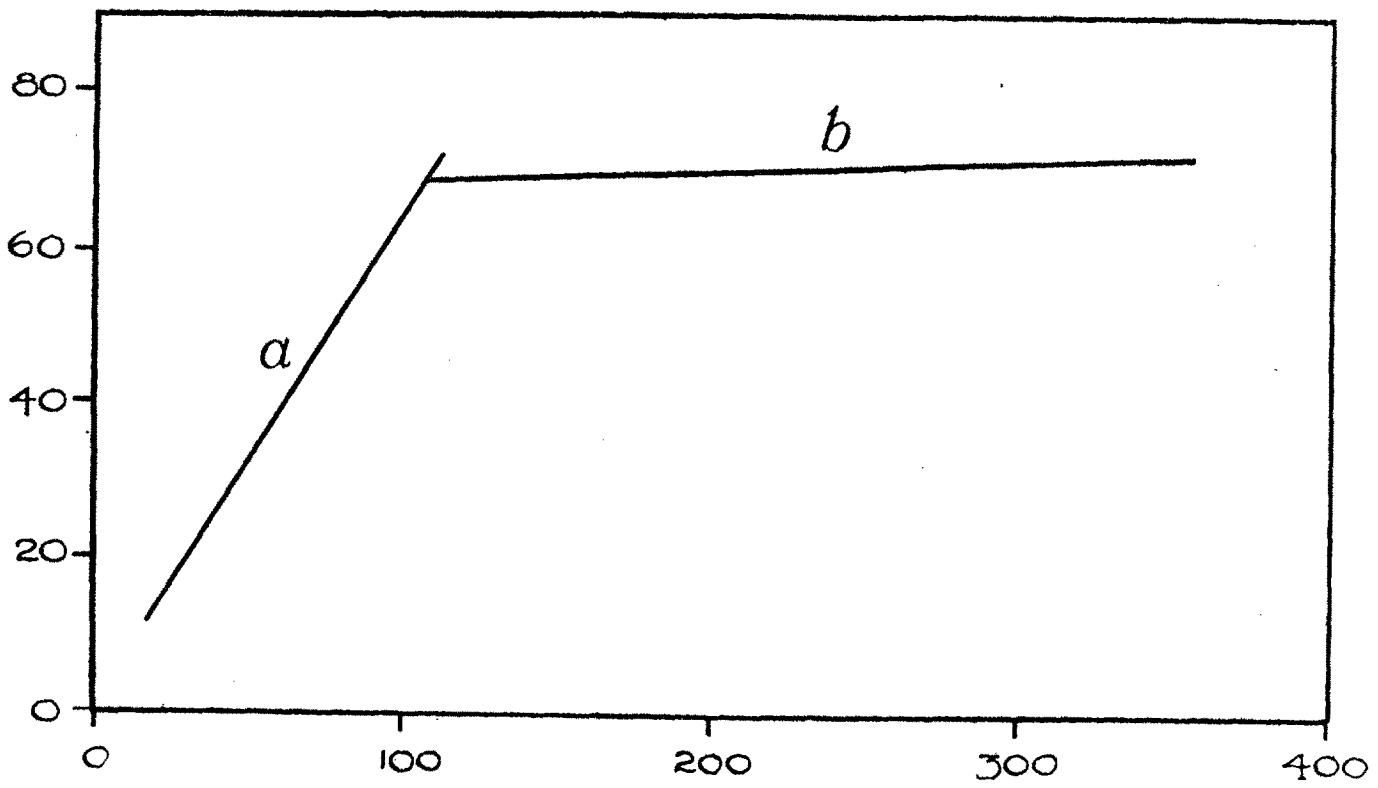

FIG. 5—Graphical representation of the regression of diameter of ovum on diameter of follicle. The formulæ for the two lines *a* and *b* are given in the text

Both regression lines were found to be significant. The lines are represented by the following formulæ

$$(a)\ y = 1 \cdot 2 + 0 \cdot 643\,x \text{ where } x = 16 \text{ to } 105$$
$$(b)\ y = 67 \cdot 26 + 0 \cdot 013\,x \text{ where } x = 105 \text{ to } 356$$

where y = diameter of oocyte in μ and x = diameter of follicle in μ. During the initial phase the ovum, measured in terms of the size of the follicle, grows more

TABLE XVI

Diameter of ovum in μ	0+					40					80					120					160					200					240					280					320				
80																		3			1	1				1																			
														1	1	1	2				1		1		1				1				1			1								1	
															1	1	1	1	1	5	2	3	3	1	2						1			1	3	3	3	2	5	3	1	2	1	2	1
																	1		6	4	6	3	7	3	5	6	1	1	1		1		1	3	4		1	4	2	4	3	1			
												1	3	1	2	3	3	1	4	5	8	4	5	2	3	1		1		2			1	1			4	2	1	2	1				
60											4	8	3	2	1	3	2	2	1	1	2	1			1																				
										2	7	1	1																																
										3	7	1		1																															
									2		1																																		
								1	2	3																																			
40								2	1	1																																			
							3	1																																					
							5	1																																					
						1	1																																					
					1	2																																						
20					2																																								
				1																																									
			13																																										
		1	2																																										
0+																																													

Diameter of follicle in μ

rapidly than that of any of the other mammals examined, as is shown by a comparison of the second terms of the regression formulæ.

Common Shrew .	0·643 x	
Ferret . .	0·5848 x	(Parkes, 1931)
Mouse . .	0·502 x	(Brambell, 1928)
Rabbit . .	0·4730 x	(Parkes, 1931)
Baboon . .	0·369 x	(Zuckerman and Parkes, 1932)
Rat . . .	0·2861 x	(Parkes, 1931)
Pig . . .	0·1382 x	,,

The initial phase is completed when the ovum attains a diameter of 69 μ, and the follicle a diameter of 105 μ. Subsequently the oocyte grows very slightly, attaining a diameter of 72 μ when the follicle is 350 μ in diameter. No follicles were obtained larger than this, and as one animal with follicles up to 328 μ in diameter was in full œstrus with spermatozoa in the vagina, and the oocytes in the large follicles, fig. 39, Plate 5, in the spindle stage of the first maturation division it may be assumed that they do not normally exceed 350 μ in diameter. The mature size of the follicle of the Common Shrew thus accords closely with that which would be expected on the basis of Parkes' (1931) suggestion that the diameter of the mature follicle plotted against the body-weight is a straight line relationship for mammals. The ratio of the size of the follicle at the beginning and at the end of the second phase is 1 : 3·4.

The antrum appears soon after the close of the first phase of follicular growth, when the follicle measures about 160 μ in diameter, as a few small cavities in the membrana granulosa. The number of follicles with antra, present in a pair of ovaries, varies considerably in different individuals. Counts of the follicles with antra in the ovaries of adult animals from April to November inclusive were made and the results are given in fig. 6. It can be seen that the largest number found in a pair of ovaries was 64. The number tends to be high at first but appears to fall off at the end of May. After August some of the animals, being in anœstrus, have no follicles with antra. It is apparent also that there is no significant difference between the number of follicles in the ovaries of pregnant and non-pregnant animals during the breeding season.

d. The structure of the mature Graafian follicle

The membrana granulosa surrounding the antrum is 45 to 55 μ thick and is composed of several layers of cells in a mature Graafian follicle measuring about 300 to 325 μ in diameter excluding the theca. The nuclei of many of the membrana granulosa cells are situated close to the bases of the cells where they are attached to the membrana propria, forming a zone in this region. The nuclei of the majority of the remaining cells are situated in a zone two or three nuclei deep next to the antrum. There is thus a region between these outer and inner zones of nuclei in the membrana granulosa which tends to be comparatively free of nuclei. Those cells of the membrana granulosa with nuclei next the antrum appear to be growing inwards and invading the antrum in the mature follicle, doubtless the first manifestation of the active ingrowth that will take place as soon as the follicle ruptures.

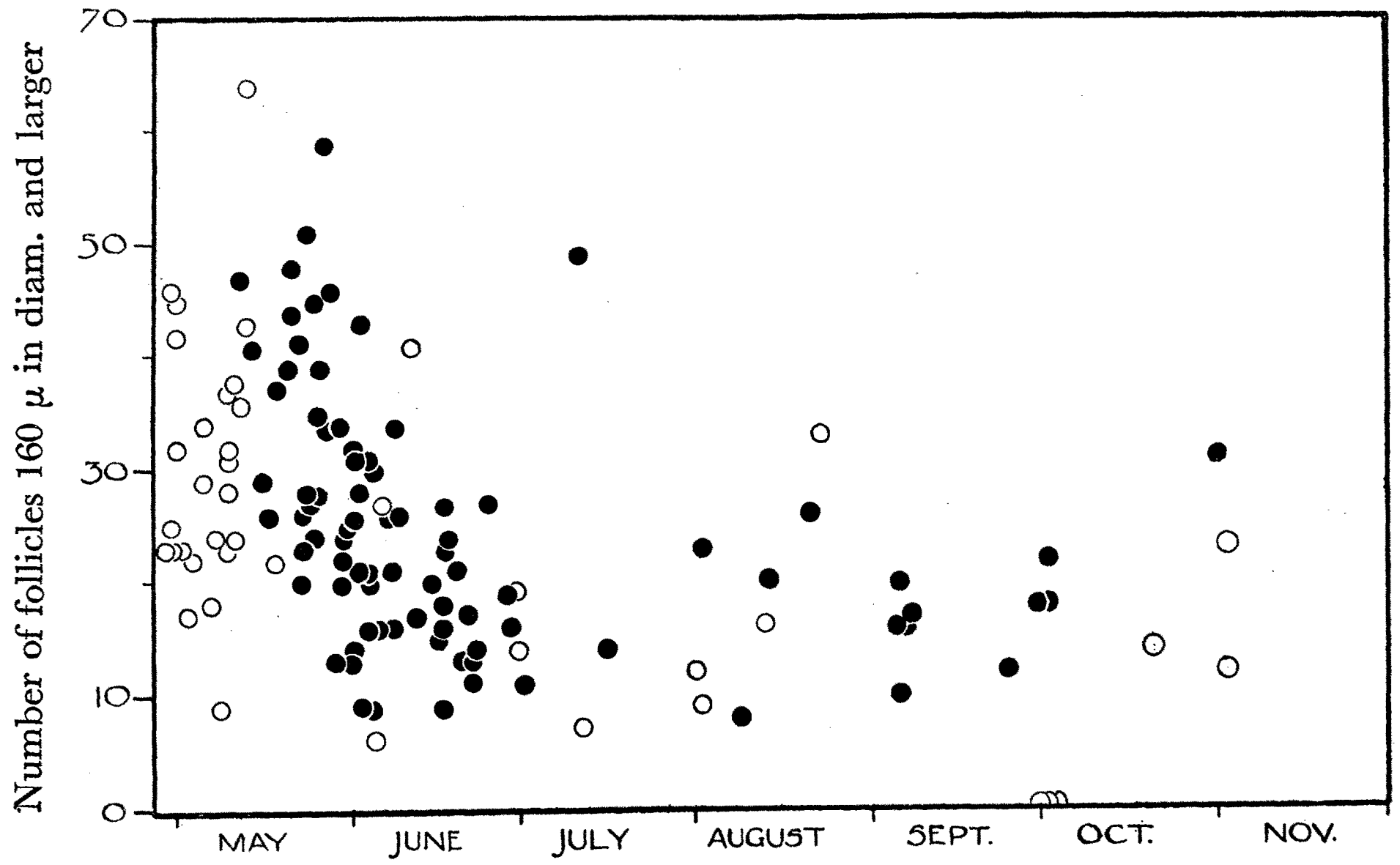

FIG. 6—Graphical representation of the number of follicles with antra (160 μ in diameter and larger) present in each adult obtained from April to November

● = pregnant animals ; ○ = non-pregnant animals

The discus proligerus measures about 150 μ in diameter and is only slightly excentric, being nearer the side of the follicle to which it is most firmly attached. Strands of cells, however, connect it in other places to the membrana granulosa. The antrum of the healthy mature follicle is therefore exceedingly small, fig. 39, Plate 5. It is larger in degenerating follicles in which thinning-out of the membrana granulosa is an early sign of retrogression. The cells nearest the ovum in the discus proligerus of mature follicles become vacuolated and enlarged, but those in the periphery of the discus tend to become pycnotic. The cells of the membrana granulosa do not become arranged to form bodies of Call and Exner, such as are found in a number of animals.

The theca of mature follicles measures from 17 to 22 μ thick, of which the theca interna constitutes 11 to 15 μ. The theca interna, which is poorly developed, consists of small cells, resembling the epithelial cells of the ovarian stroma, which show no signs of glandular activity. They are plentifully interspersed with blood capillaries which become greatly distended as the follicles approach maturity. The theca externa forms a thin connective tissue coat around the whole follicle. There is a thin but clearly defined connective tissue membrana propria between the theca interna and the membrana granulosa.

e. The follicle during pregnancy

The number of follicles 160 μ in diameter and over, which presumably corresponds with the number with antra, present in the ovaries during pregnancy varies from 8 to 59, the mean number being 25. There does not appear to be any significant change in their number during pregnancy. This fact is brought out in fig. 7, in which the number of follicles is plotted, the pregnancies being arranged in order of stage of development beginning at fertilization on the left and ending at the latest stage available on the right.

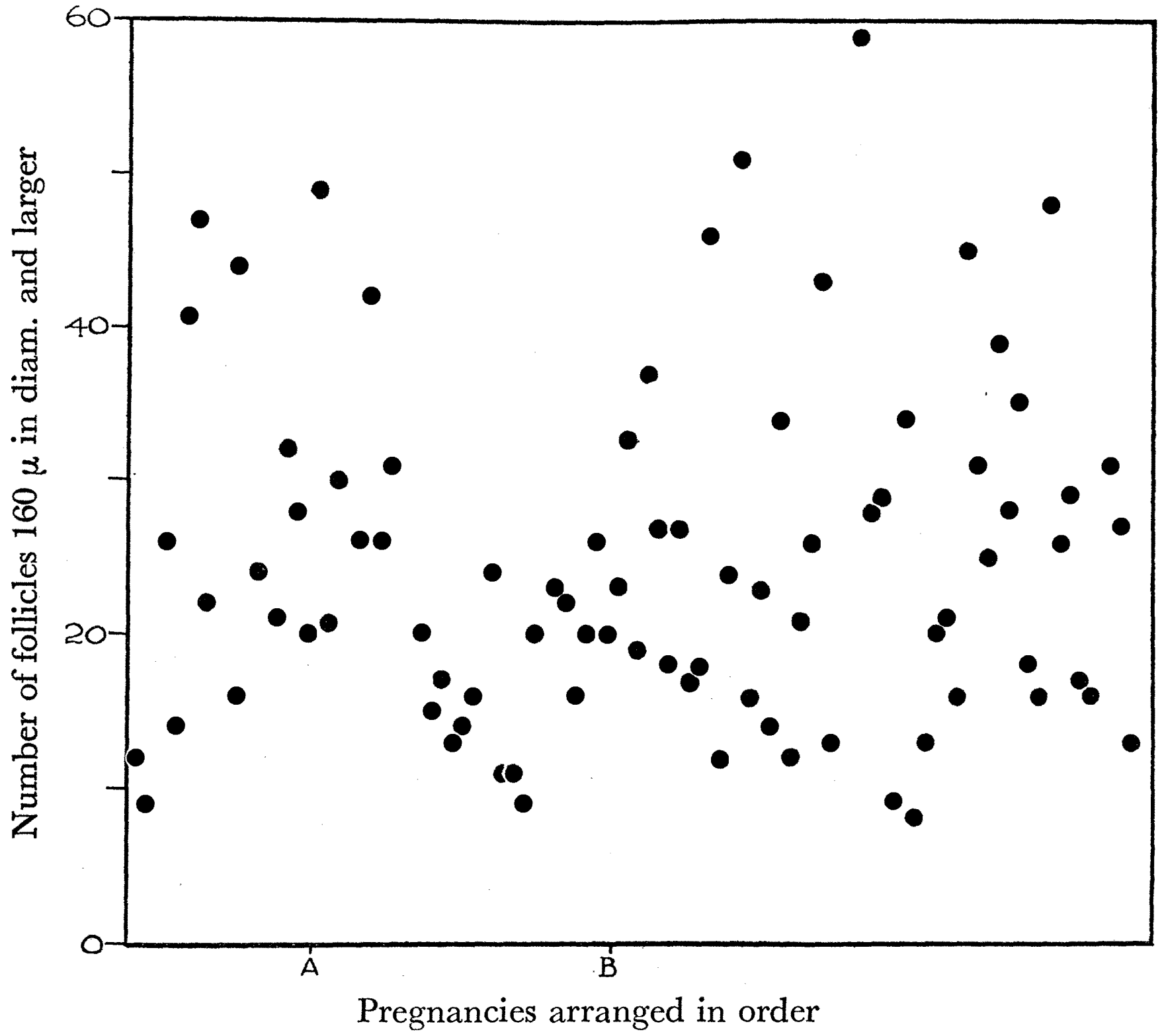

FIG. 7—Graphical representation of the number of follicles with antra (160 μ in diameter and larger) present in each pregnant animal according to stage of pregnancy. The successive stages of pregnancy are arranged in order on the abscissa beginning with fertilization at the origin and ending with approximately full-term on the right. A = stage of passage of ova from tube to uterus. B = stage of implantation of embryos

Although the total number of follicles with antra does not appear to change during pregnancy, the largest follicles, which will presumably ovulate at the post-partum œstrus, increase in size. This is shown in fig. 8, in which the diameters of the largest follicle in each pair of ovaries are plotted successively according to stage of pregnancy. The abscissæ of figs. 7 and 8 therefore correspond. It is apparent that immediately after ovulation, when the ova are still unsegmented, the largest follicle is small, but rises rapidly from 180 to 200 μ in diameter to a mean size of approximately

260 μ in diameter when the ova are about to pass into the uterus. Subsequently the mean size increases gradually to about 320 μ at the end of pregnancy. There is, however, remarkable variation in the size of the largest follicle, examples 320 μ and over being found while the ova are still in the tubes, while the two largest at 350 μ in diameter were respectively before implantation occurred and at the end of pregnancy.

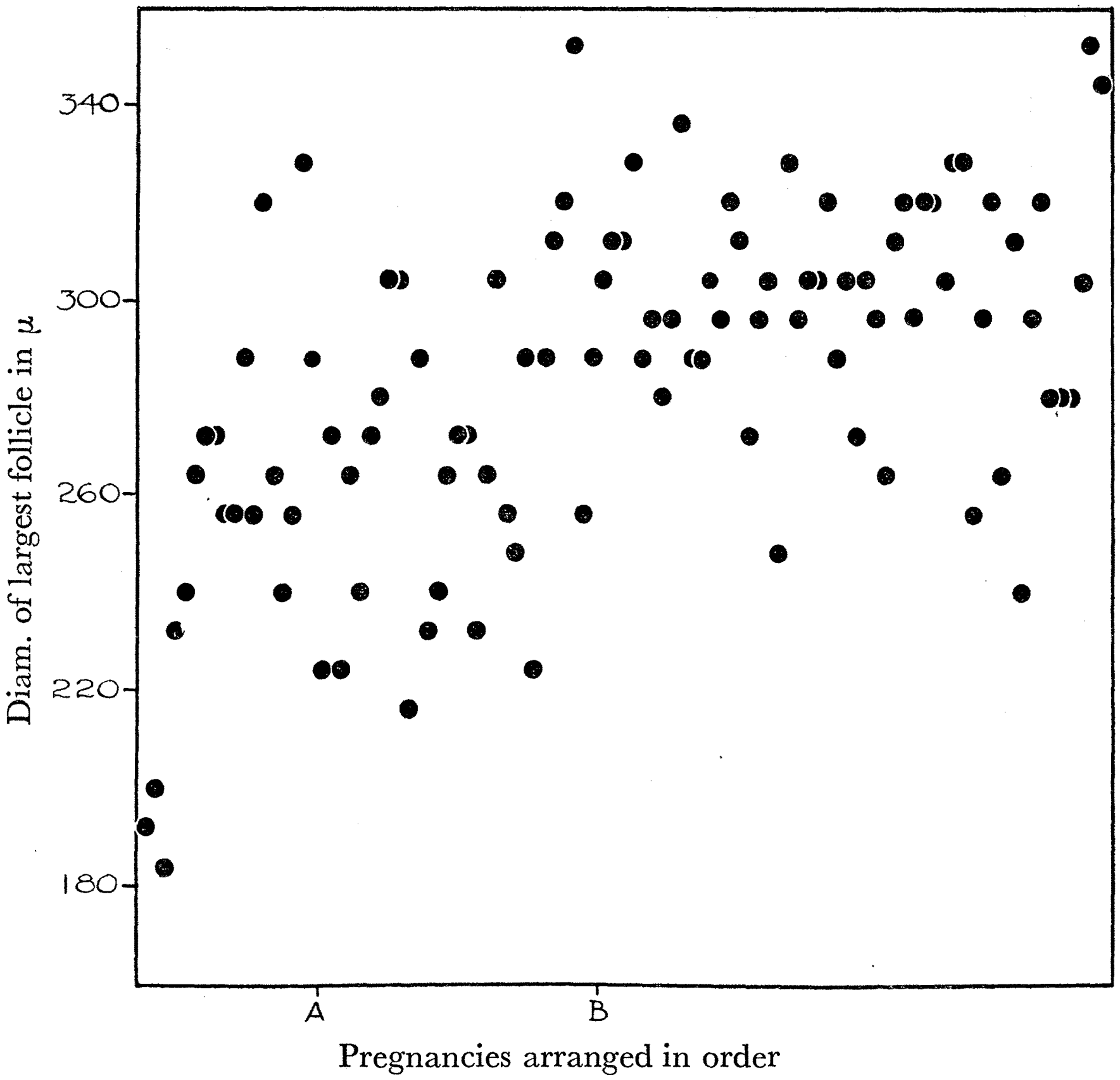

FIG. 8—Graphical representation of the diameter of the largest follicle in each pregnant animal according to stage of pregnancy. The abscissa corresponds to that of fig. 7

f. Size changes in the corpus luteum during pregnancy

Corpora lutea which were measurable were present in the ovaries of 103 animals, in three of which there were two sets. It was impossible to include one animal (S. 4) owing to bad preservation. The mean diameter of all the measurable corpora lutea in each of the 105 sets was calculated. The results are given in fig. 9, the animals being arranged in order, according to the stage of pregnancy, on the abscissa as in figs. 7 and 8. The order of the five sets of corpora lutea persisting after parturition is somewhat arbitrary, but the first three were in post-partum œstrus and the last two each had a second set of newly formed corpora lutea accompanied by tubal ova undergoing the first cleavage and in the 2-cell stage respectively.

The earliest stages, which had ovulated recently, had developed corpora lutea with mean diameters of 280 to 300 μ. The corpora lutea attain a mean size of nearly 500 μ in diameter by the time the ova reach the uterus and remain at this level until near the end of gestation. The size in individual animals ranges from 400 to 575 μ in diameter except in two cases ; one with a mean diameter of 638 μ and the other with a mean diameter of 224 μ, probably owing to extreme post-mortem shrinkage. The decrease in size of the regressing corpora lutea at the end of pregnancy appears to be very rapid, so that when parturition occurs they measure approximately 200 to 250 μ in diameter and disappear completely soon afterwards. No regressing corpora lutea were observed to persist after the ova of the ensuing pregnancy were in the 2-cell stage. Two sets of corpora lutea normally are present simultaneously in the ovaries only for a very brief period after parturition.

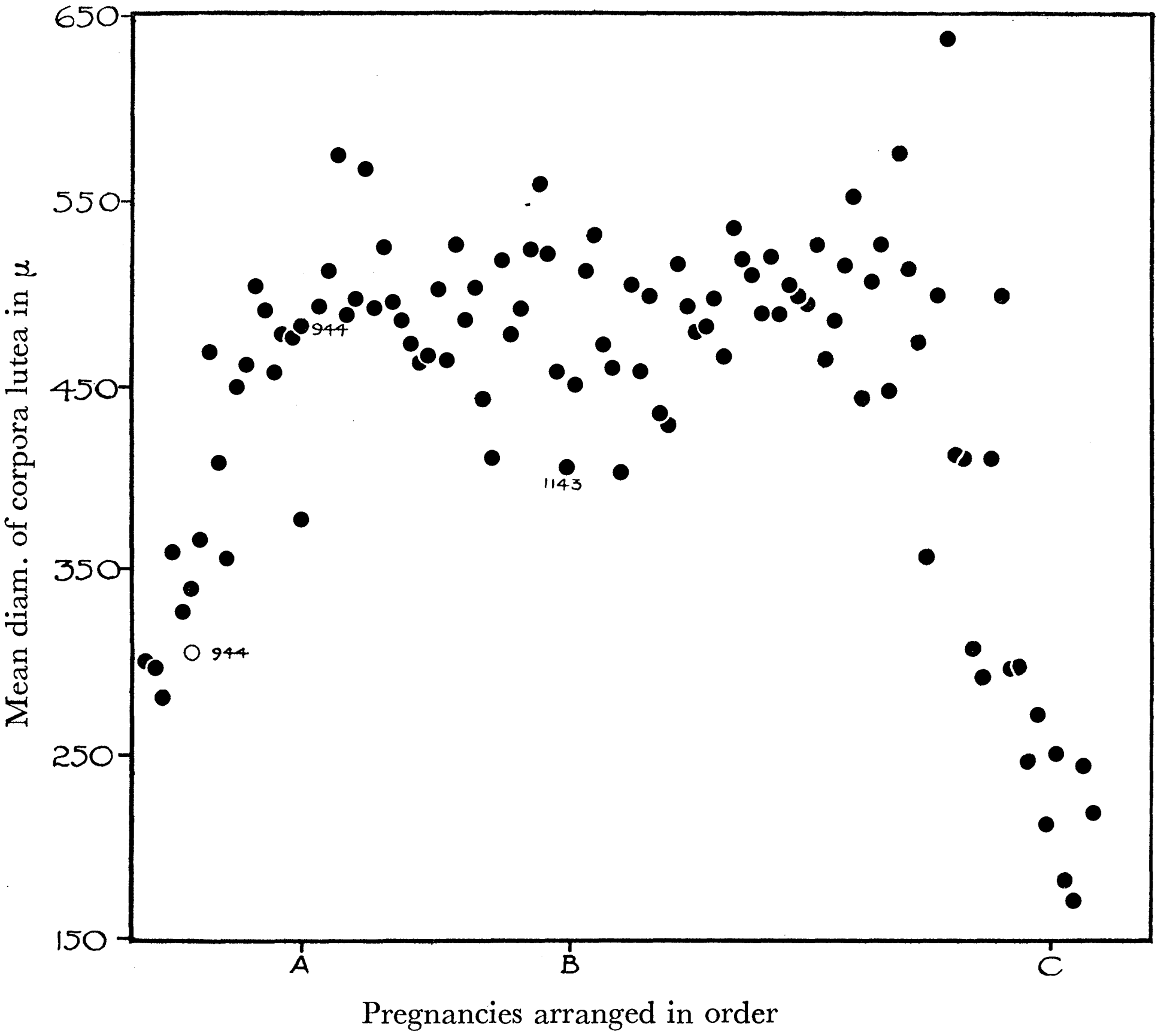

FIG. 9—Graphical representation of the mean diameter of the corpora lutea present in each pair of ovaries according to stage of pregnancy. One animal (S. 944) had two sets of corpora lutea and embryos. The mean diameter of the newer set is represented by a hollow circle with the number beside it and of the older set by a solid circle, also numbered. The abscissa corresponds to that of figs. 7 and 8 up to the time of parturition at C. Post-partum animals are arranged in order after point C

g. Histological changes in the corpus luteum

The follicle partially collapses after rupturing, measuring 280 to 300 μ in diameter as compared to 350 μ before ovulation. The collapse is relatively slight, as compared to that found in animals with larger follicles, and does not lead to any infolding of the wall. The subsequent formation of the corpus luteum thus is due entirely to ingrowth of the cells from the periphery and is not assisted by infolding of the theca or membrana granulosa. The newly ruptured follicle, fig. 15, Plate 2, retains the central cavity which opens on the surface of the ovary at the point of rupture. The presence of colloidal precipitate in this cavity indicates that the secretion of liquor folliculi continues for a time after ovulation. Pycnotic cells are found in the membrana granulosa and in the cavity but soon disappear as the healthy cells form the corpus luteum. Some blood may also be found in the cavity and around the point of rupture of the follicle, but as a rule there appears to be little bleeding. The nuclei of the cells of the membrana granulosa, which were localized in zones near the thecal wall or near the antrum, become rearranged. The cells enter upon a period of enlargement and ingrowth, fig. 16, Plate 2, immediately after the rupture of the follicle. This process continues until the antrum is filled, except that a small clot persists in the centre. The antrum ceases to be patent about the time when the tubal ova have reached the 8-cell stage. During the formation of the corpus luteum no mitoses are observable in the cells of the membrana granulosa. Its formation is due therefore, so far as these cells are concerned, to their enlargement and ingrowth. This continues until the corpus luteum is fully formed, fig. 17, Plate 2, about the time when the blastocysts reach the uterus. It results in the cytoplasm appearing more eosinophil as well as dense and homogeneous in stained preparations. The nuclei at the same time become larger and sub-spherical in shape instead of oval. The chromatin becomes less obvious but the plasmosome becomes larger. The nuclei of the fully developed luteal cells therefore appear larger, plumper, rounder and clearer but with a more noticeable plasmosome than those of the membrana granulosa of the follicle. Meanwhile, the ingrowth of capillary vessels from the theca takes place rapidly so that the forming corpus luteum is well vascularized before the antrum has disappeared. The ingrowth of connective tissue from the theca is a much more gradual process. It does not begin until the ova are in the 2- or 4-cell stage, fig. 16, Plate 2, and proceeds gradually and continuously until the blastocysts are about to become implanted, fig. 18, Plate 2. During this period mitoses are frequent in the connective tissue cells in the corpus luteum. The connective tissue forms a complete network between the luteal cells and invades and replaces the central clot in the fully formed corpus luteum. Once the corpus luteum is fully formed no change can be detected in it until about half-way between implantation and parturition (as judged by the series of pregnancies). Subsequently the cytoplasm of the luteal cells becomes vacuolated. This vacuolation is slight in most animals but is very marked in one or two. Regression begins after this and is accompanied by shrinkage and pycnosis of some of the luteal cells. Mitoses were observed in the luteal cells in many retrogressing corpora lutea and were plentiful in some. This phenomenon is remarkable and is a sign of retrogressive changes in the cells, although usually the mitotic stages appeared to be perfectly normal. Retrogression is very rapid and does not normally appear to be accompanied by leucocytic invasion, although leucocytes were present in some retrogressing corpora lutea. By the end of pregnancy the corpora lutea are very small, shrunken and distorted, fig. 19, Plate 2. They then measure only 200 to 250 μ in diameter, and consist of a connective tissue reticulum with relatively few luteal cells in the interstices. They disappear completely very soon after parturition.

h. The anœstrous ovary

The condition of the ovary of non-pregnant animals during lactation anœstrus varies considerably. Nine of the twelve animals available (including S. 240, *vide* p. 7) had follicles from 248 to 288 μ in diameter, and in one of these pigmented traces of the corpora lutea of the previous pregnancy could be distinguished. These ovaries therefore could not be said to be inactive although the cycle was at least temporarily suspended. The other three animals had no follicles with antra in the ovaries, which were very small and exhibited much follicular degeneration. It seems probable that these animals, which were obtained between September 30 and October 3, were passing into true anœstrus and would not have resumed breeding at the conclusion of lactation.

The ovaries of two animals in winter anœstrus were available. One, obtained on March 10, had follicles up to 264 μ in diameter and was therefore probably exhibiting signs of the onset of renewed activity at the approach of spring. The other, obtained on February 4, had small inactive ovaries, fig. 56, Plate 8, with no follicles over 160 μ in diameter and was the only one which exhibited the complete ovarian inactivity commonly associated with anœstrus.

IX—The Cycle in the Fallopian Tubes

The cyclic changes in the Fallopian tube of the shrew are slight in comparison with those in some other mammals. The ovarian part of the tube is continuous with the fimbriate opening into the ovarian capsule and is similar to it in structure. The epithelial lining of this portion of the tube is much folded and tubular crypts or alveoli are formed in it, so that the relatively narrow and irregular cleft-like lumen is surrounded by a broad zone of spongy tissue made up of these alveoli with thin partitions between them. The whole is surrounded by a thin connective tissue sheath over which the peritoneal investment is stretched. The changes taking place in the immature animal, fig. 37, Plate 5, leading up to the first œstrus consist chiefly in an increased folding of the epithelial lining and extension of the epithelial crypts or alveoli opening into it. This results in considerable increase in diameter of this part of the tube, fig. 38, Plate 5, and much complication of the lumen in cross-section. This change is accompanied by a slight increase in the thickness of the epithelium which measures 10 to 20 μ thick at its maximum development. The epithelium is ciliated, the cilia being clearly visible at all stages in well-preserved material. Some of the cells of the epithelium develop lobes of cytoplasm, protruding into the lumen, into which the nuclei pass. This phenomenon has been observed previously in the mouse by 'ESPINASSE (personal communication). It becomes increasingly common during œstrus. It reaches a maximum during the initial stages of pregnancy and then decreases towards the end. It can be observed, although infrequently, even in anœstrous animals. These lobed cells are most plentiful in the fimbria and gradually decrease in number along the proximal portion of the tube, being entirely absent where this joins the uterine portion. They are confined to the epithelium lining the lumen of the tube and do not occur in the alveoli. During the time when the ova are in the tube secretion can be observed in the alveoli. As the ova pass down the tube this phase of maximum activity is followed by sloughing of some of the cells in the alveoli, many of which can be observed to contain masses of cell debris. Sperms are found in the alveoli after copulation and persist longer in them than elsewhere, being found in some animals among the cell debris when the ova have reached the blastocyst stage and are about to pass into the uterus. During lactation anœstrus the ovarian portion becomes less active, the epithelium decreases in thickness and the alveoli and folds of the epithelium are reduced in extent. The extreme stage of this process of involution is exhibited in anœstrous animals taken in winter. The epithelium in them is reduced to 4 to 9 μ in thickness. The reduction in the alveoli results in relative increase of the connective tissue stroma which is consequently much more conspicuous in sections.

The changes taking place in the uterine part of the tube are even less marked. This region is circular in cross-section and is provided with a relatively thick muscular wall. The epithelial lining is thrown into longitudinal folds. The epithelial cells do not appear to be ciliated at any stage of the cycle. In the immature animal the epithelial folds are shallow, fig. 33, Plate 5. The cells composing the cubical epithelium are almost filled by the nuclei, which therefore appear crowded together. Prior to and during œstrus the folds become deeper, fig. 34, Plate 5, the epithelial cells increase in size, and the epithelium becomes slightly thicker. The increase in size of the cells is confined to the cytoplasm which thus appears more abundant and the nuclei less crowded. Even in late œstrus, after copulation has occurred and when spermatozoa are present in this region of the tube, the cells are definitely not ciliated and do not appear to be actively secreting. After œstrus, when the fertilized ova are in the ovarian part of the tube, a phase of increased activity sets in and reaches its height when the ova enter the uterine part of the tube, fig. 35, Plate 5. This phase is marked by further complication of the lumen resulting from increased folding of the epithelium. The cytoplasm of the epithelial cells enlarges still further and cells extrude globules of secretion into the lumen. Mitoses are numerous in the epithelial cells at this stage and the epithelium is thicker, being low columnar in form. Activity ceases after the passage of the ova into the uterus, no signs of mitoses or of secretion being visible. The lumen also becomes simpler but the epithelium does not decrease in thickness. The condition during the post-partum œstrus, fig. 34, Plate 5, resembles that at the first œstrus. During lactation anœstrus and true anœstrus the involution is more marked, the tube, fig. 36, Plate 5, approaching the condition found in the immature animal both in the simplicity of the lumen and in the cytological character of the epithelium.

X—The Uterine Cycle

a. The prepubertal uterus

The uteri of immature shrews, fig. 21, Plate 3, during the late summer, autumn or winter are very small and almost circular in section. They measure about 0·6 mm in diameter. The outer layer of longitudinal muscle measures approximately 15 μ, the inner layer of circular muscle about 30 μ in thickness. There is a well-defined layer between the circular muscle and the mucosa which appears to be composed chiefly of fibrous connective tissue and which measures 25 μ in thickness. Nuclei are scarce in this layer as compared to the circular muscle, but are more numerous in the region adjoining the mucosa. The cells are arranged chiefly in a circular manner. This layer is very characteristic of non-parous uteri and remains distinct during the first pregnancy until the blastocysts are about to become implanted. The mucosa is thicker on the anti-mesometrial side, all the glands being localized in this region. They lie chiefly on each side of the slit-like anti-mesometrial portion of the T-shaped lumen, into the extremity of which they open. No glands are situated in the mucosa on the mesometrial side. The glands are poorly developed, relatively few being cut across in a transverse section. The uterine epithelium consists of a single layer of columnar cells with the nuclei, elongated presumably by the pressure of neighbouring cells, lying in a row at the basal ends of the cells. During the spring the uterus enlarges but otherwise undergoes little change.

b. The uterus during first œstrus

The uterus during the first œstrus, fig. 22, Plate 3, measures approximately 1 mm in diameter ; the longitudinal muscle being 50 μ thick, the circular muscle 80 μ and the fibrous connective tissue zone 70 μ. The mucosa has hypertrophied ; the connective tissue stroma being denser and the uterine glands better developed and more numerous. The uterine epithelium still consists of a single layer of columnar cells.

c. The uterus during first pregnancy

Since all the post-œstrous animals were pregnant it is not possible to describe the subsequent changes in non-pregnant uteri. However, the changes after ovulation leading up to implantation are striking. The later stages immediately preceding and during implantation have been described in some detail by Hubrecht

(1894), but he paid little attention to the changes in the uterus while the ova are still in the Fallopian tubes and failed to distinguish between uteri of first and subsequent pregnancies.

The uterus continues to hypertrophy after œstrus, fig. 23, Plate 3. The growth in thickness of both the muscularis and mucosa results in the gradual suppression of the fibrous connective tissue layer between them. This layer disappears by the time the blastocysts are ready to become attached to the uterine wall. The vascular development also increases continuously. During metœstrus, when the tubal ova exhibit the second polar spindles, fig. 23, Plate 3, the uterine glands increase both in size and number and the uterine epithelium becomes considerably thicker. Mitoses are relatively rare in both and the single-layered condition of the epithelium is maintained, fig. 27, Plate 4. Spermatozoa are numerous in the uterine lumen together with a colloid substance derived chiefly from the secretion of the uterine glands, but possibly in part from the seminal fluid. Other cellular elements are absent from the lumen at this stage, but leucocytes are numerous in the mucosa.

The changes in the mucosa have proceeded much further by the time the ova have reached the 4-cell stage. The glands are more numerous and extend further round the sides of the uterine lumen on the anti-mesometrial side. A distinct lumen can be distinguished in most of the gland tubules, which often contain colloid. The openings of the glands into the uterine lumen are distended with colloid. Mitoses can be observed in the uterine epithelium and in the glands but are not very numerous. Leucocytes are numerous and free in the uterine lumen, together with colloid and a few sperms, as well as in the mucosa. They are still more numerous by the time the ova have attained the 8-cell stage, fig. 24, Plate 3, and are present in large clusters both in the uterine lumen and epithelium, but sperms are very scarce. Mitoses are more numerous and the individual cells are larger in the glands at this stage.

The next stage is one with blastocysts still in the tubes. At this stage the uterine epithelium, fig. 28, Plate 4, has undergone a profound change. The nuclei have become arranged in several layers instead of in a single layer near the bases of the cells. They have in consequence, owing presumably to their being no longer squeezed between their neighbours, become spherical instead of oblong in shape. This striking change appears to have been effected by movement of the nuclei within the cells, which are still columnar and arranged in a single layer, as well as by mitosis. Mitotic figures are present, but are not numerous, as would be expected if the change were due entirely to proliferation without rearrangement. The epithelium is slightly thicker. The glands are still more convoluted, their lumina more distinct and mitotic figures are numerous in their cells. Leucocytes are entirely absent from both the mucosa and from the uterine lumen, which is empty. The next stage was one in which the blastocysts were in the uterus, fig. 25, Plate 3, but had only recently arrived there. This stage exhibited little advance on the previous one, but mitoses were numerous in the epithelium which was evidently entering upon a period of rapid proliferation. There was granular colloid in the lumen of the uterus, which, since it was not present in the uterine glands, was probably derived from the Fallopian tubes.

A remarkable change takes place after the blastocysts have become definitely spaced out in the uterine lumen. At this time the part of the lumen on the side opposite the mesometrium becomes distended to form a spherical chamber around each blastocyst. This stage has been described and discussed in detail by HUBRECHT (1894). Since the blastocysts are free in the lumen at the outset of this stage and are still surrounded by the thin stretched zona pellucida of the ovum HUBRECHT maintained that the change took place without " any direct or active co-operation of the blastocyst." It is suggested that the formation of the spherical chambers may be interpreted equally well as due to local distensions of the uterine lumen by the expanding blastocysts, which are presumably spherical in life although collapsed in fixed material. The formation of the spherical chambers, fig. 26, Plate 3, results in the anti-mesometrial uterine wall becoming much stretched and consequently greatly reduced in thickness. This stretching results in the glands becoming spread further around the sides of the uterus and consequently becoming much less numerous immediately opposite the mesometrium. It also results in the uterine epithelium being stretched to form a single layer of cubical cells opposite the mesometrium, although it remains thick at the sides and next to the mesometrium.

The subsequent changes taking place in the pregnant uterus belong more properly to a description of the placentation and will not be described here. Reference should be made to HUBRECHT's paper (1894) for such a description.

d. The post-partum œstrous uterus

The uterus during post-partum œstrus is large and its walls are thin and folded. The placental sites have not healed and the lumen is full of cell debris. Remarkably little extravasated blood is present but the uterine vessels are enormously distended. Sperms are found in numbers amongst the cell debris in the lumen of the uterus. It is remarkable that they are able to ascend the uterus during this phase of disorganization.

e. The parous uterus during pregnancy

The uterine changes during the early stages of pregnancy in parous animals differ from those of the non-parous animals chiefly in the complications resulting from the repair of the placental sites. There are, at first, large numbers of leucocytes in the mucosa, especially in the vicinity of the placental sites, and in the uterine lumen. These disappear gradually and are absent both from the mucosa and the lumen by the time the ova are in the stage of tubal blastocysts. Cell debris from the placental sites is found in the uterine lumen and the mucosa is markedly hyperæmic immediately after post-partum œstrus. The placental sites heal rapidly and are small by the time the ova are in the 4-cell stage, fig. 29, Plate 4. The epithelium has closed over them and is intact when the ova are in the morula stage, fig. 30, Plate 4, and scarcely any trace of them remains when the blastocysts reach the uterus. The uteri of parous shrews have two other characteristic features which are apparent in the early stages of pregnancy. The uterine arterioles both in the mesometrium and in the mucosa and muscularis of the uterus itself have very thick hyaline walls which render them conspicuous and serve to distinguish parous, figs. 31 and 32, Plate 4, from non-parous uteri, figs. 21 to 24, Plate 3, at a glance. This characteristic of parous uteri has been described in the grey squirrel by Deanesly and Parkes (1933) and in the hedgehog by Deanesly (1934). Secondly, the zone of fibrous connective tissue found between the muscularis and mucosa in the non-parous uterus is absent.

The uterine epithelium in the parous animal, by the time the fertilized ova are undergoing the first cleavage, is composed of low columnar cells with their nuclei arranged in a single row on the side away from the lumen. The subsequent changes in the epithelium closely resemble those in non-parous uteri except that mitoses are much more numerous at first, presumably owing to the active repair of the damage resulting from parturition. The changes in the glands are also similar. Glands are absent at first from the old placental sites, but as these retrogress the glands become rearranged in these regions, fig. 30, Plate 4. Apart from these differences the changes taking place prior to attachment of the blastocysts in parous uteri appear to be identical with those described in non-parous uteri.

f. The anœstrous uterus

It is only necessary to describe the typical condition during the height of anœstrus as exhibited by S. 646 obtained in February. The parous nature of the uterus, fig. 32, Plate 4, is apparent from the thickened hyaline walls of the arterioles and the absence of the fibrous connective tissue zone. The uterus is, however, exceedingly small, measuring only 0·6 mm in diameter. The glands in the mucosa are very poorly developed and the cells composing them are small with the nuclei almost filling them. Consequently the nuclei appear to be crowded together. The lumina of the glands are distinct and are empty of secretion. The uterine epithelium is thin and composed of a single layer of cubical or low columnar cells. The stroma of the mucosa is dense and contains scattered patches of pigment. Mitoses are entirely absent from both the epithelium and glands. Leucocytes are numerous in the uterine lumen together with a few detached nucleated epithelial cells. The uterus of the other anœstrous animal is similar. The uteri of some of the animals in lactation anœstrus, fig. 31, Plate 4, are equally inactive.

g. Changes in the cervix

The mucosa thins out in the cervical region ; the epithelium being separated from the muscularis by a comparatively thin zone of stromal tissue. Glands are entirely absent from this region and the cyclic changes are confined to the epithelium. The uterine epithelium gradually merges with the cervical epithelium which exhibits a similar series of changes but less marked. The cervical epithelium of the immature animal is thin and composed of a single layer of flattened cells. At the first œstrus it becomes columnar, and during pregnancy exhibits changes in height and in the arrangement of the nuclei in the cells which resemble those in the uterus, but are not nearly so clearly defined. The cervical region is short and just within the external os the epithelium merges abruptly with the typical vaginal epithelium.

XI—The Vaginal Cycle

a. *The prepubertal vagina*

The upper part of the vagina of immature animals, fig. 40, Plate 6, is circular in transverse section and measures approximately 1 mm in diameter. It has a thick wall composed of outer longitudinal and inner circular muscle layers, a wide zone of fibrous connective tissue merging with the narrow zone of less fibrous sub-epithelial stroma lying immediately beneath the stratified epithelium, which is 30 to 50 μ thick. These layers thus correspond to those forming the uterine wall, but glands are absent. The lumen is simple, only low longitudinal folds being formed in the epithelium. The basal part of the epithelium is thrown into shallow folds which project into the sub-epithelial stroma. The relative thickness of the various layers of the vaginal wall can be seen from fig. 40, Plate 6. The surface of the epithelium next the lumen will, for convenience of description, be termed superficial. The epithelial cells next the lumen are flattened and are sloughed off into the lumen. They are normally nucleated. Well-grown immature animals in the later part of the summer and early autumn sometimes exhibit precocious pro-œstrous cornification of the superficial layers of the epithelium, but this gives place to the nucleated condition as winter approaches. The lower region of the vagina, fig. 42, Plate 6, between the vulva and the opening of the urethra, is much thinner walled, owing to reduction of the muscular and fibrous coats. The lumen in this region is much larger, being wide and slit-like laterally but flattened dorso-ventrally. The epithelial lining is thrown up into deep irregular folds. The lumen contains desquamated nucleated epithelial cells and leucocytes. The epithelium consists of stratified nucleated epithelium 20 to 40 μ thick in which scattered leucocytes are present. The region of the vagina, fig. 41, Plate 6, between the upper part and the urethral opening is closed in the immature animal, the lumen being completely absent and the epithelium being represented by a solid band 15 to 25 μ thick with short branches.

Pro-œstrous changes in the immature animal set in at the end of March. They consist, in the upper region of the vagina, of widening of the lumen accompanied by deepening of the epithelial folds projecting into it, and of increasing cornification of the superficial layers of the epithelium. In the lower region the lumen extends upwards to meet that of the upper region. Simultaneously, the epithelium becomes thicker and more folded ; finally, its superficial layers become cornified, though the cornification is less intense than in the upper region.

b. The vagina during first œstrus

During the first œstrous period the vagina exhibits a very characteristic appearance. The upper part, fig. 43, Plate 6, which measures about 2 mm in diameter, exhibits intense cornification of the epithelium. Early in œstrus, when masses of semen are present in the lumen, the epithelium reaches a maximum thickness of 50 to 110 μ. The superficial layers, to a depth of 40 to 85 μ, are completely cornified and exhibit no traces of cellular structure, fig. 47, Plate 6. The cells immediately beneath the cornified material are flattened and contain conspicuous granules, presumably of keratin, in the cytoplasm, but flattened nuclei can be distinguished in them. These cells are intermediate stages between the normal cells in the basal layers and the cornified material superficially. Later in œstrus the thickness of the epithelium is reduced to 25 to 60 μ owing to sloughing of the cornified material, masses of which are then to be found in the lumen together with a few sperms and leucocytes. The sub-epithelial stroma becomes hyperæmic in late œstrus and leucocytes are plentiful in it. The epithelium throughout the lower region of the vagina, fig. 44, Plate 6, measures 30 to 50 μ in thickness. It exhibits cornification of the superficial layers, but less intensely than the upper part, the completely cornified material only measuring 10 to 20 μ in thickness. Leucocytes are also found in the sub-epithelial stroma in this region.

c. The vagina during pregnancy

After ovulation, when ova are in the tubes, the hyperæmia of the sub-epithelial stroma becomes more intense and is accompanied by extensive extravasation of blood and accumulation of large numbers of leucocytes beneath the epithelium, fig. 48, Plate 7. The cornification of the epithelium, which is 20 to 30 μ thick, proceeds so far that non-cornified epithelial cells are only present as a single basal layer, which is interrupted in places. Here and there rupture of the epithelium occurs allowing the escape of some red blood-corpuscles and large numbers of leucocytes into the lumen, where they are mixed with the masses of cornified material. By the time the ova have attained the blastocyst stage and are about to pass from the tubes into the uteri both the cornification of the epithelium and the hyperæmia of the stroma have subsided. The epithelium, which measures 25 to 35 μ in thickness, re-forms. It then consists entirely of nucleated cells, but sloughing of the most superficial, which are flattened and contain keratin granules in the cytoplasm, continues. There is little non-nucleated cornified material and leucocytes are scarce in the lumen. The epithelium of the lower region, which is 15 to 45 μ in thickness, is also nucleated throughout and exhibits sloughing of the superficial layers. Leucocytes are very numerous in the stroma and epithelium. Leucocytes, cornified material and nucleated epithelial cells are present in the lumen.

Throughout the uterine stage of pregnancy the epithelium of both the upper and lower regions is nucleated and epithelial cells are being sloughed continually into the lumen. Leucocytes are plentiful until shortly before parturition in the stroma, epithelium and lumen. The upper region of the vagina gradually decreases in diameter reaching a minimum after implantation, when it measures 1 mm or less. The epithelium also decreases in thickness and the folds fuse with their neighbours on each side, reducing the lumen to a narrow central passage only a few μ in diameter or occluding it altogether in places. The epithelium in this extreme condition, fig. 46, Plate 6, is in the form of a central, nearly solid core approximately 100 μ in diameter, from which a number of solid epithelial lamellæ 7 to 25 μ in thickness radiate. This occlusion of the upper vagina during pregnancy has not been described in any other animal so far as we are aware. Parkes (personal communication) has observed a somewhat similar condition in the fox, in which the vagina becomes reduced to a narrow cord of tissue during pseudo-pregnancy. At the end of pregnancy the leucocytes disappear from the lumen and mucosa and the epithelium thickens enormously. Many of the cells of the basal layers exhibit mitoses and the epithelium attains a thickness of 40 to 200 μ at parturition. The vagina at this stage, fig. 50, Plate 7, measures 2·5 to 3 mm in diameter.

The changes in the vagina during the early stages of pregnancy in parous animals differ from those during the first pregnancy. There is no distinct fibrous layer between the sub-epithelial stroma and the muscularis in vaginæ of parous animals. This difference in the vaginæ is strictly comparable to that in the uteri of parous and non-parous animals. During the period immediately following ovulation the vagina of a parous animal measures approximately 3 mm in diameter. Some extravasation takes place in the sub-epithelial stroma, but this is not nearly so marked as in the non-parous animal. The epithelium is nucleated, not cornified, and measures 40 to 100 μ in thickness. Nucleated epithelial cells alone are present in the lumen. Leucocytes are numerous in the stroma and have appeared both in the epithelium and lumen by the time the ova have reached the blastocyst stage. The subsequent changes are similar to those during the first pregnancy.

d. The post-partum œstrous vagina

The vagina during the post-partum œstrus, fig. 45, Plate 6, is large with a thick nucleated epithelium, as it was at the end of pregnancy. Even the most superficial layers of the epithelium retain their nuclei and do not become completely cornified, although granules of keratin are visible in the cytoplasm. Leucocytes are numerous in the epithelium and, together with nucleated epithelial cells, in the lumen at the beginning of the post-partum œstrus. The leucocytes disappear from both and the epithelial cells from the lumen during late œstrus. The vagina is distended with a plug of semen, the lumen measuring as much as 2 mm in diameter immediately after copulation.

e. The anœstrous vagina

During lactation anœstrus the vaginal epithelium is nucleated both in the upper and lower regions and nucleated epithelial cells are present in the lumen. The thickness of the epithelium varies considerably in different individuals being only 10 to 30 μ in one animal, and as much as 40 to 120 μ in another at the other extreme. The number of leucocytes varies considerably in different individuals; the majority have many both in the mucosa and lumen, but in some none are to be found in either the epithelium or the lumen. The upper part of the vagina is large during lactation, varying from 1·5 to 1·8 mm in diameter.

The condition of the vagina varies widely in the four parous animals which were neither pregnant nor lactating. One (S. 1214), obtained in November, was evidently in late metœstrus, fig. 49, Plate 7, possibly entering on anœstrus. The vaginal epithelium was thick, measuring 40 to 70 μ, and in places the superficial layers were cornified to a depth of 30 μ. Cornified material and numerous leucocytes were present in the lumen. Leucocytes were also very numerous in the mucosa. Another animal (S. 1257), obtained in August, had a large vagina, the upper region measuring 1·6 mm in diameter, with an entirely nucleated epithelium 40 to 130 μ thick. Nucleated epithelial cells only were found in the lumen. Leucocytes were absent from the mucosa as well as the lumen. The two animals, obtained in February (S. 646) and March (S. 559), which were truly anœstrus, had vaginæ 1·1 to 1·5 mm in diameter in the upper region with a relatively thin nucleated epithelium 10 to 30 μ in thickness. Leucocytes were numerous in the lumen and mucosa in both. Nucleated epithelial cells were mixed with the leucocytes in the lumen of one (S. 646). Partial fusion of the epithelial folds, resulting in reduction and simplification of the lumen, had occurred in one (S. 559).

XII—The Changes in the Mammary Glands

The mammary glands of the shrew exhibit remarkably little development at the time of the first œstrus and during the earlier stages of the first pregnancy when the segmenting ova are still in the Fallopian tubes. The ducts, usually two in number, extend only some 2 or 3 mm from the nipple at this time. Each duct may have several blunt processes upon it and in one specimen, with 8-cell stages in the tube, these exhibit swollen vesicular endings, fig. 51, Plate 8, such as have been described by Cole (1933) and others as characteristic of œstrus in the mouse. The ducts extend outwards as pregnancy progresses and more branches develop on them. Glandular alveoli, staining more densely in whole mounts than the ducts, are formed around the tips of the smaller branches. The degree of development attained at any stage of pregnancy varies considerably from specimen to specimen, but in all the glands continue to extend up to the end of pregnancy. During the later part of pregnancy, fig. 52, Plate 8, the glands thicken considerably and in consequence it becomes impossible to distinguish detail in them. They enlarge still further during lactation and reach a maximum, fig. 53, Plate 8, at the time when the embryos of the pregnancy resulting from the post-partum œstrus are at the stage of free uterine blastocysts. At this time the glands are enormous for the size of the animal. The anterior glands extend from the groin around the loins and over the hips, almost meeting in the mid-dorsal line. The posterior glands similarly extend from the anus, which they surround closely, round the gluteal region, and meet or even slightly overlap above the root of the tail. The middle pair of glands covers the whole ventral surface of the abdomen. The glands are also remarkably thick, the posterior ones often attaining a thickness of over 2 mm. After implantation the mammary glands begin to retrogress and by the time parturition is approaching they have decreased in size considerably and are no larger than at the close of the first pregnancy.

The mammary glands of ten parous animals which were pregnant exhibited marked retrogression in comparison to the other pregnant lactating animals. It was assumed that these animals had lost their litters at or soon after parturition. One of these, S. 1254, was kept in captivity for 10 days and contained implanted embryos when it died. Probably it was caught soon after post-partum œstrus and therefore had only been lactating for a short time prior to being caught. Since the litter was not obtained it had ceased to lactate for at least 10 days and probably not much longer. The glands of this animal had retrogressed as much as those of any other animal obtained. It is clear from this that retrogression of the glands must be extremely rapid. Such retrogressed glands, fig. 54, Plate 8, though no larger than those of non-parous animals during mid-pregnancy, can be distinguished from them by their more compact and homogeneous appearance, the individual alveoli being scarcely distinguishable, and by the large size of the ducts in the vicinity of the nipples. Although they have decreased in extent and become very thin, none were obtained as small as at the beginning of the first pregnancy.

The mammary glands of the two anœstrous animals obtained during mid-winter were not available so that the final stage of retrogression is unknown.

XIII—ABNORMALITIES

a. Super-ovulation

One animal exhibited the rare phenomenon of super-ovulation and therefore deserves special description. This animal, S. 944, was obtained on May 22 and weighed 9·4 gm. The histology of the uterus showed clearly that it was non-parous. One ovary (A) contained a single corpus luteum 432 μ in diameter, and there was a single blastocyst corresponding to it in the tip of the uterine cornu of the same side close to the opening of the Fallopian tube into the uterine lumen. The other ovary (B) contained six corpora lutea, 444, 452, 492, 500, 520, and 524 μ in diameter respectively, the histological condition, fig. 20, Plate 2, of which, as well as the size, clearly showed that they belonged to the same set as the corpus luteum in ovary A. The uterine cornu corresponding to ovary B had been cut near the tip before embedding. The upper portion was found to contain one blastocyst, and two other blastocysts were found at the cut surface of the lower portion. It is probable, therefore, that three blastocysts, corresponding to the three remaining corpora lutea, were lost when the uterus was cut. Ovary B also contained four newly formed corpora lutea, fig. 20, Plate 2, in which the central cavity was present and in which the cells of the membrana granulosa had undergone little enlargement. These corpora lutea measured 264, 304, 320, and 328 μ in diameter respectively, and evidently constituted a second set arising from an ovulation which occurred after the ova from the previous ovulation had begun to develop. Corresponding to this second set of corpora lutea four ova, all in the 2-cell stage, were found in the proximal part of the Fallopian tube attached to ovary B. These four segmenting ova were all close together and were each surrounded by the remains of the discus proligerus.

The stage of development and position of the blastocysts indicated that they had only recently reached the uterine lumen. The size and histological characters of the first set of corpora lutea corresponded with those of other animals containing early uterine blastocysts at this stage. The condition of the uterus, in which the epithelium exhibited the characteristic arrangement of nuclei in several rows, was also consistent with late tubal or early uterine blastocysts. The 2-cell stages were in the same region of the tube as were the same stages in other animals and the size and condition of the second set of corpora lutea also corresponded. There was one atretic follicle in each ovary, probably belonging to the same set as gave rise to the second set of corpora lutea. There was also a group of six large follicles, averaging 267 μ in diameter, in ovary A and one in ovary B, which would presumably ovulate at the next œstrus. Sperms were found in the Fallopian tubes. These may have persisted from the copulation preceding the first ovulation, but they were sufficiently numerous to suggest that copulation had occurred after the first and before the second ovulation. The mean diameters of the two sets of corpora lutea are plotted in fig. 9, the first set being put in the appropriate place in the series of pregnancies on the basis of the stage of the blastocysts and the second set on the basis of the 2-cell stages. The evidence for super-ovulation in this animal appears, therefore, to be conclusive.

b. Non-parous adult in autumn

One animal, S. 1143, was obtained with a number of other adults under the stooks of a barley field near Hitchin, Herts, on September 5, 1932. This animal proved to be unique in several respects and requires separate description. It weighed 11 gm and was pregnant, the embryos being late blastocysts, fig. 26, Plate 3, spaced out, each in a spherical chamber, in the uterine cornua and just beginning to adhere in places to the uterine epithelium. There were 10 blastocysts, five in each cornu, and an unsegmented and degenerating ovum in one (cornu A) as well. The mammary glands were preserved and showed clearly that the animal was non-parous. The histological appearance of the uterus supported this conclusion, although not in itself conclusive owing to the changes due to the existing pregnancy. The animal is therefore unique in being the only non-parous adult obtained after June. It is probable, from its large size, that it was born the previous year, but it is possible that it was a very exceptionally developed animal born early in the same season. It was also unique in having 17 corpora lutea in the 2 ovaries. Ovary A contained 8 corpora lutea, of which 3 were definitely smaller than the others. Ovary B contained 9 corpora lutea, of which 1 was cystic and consequently abnormally large, and 4 were definitely smaller than the others. No signs of retained ova were found in any of these, the mean diameter of which (excluding the cystic one) was 409 μ. The ten large corpora lutea resembled each other histologically and had a mean diameter of 487 μ (excluding that which was cystic). The seven small corpora lutea also resembled each other histologically, but differed from the larger ones. They had a mean diameter of 309 μ. The connective tissue reticulum in them was better developed and the luteal cells did not appear so plump as in the larger ones ; than which they appeared to be slightly older in consequence. It is clear that either (*a*) all the corpora lutea formed a single set resulting from a single ovulation or (*b*) that they formed two sets of 3 + 4 and 5 + 5 respectively, resulting from two consecutive ovulations. The first alternative is supported by the fact that ten embryos and one degenerating ovum were present in the uterus. Even if it were assumed that the embryos were derived from the ten ova presumably liberated at the second ovulation the degenerating ovum could only be accounted for by assuming its persistence from the previous ovulation. Moreover, no other animal was obtained with more than one recent set of corpora lutea. The second alternative is supported by the histological differences in the corpora lutea, but these might possibly have been caused by the overcrowding resulting from the presence of so large a number in the ovaries. The fact that no other animal was obtained with more than 12 corpora lutea in a set supports this alternative. The second alternative postulates that the first ovulation, which may or may not have been preceded by copulation, did not result in pregnancy and was followed by a second which did ; the interval between the two being sufficiently short to allow of the persistence of the first set of corpora lutea and one of the ova. It is impossible on the evidence to decide which hypothesis is true, but in either case the animal is so exceptional that it is probable that it was functionally abnormal.

Part of this investigation was carried out during the summer of 1932 at the National Institute for Medical Research through the courtesy of the Medical Research Council and Sir HENRY DALE, Sec. R.S. The author is greatly indebted to them for the hospitality and for the many facilities provided. The author's thanks are due to Dr. A. S. PARKES, F.R.S., and Mrs. PARKES for their advice and for collecting a large part of the material from the home counties, to Professor J. P. HILL, F.R.S., for advice, and to Messrs. L. H. JACKSON and I. W. ROWLANDS for much assistance in the routine trapping in N. Wales. The work would have been almost impossible without their co-operation. The author is indebted to Professor R. G. WHITE and Messrs. H. A. COLE, W. H. EDWARDS, M. H. FOSTER and other friends for collecting material for him.

The author is indebted to the Rt. Hon. Lord PENRHYN for permission to trap on his estates, where many of the animals were obtained.

The expenses of this research were defrayed in part by grants from the Government Grant Committee of the Royal Society, for which we wish to express our thanks.

XIV—Summary

The material consisted of 1064 Common Shrews, of which 487 were females, collected during every month of the year. The majority were trapped in North Wales.

The sex-ratio for the whole material was 54 ± 1·03 males %. The percentage of males was remarkably high during April and May.

The structure of the female reproductive organs is described. The most remarkable features being the closed periovarian cavity, single cervical canal, and the presence of upper and lower regions in the vagina, differing structurally from each other. A circular fold projecting into the vaginal lumen marks the junction of these two regions and probably represents the "hymen."

The smallest immature animals taken in the traps weighed over 4 gm. At the end of the breeding season most of the immature animals weigh from 7 to 9 gm but they lose weight during the winter, weighing from 5 to 7 gm in January to March. During April they increase rapidly in weight and become mature. Mature females vary from 6 to 15 gm but the majority are 10 to 13 gm.

The data provide strong evidence that female shrews live over a single winter only and die at the close of their first breeding season, the year following that in which they are born.

The onset of the first œstrus is gradual and mating takes place between April 29 and May 20. There is a post-partum œstrus which differs from the first œstrus chiefly in the absence of vaginal cornification.

Animals which fail to become pregnant at the post-partum œstrus pass into lactation anœstrus. Such animals become relatively increasingly common as the season progresses. During lactation anœstrus corpora lutea are absent from the ovaries.

Two parous animals were obtained in winter and both were in anœstrus.

The breeding season, as defined by the occurrence of pregnant females, extends from May to September inclusive in North Wales. It lasts until the end of October in the Home Counties of England.

Ovulation results in pregnancy in approximately 100% of cases and must therefore always be accompanied by copulation. Pseudo-pregnancy does not occur.

From May 20 to the end of July 90% of adult females are pregnant. Therefore pregnancy normally must follow the post-partum œstrus simultaneously with lactation.

The average size of litter, as determined from the number of embryos in the uterus, is 6·45. The mean number of corpora lutea in a set is 7·35, and of maturing follicles 8·35.

The size of litter appears to decline after June. This decline is probably due to increased intra-uterine mortality. Comparison of the number of embryos and corpora lutea shows that the intra-uterine mortality is twice as great when eight or more as it is when seven or less ova are ovulated.

The distribution of implanted embryos in the two uterine cornua is not fortuitous but shows a pronounced tendency to equality on the two sides, but the distribution of maturing follicles and of corpora lutea between the two ovaries is fortuitous. The equal distribution of the embryos is due to migration of the blastocysts directly from one cornua to the other prior to implantation.

The period of gestation and of lactation is not less than 13 and probably not more than 19 days.

There is evidence that implantation of the embryos is delayed in parous animals which are lactating, as has been observed in the rat and the mouse (KIRKHAM, 1916).

Immature females exhibit signs of precocious sexual activity in the autumn of the season in which they are born. Follicular growth and vaginal cornification occur but there is no evidence that they become functionally mature. Such animals gradually pass into the typical winter condition.

The growth relations of the ovum and the follicle are described and resemble those of other animals. The mature ovum measures 72 μ in diameter. The smallest follicles measure 16 μ in diameter, the antrum appears at 160 μ in diameter approximately, and the mature follicles about to ovulate measure 325 to 350 μ in diameter. The antrum of the mature follicle is very small.

The mode of formation and structure of the corpus luteum is described. The mean diameter of the largest set of corpora lutea observed was 638 μ, but the majority do not exceed 500 μ in diameter at their maximum. Luteal retrogression begins before parturition and is marked by mitoses in the luteal cells. At parturition the corpora lutea are only 200 to 250 μ in diameter, and they have disappeared completely soon after parturition.

The changes in the Fallopian tubes are described. The part of the tube proximal to the ovary is ciliated, but the part distal to the ovary is not ciliated at any stage.

The non-parous uterus has a fibrous connective tissue zone between the mucosa and muscularis which is absent in parous animals. During pregnancy the nuclei in the epithelium, which is columnar, are arranged at first in a single row at the basal ends of the cells. At the time when the ova reach the blastocyst stage the nuclei become rearranged in several layers. Shortly before implantation spherical chambers are formed by the extension of the lumen around the blastocysts. The parous uteri are characterized by the thick hyaline walls of the blood vessels.

The upper part of the vagina of non-parous animals has a fibrous connective tissue layer between the mucosa and muscularis corresponding to that in the uterus. This is absent from the lower part of all vaginæ and from the upper part in parous animals. The region of the vagina between the upper part and the urethral orifice is closed in immature animals.

The vaginal epithelium exhibits intense cornification during the first œstrus. After œstrus the cornified material is sloughed and the mucosa becomes intensely hyperæmic and extravasation occurs. Leucocytes are then found in the mucosa and lumen and the nucleated epithelium re-forms. During mid-pregnancy the lumen of the upper part of the vagina becomes reduced and finally occluded by fusion of the epithelial folds. The vaginal epithelium at parturition is very thick and nucleated. It does not become cornified at the post-partum œstrus. The epithelium during anœstrus is thin and leucocytes are frequently present.

The mammary glands show very little development at the first œstrus but the ducts exhibit characteristic bulb-shaped endings. The changes in the glands during pregnancy, lactation, and retrogression are described.

An interesting and unique case of super-ovulation is described, with blastocysts in the uterus, 2-cell stages in the Fallopian tubes, and two distinct sets of corpora lutea corresponding.

XV—References

Adams (1910). ‘ Mem. Proc. Manchester Lit. Phil. Soc.,’ vol. **54**, No. 10.

Ärnbäck-Christie-Linde (1907). ‘ Morph. Jahrb.,’ vol. **36**, p. 463.

Barrett-Hamilton (1911). “ A History of British Mammals.” London, Pt. 8, p. 82.

Baxter (1933). ‘ J. Anat.,’ vol. **67**, p. 555.

—— (1934). ‘ J. Anat.,’ vol. **68**, p. 239.

Brambell (1928). ‘ Proc. Roy. Soc.,’ B, vol. **103**, p. 258.

Cole (1933). ‘ Proc. Roy. Soc.,’ B, vol. **114**, p. 136.

Deanesly and Parkes (1933). ‘ Phil. Trans.,’ B, vol. **222**, p. 47.

Deanesly (1934). ‘ Phil. Trans.,’ B, vol. **223**, p. 239.

Hain (1934). ‘ J. Exp. Biol.,’ vol. **11**, p. 279.

Hubrecht (1890). ‘ Quart. J. micr. Sci.,’ vol. **31**, p. 499.

—— (1894). ‘ Quart. J. micr. Sci.,’ vol. **35**, p. 481.

Kirkham (1916). ‘ Anat. Rec.,’ vol. **11**, p. 31.

—— (1918). ‘ J. Exp. Zool.,’ vol. **27**, p. 49.

Middleton (1931). ‘ Proc. Zool. Soc. Lond.,’ p. 133.

Millais (1904). “ The Mammals of Great Britain and Ireland.” London, vol. **1**, p. 141.

Mirskaia and Crew (1931). ‘ Proc. Roy. Soc. Edin.,’ vol. **51**, p. 1.

Parkes (1931). ‘ Proc. Roy. Soc.,’ B, vol. **109**, p. 185.

Zuckerman and Parkes (1932). ‘ Proc. Zool. Soc. Lond.,’ p. 139.

XVI—DESCRIPTION OF PLATES

PLATE 1

FIG. 10—Photograph of the ventral aspect of a dissection of the reproductive organs *in situ* of a female Common Shrew. The upper part of the long vagina is bent back ventrally so that the uterus crosses the lower part just in front of the bladder. × 2·5.

FIG. 11—Photograph of the female reproductive organs dissected out. The lower part of the figure shows the organs displayed from the ventral surface. The great length of the vagina and the loops of the Fallopian tubes around the ovaries are seen. The upper part of the figure is a lateral view of a specimen showing the vaginal flexure. × 2·7.

FIGS. 12 and 13—Drawings of the ovary, Fallopian tube and associated structures. Fig. 12 is of the apparent ventral but true dorsal aspect. In fig. 13 the ovary is flexed to show the true ventral aspect. The wide proximal (*PT*) and narrow distal (*DT*) regions of the Fallopian tube can be distinguished and the junction with the tip of the uterine cornu (*UC*) laterally. The ovarian (*OV*) and uterine (*UV*) vessels are shown. The ovarian capsule (*OC*) is thin and transparent and completely encloses the ovary (*O*). The broad ligament (*LB*), suspensory ligament (*LS*), and round ligament (*LR*) are shown. × 10 approx.

FIG. 14—Semi-diagrammatic drawing of a longitudinal section of the upper part of the uterine cornu showing the opening of the Fallopian tube (*FT*) into it. *VE* = uterine epithelium. *M* = sub-epithelial mucosa. *FZ* = fibrous connective tissue zone present in non-parous animals only. *CM* = circular muscle. *LM* = longitudinal muscle. × 42 approx.

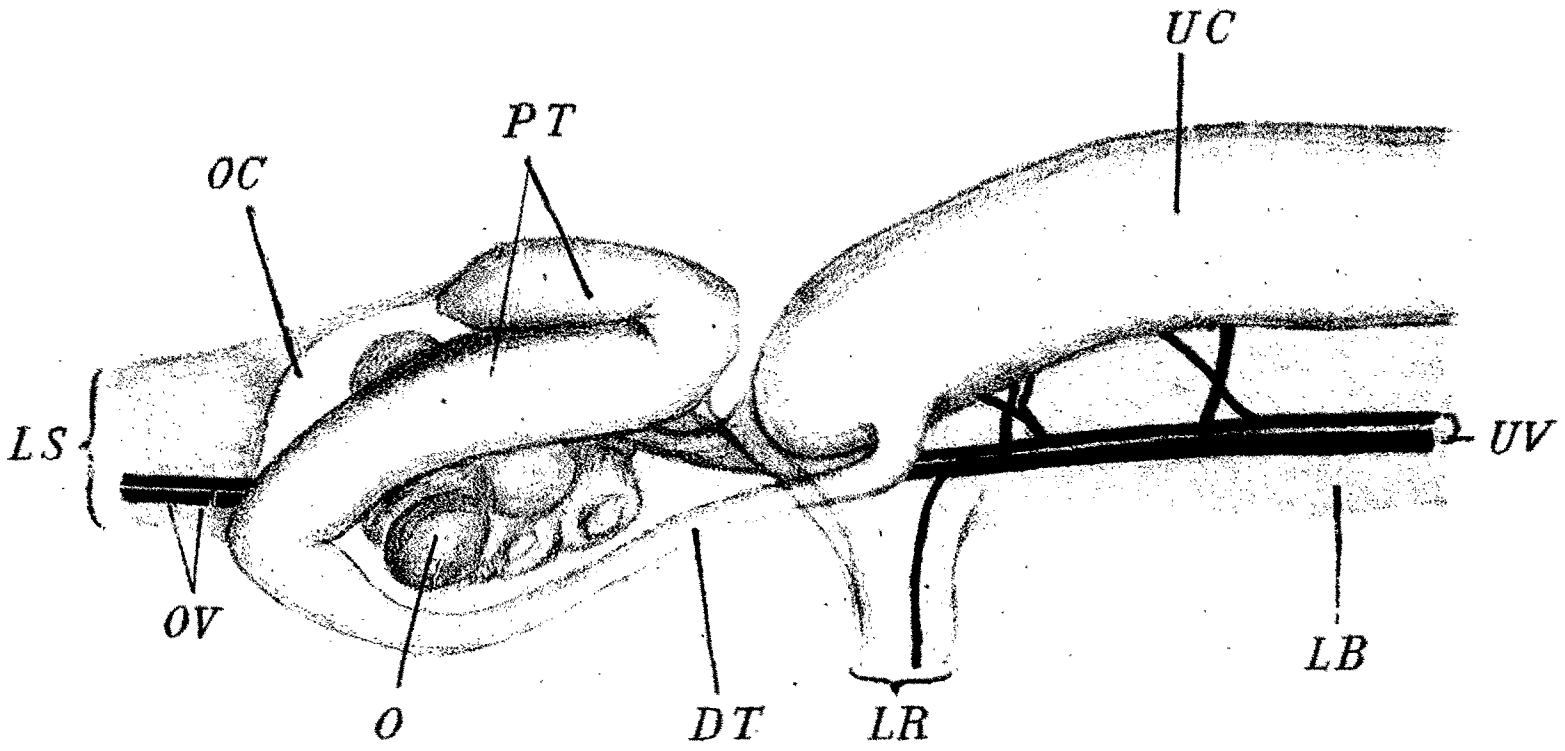

13

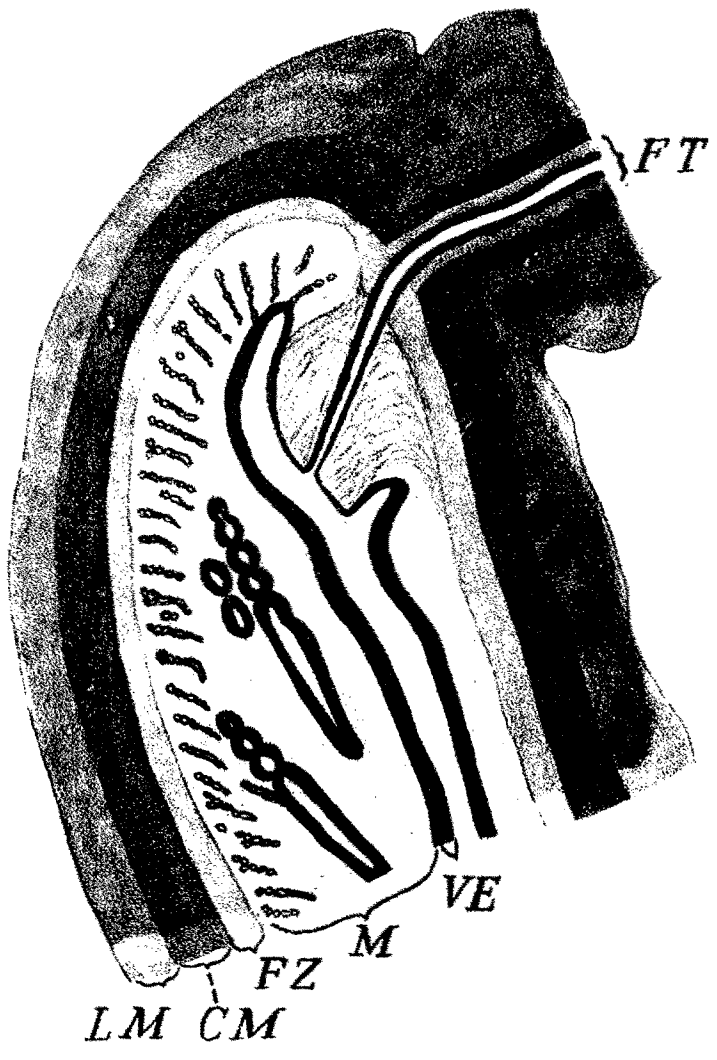

14

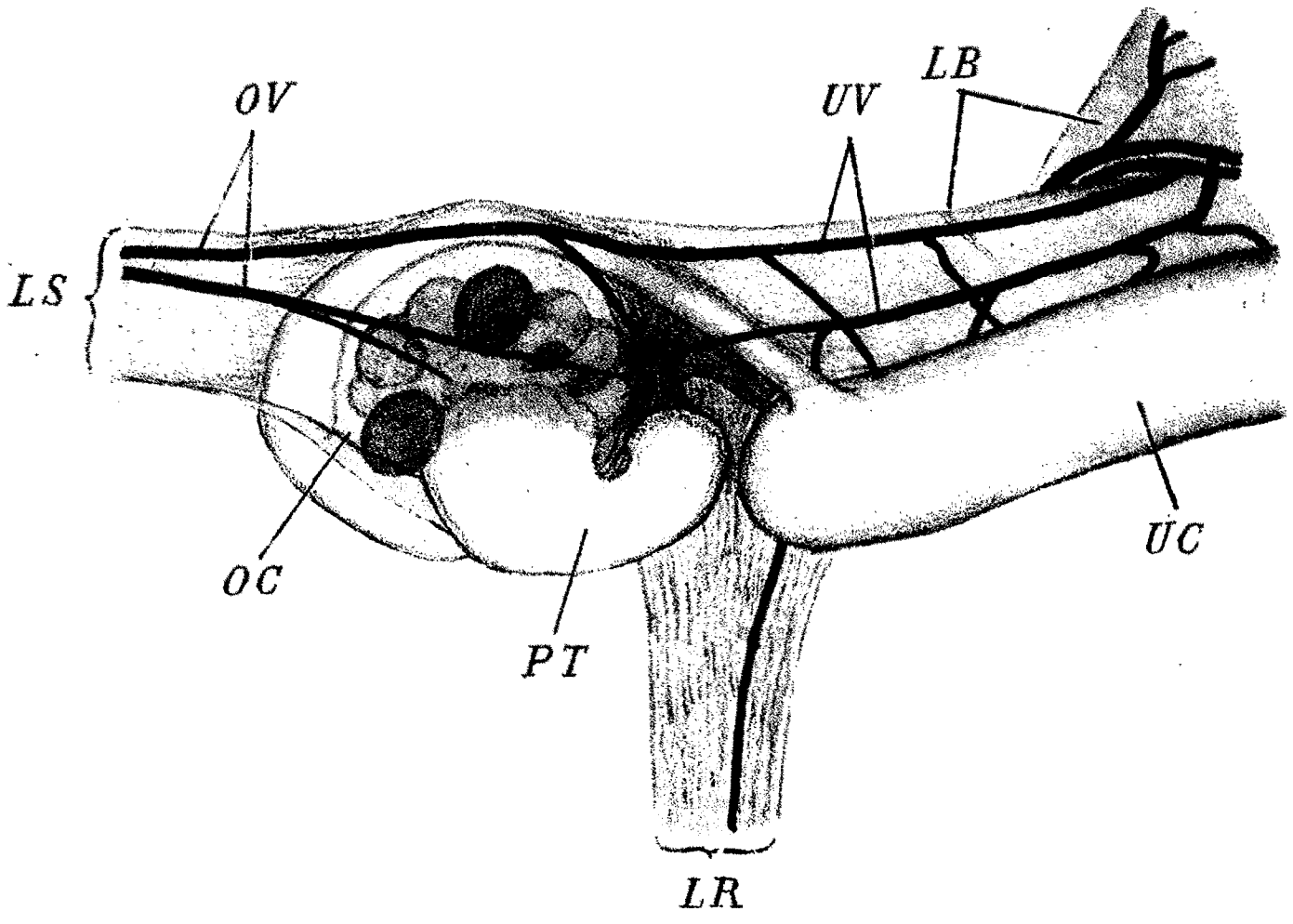

12

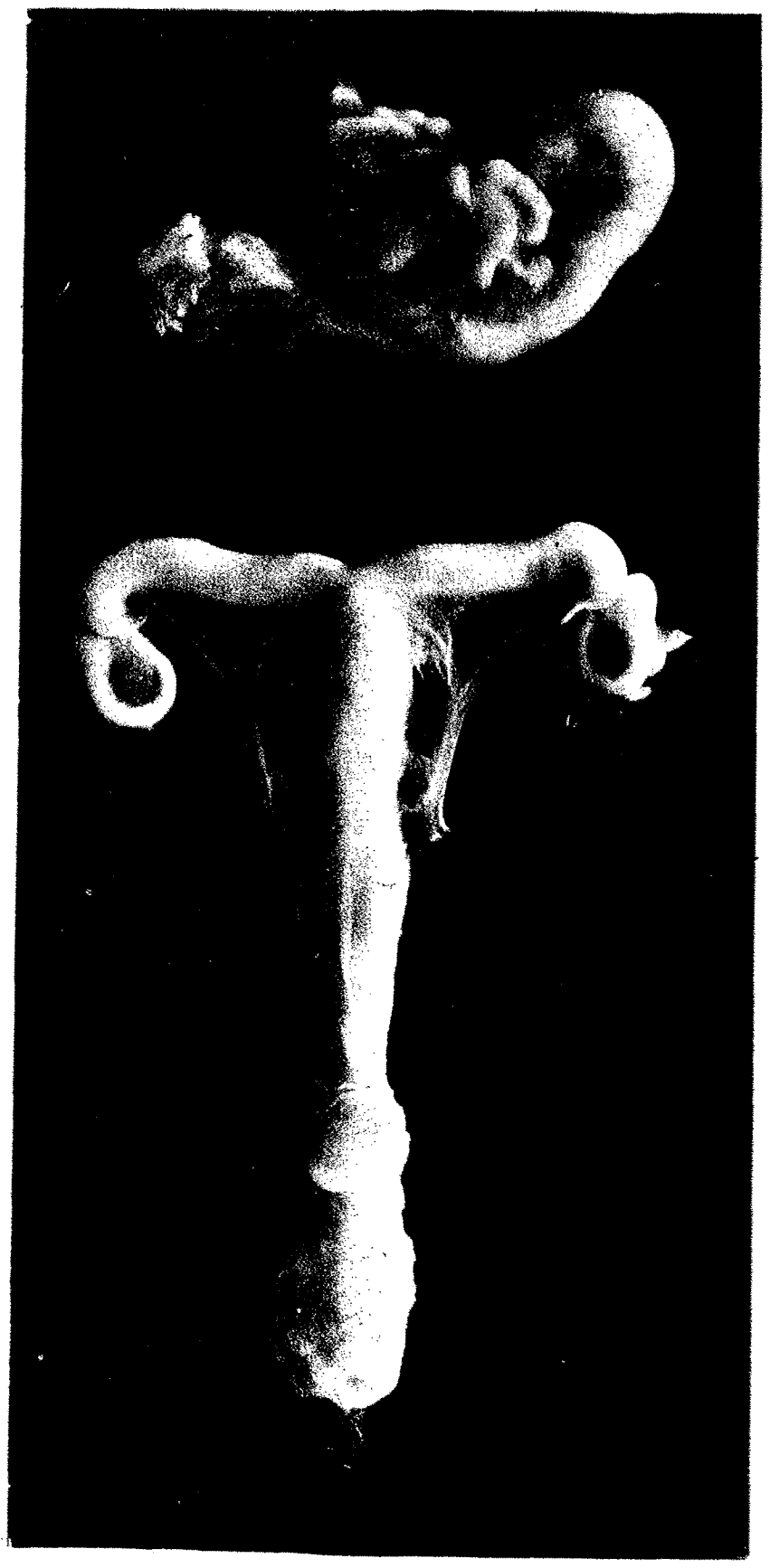

11

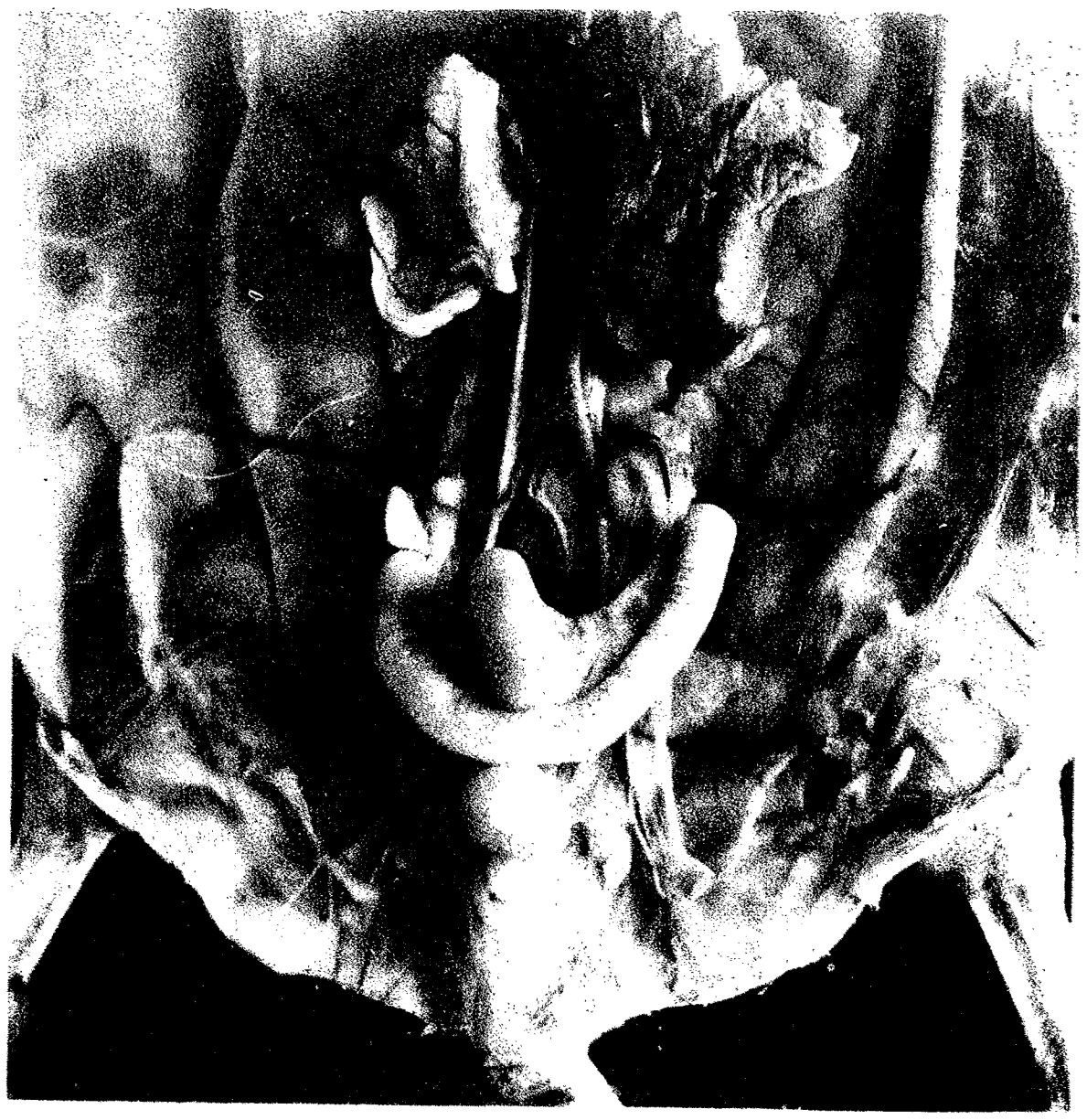

10

PLATE 2

FIG. 15—Photomicrograph of a recently ruptured follicle (S. 879) showing that the follicular wall is not folded. The ova, in the proximal part of the Fallopian tube, contain 2nd polar spindles and sperms are present in the vagina. × 220.

FIG. 16—Photomicrograph of the developing corpus luteum (S. 20) showing the first indications of connective tissue ingrowth from the theca. The cavity is still patent. The ingrowth of the membrana granulosa is active ; the cells are enlarging and their nuclei are becoming rounded. The ova are in the proximal part of the Fallopian tube and exhibit 1st cleavage spindles. × 200.

FIG. 17—Photomicrograph of the corpus luteum at the stage (S. 943) when the blastocysts have passed recently into the uterus. The luteal cells are large with rounded nuclei and the corpus luteum is hyperæmic. The connective tissue reticulum is not fully developed. × 167.

FIG. 18—Photomicrograph of the corpus luteum at its maximum development (S. 1129) shortly before implantation of the blastocysts. The luteal cells are very large and the connective tissue reticulum is well developed. The corpus luteum is hyperæmic and its centre is occupied by a small clot. × 127.

FIG. 19—Photomicrograph of the corpus luteum at approximately full time (S. 949). It is small, shrunken and obviously retrogressing. × 253.

FIG. 20—Photomicrograph of a section of the ovary of S. 944 which exhibited super-ovulation. One of the newer set of corpora lutea, corresponding to the 2-cell tubal ova, is in the centre with parts of three of the older set of corpora lutea, corresponding to the uterine blastocysts, surrounding it. × 133.

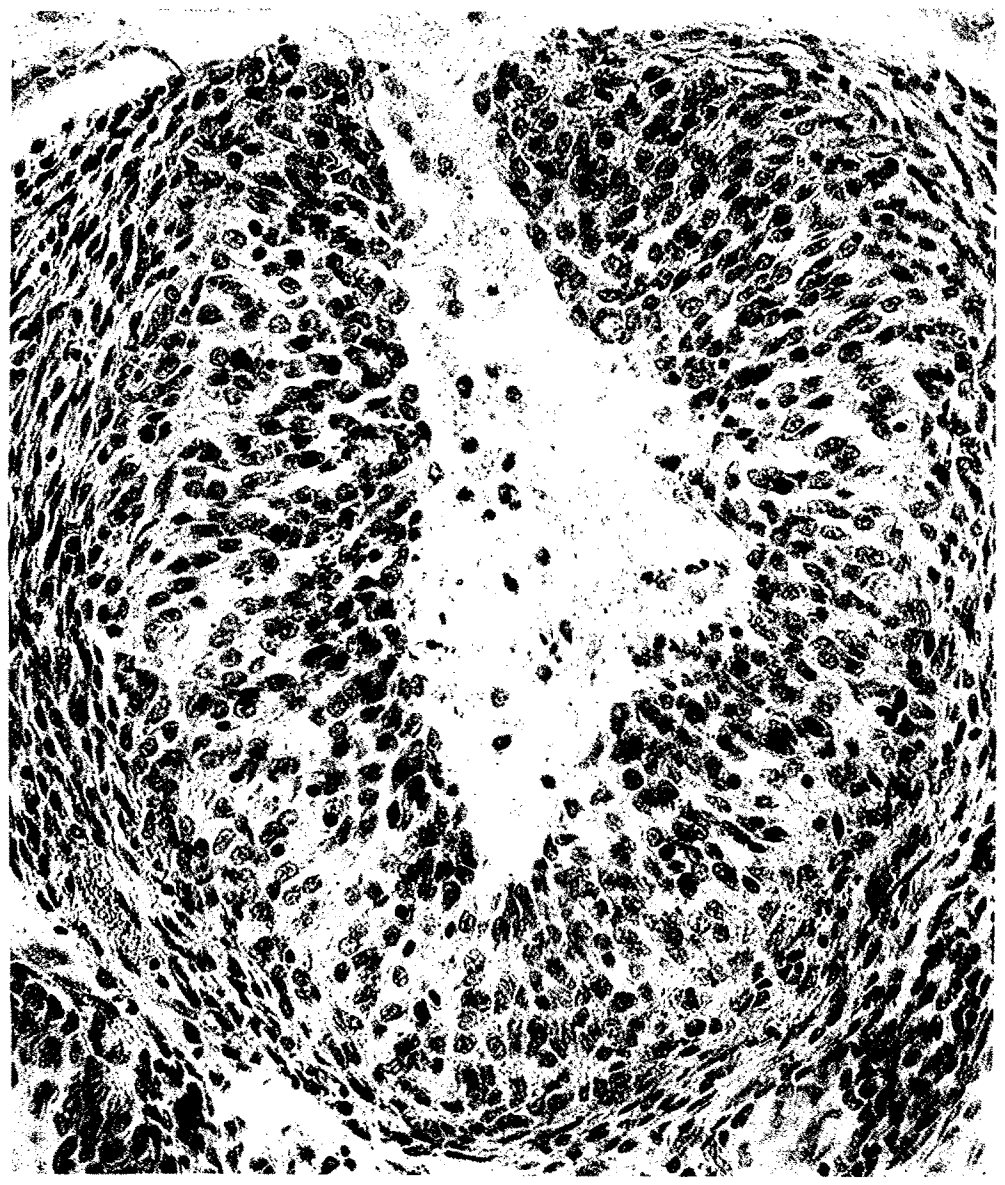

15

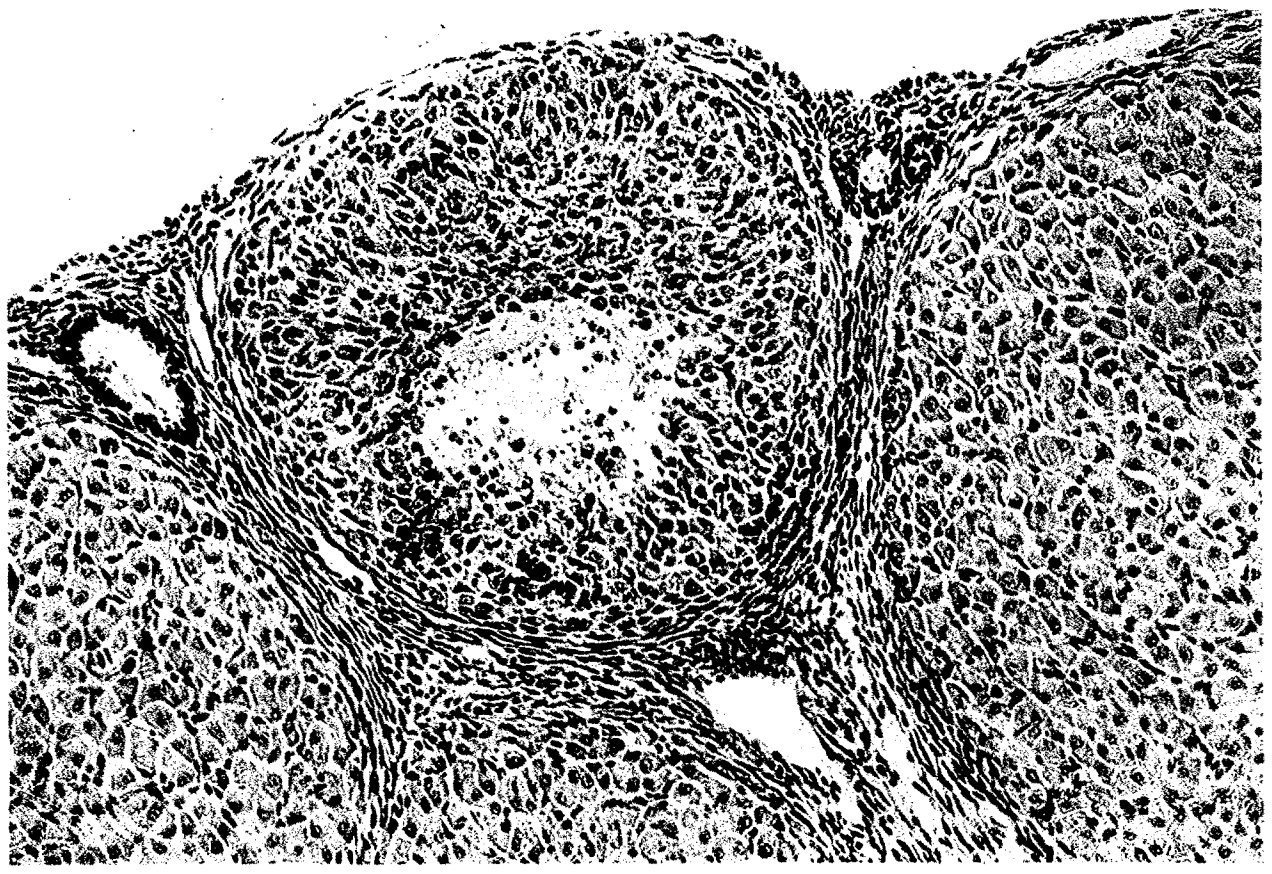

20

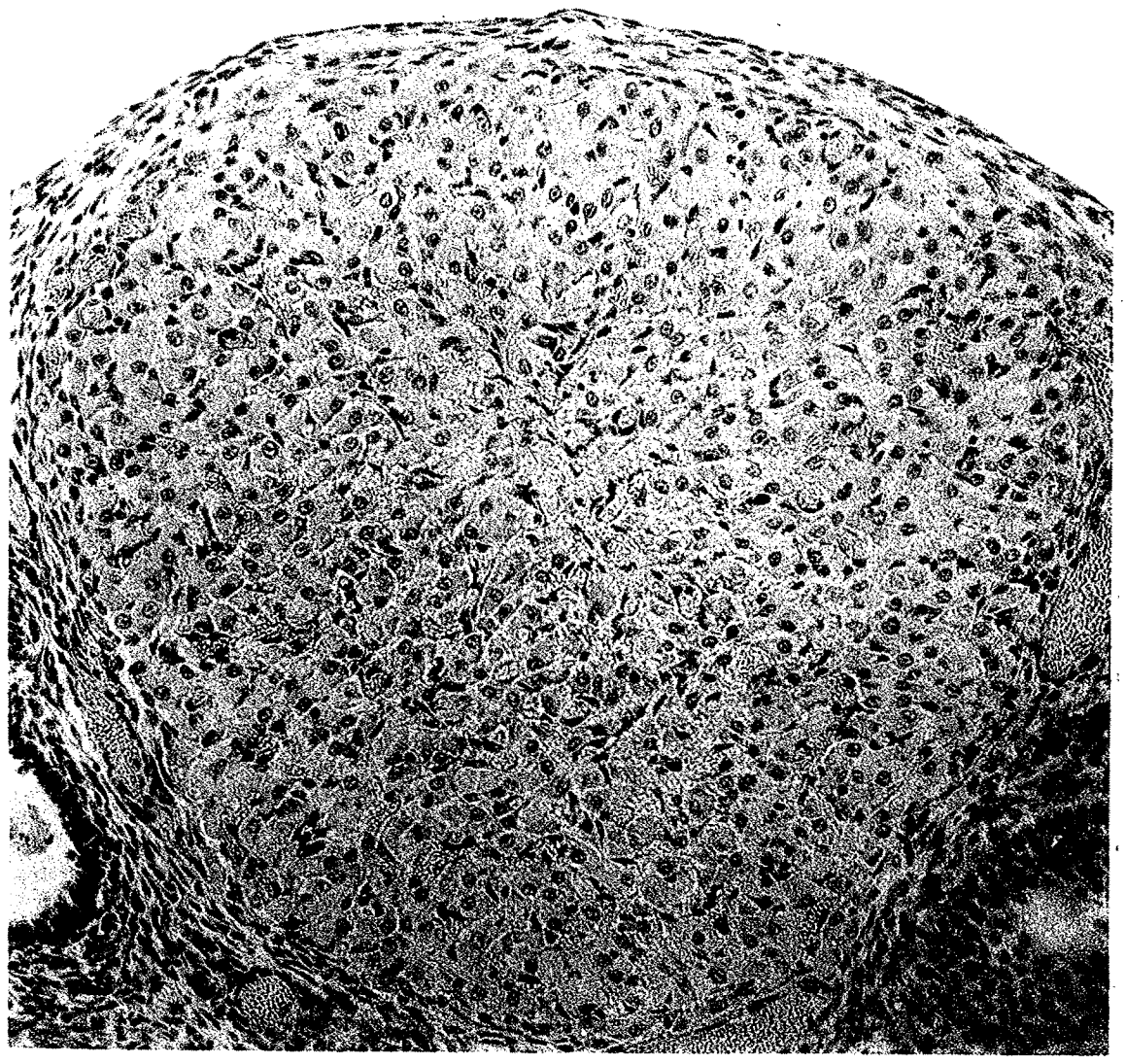

17

19

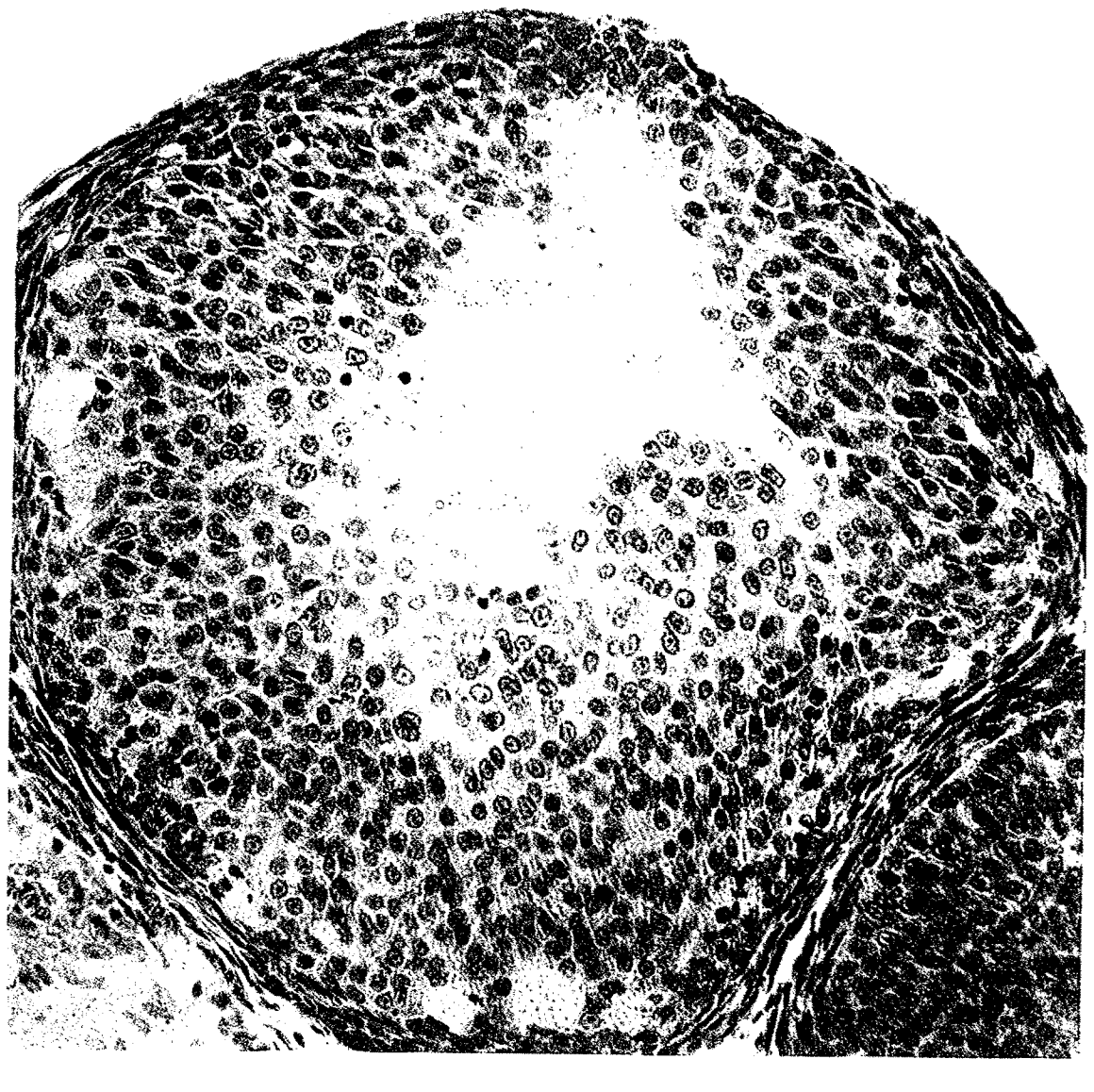

16

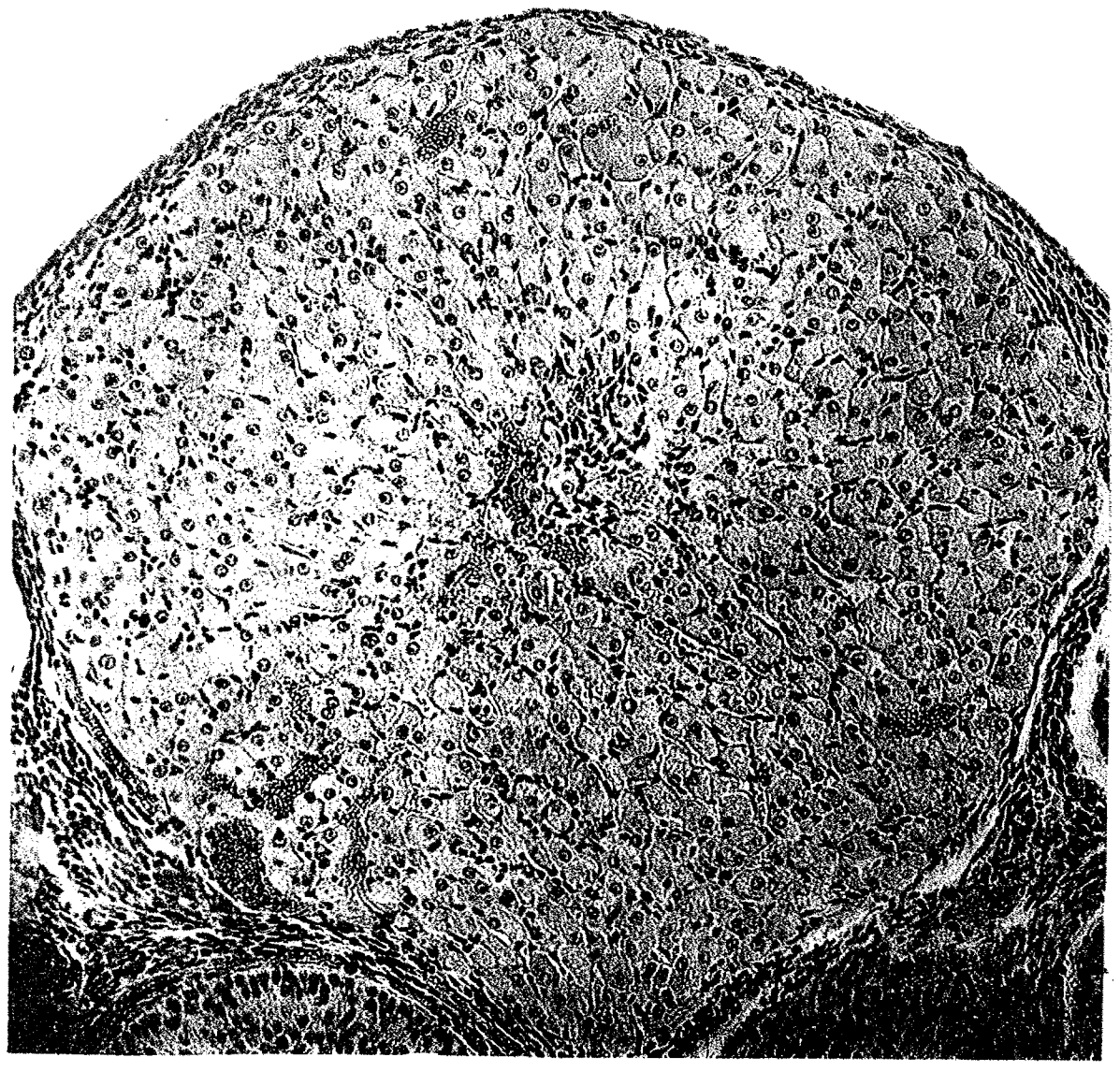

18

PLATE 3

FIG. 21—Photomicrograph of a transverse section of an immature uterus (S. 78) showing the absence of blood vessels with hyaline walls and the presence of the characteristic zone (*FZ*) between the mucosa and the muscularis. The uterine glands (*UG*) are small. × 104.

FIG. 22—Photomicrograph of a transverse section of the uterus during first œstrus (S. 911) showing the same features as fig. 21 but the mucosa and the muscularis are enlarged and both secretion and sperms are present in the lumen. The fibrous connective tissue zone (*FZ*) is shown. × 69.

FIG. 23—Photomicrograph of a transverse section of the uterus of a non-parous shrew immediately after ovulation (S. 879). It has enlarged still further and the uterine glands have extended. The fibrous zone (*FZ*) is very plain. × 53.

FIG. 24—Photomicrograph of a transverse section of the uterus of a non-parous shrew with 8-cell stages in the Fallopian tubes (S. 940). The glands (*UG*) are enlarged and have extended laterally. The uterine epithelium has become thicker. *FZ* = fibrous connective tissue zone. × 66.

FIG. 25—Photomicrograph of a transverse section of the uterus at a stage (S. 943) with early uterine blastocysts, one of which is shown. The uterine epithelium has become very thick and the glands are much enlarged and have extended considerably. × 60.

FIG. 26—Photomicrograph of a transverse section of the uterus (S. 1143) showing a late blastocyst (*BL*) in a spherical chamber (*SC*) becoming attached to the uterine wall. The uterine wall has become stretched and thin on the anti-mesometrial side and the uterine glands (*UG*) have extended round the sides. × 36.

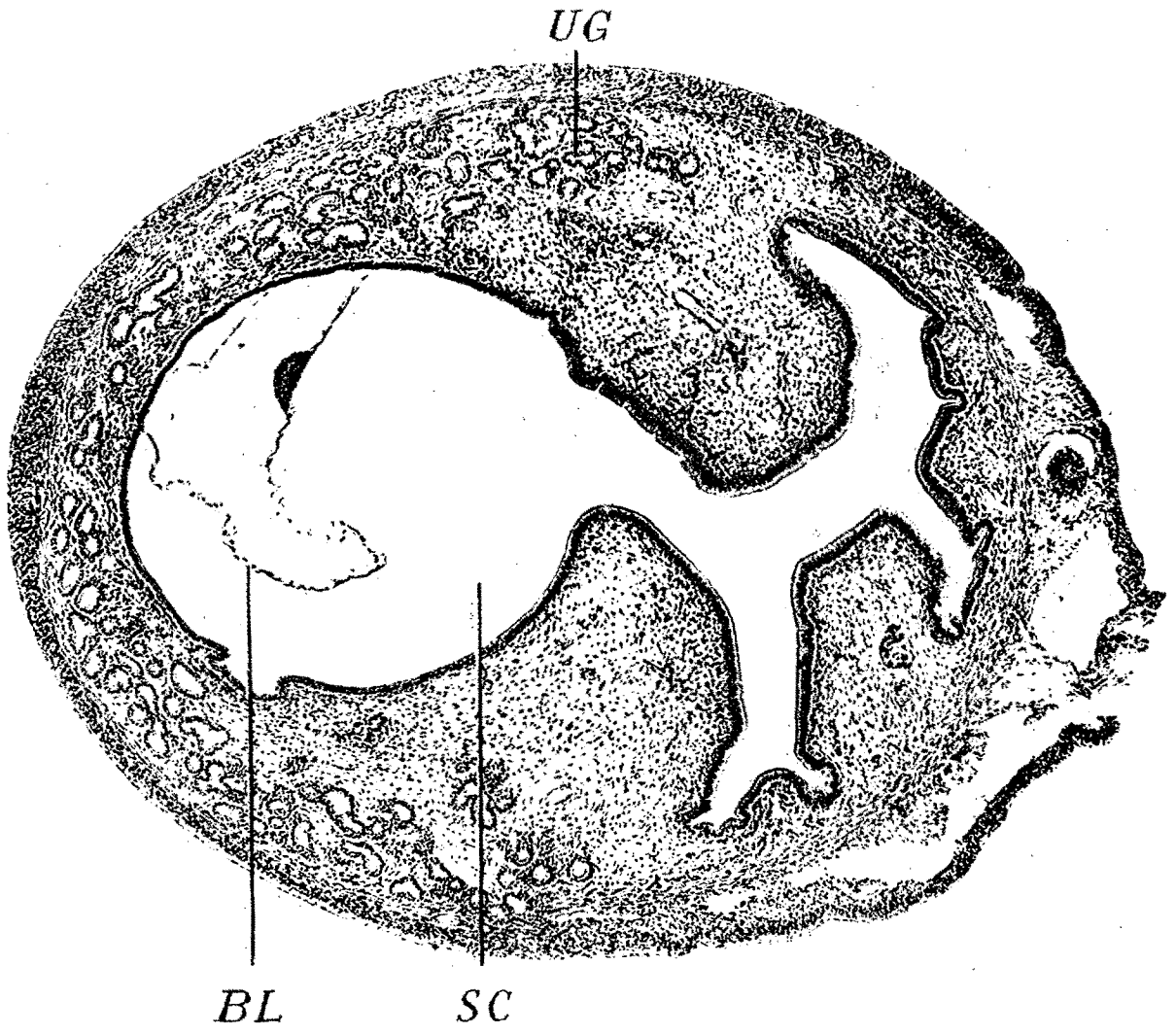

26

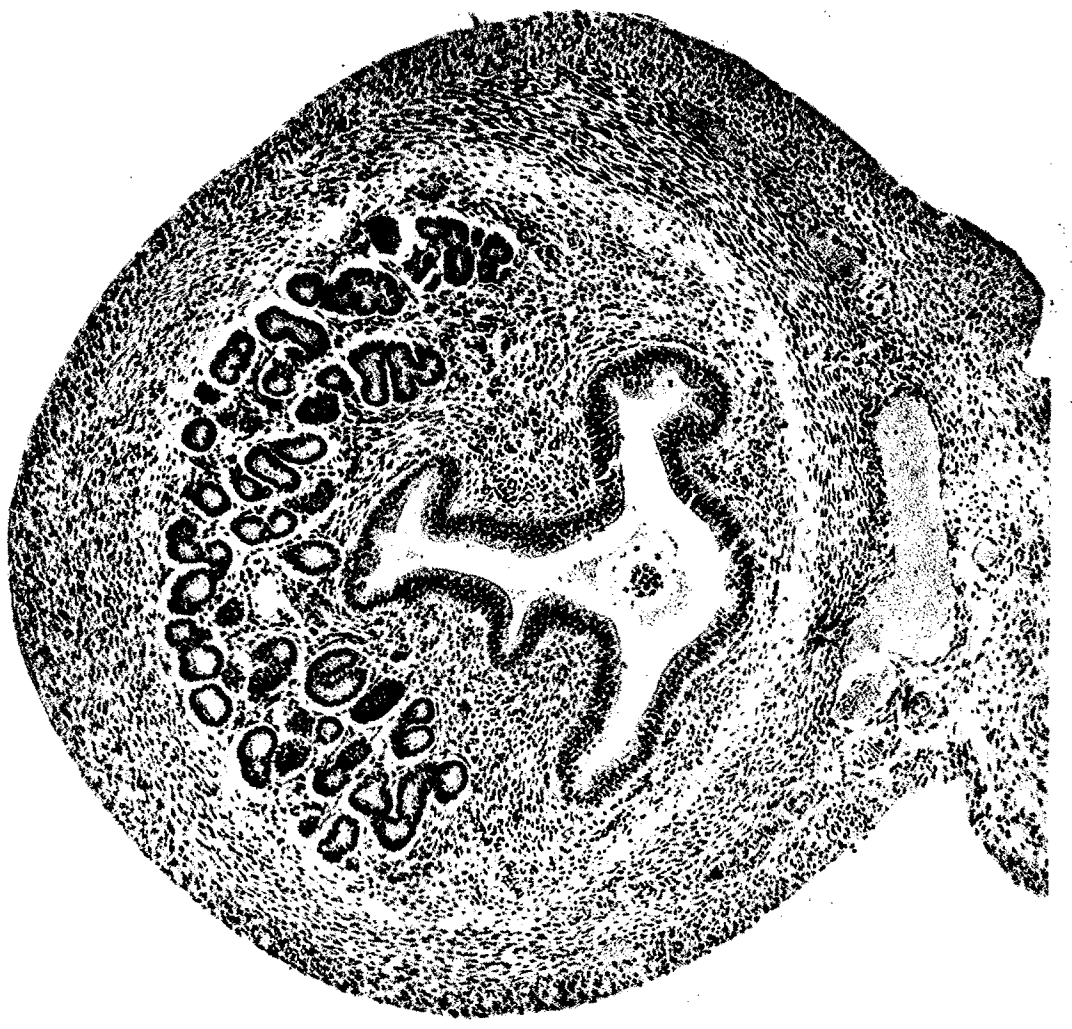

25

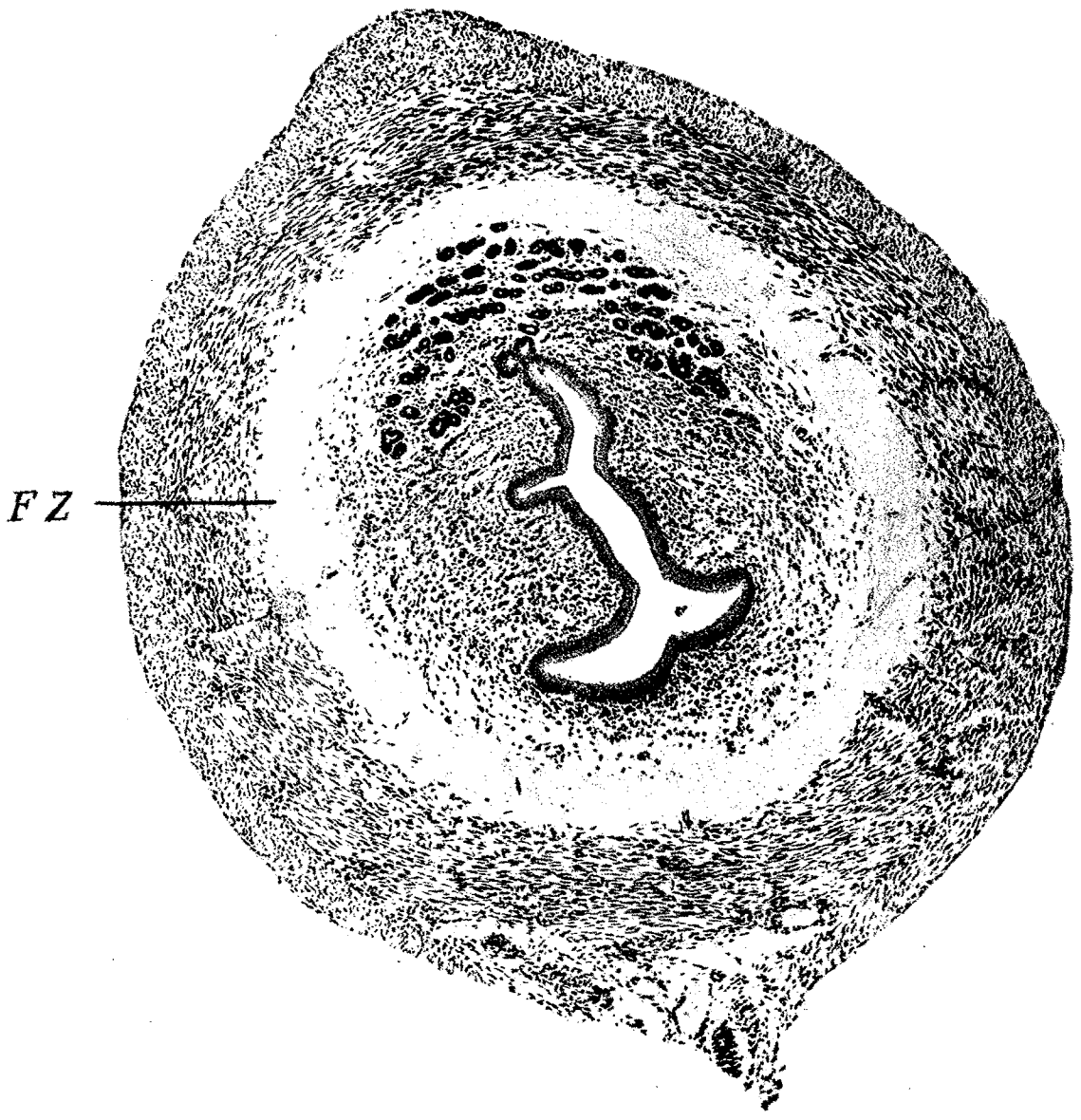

23

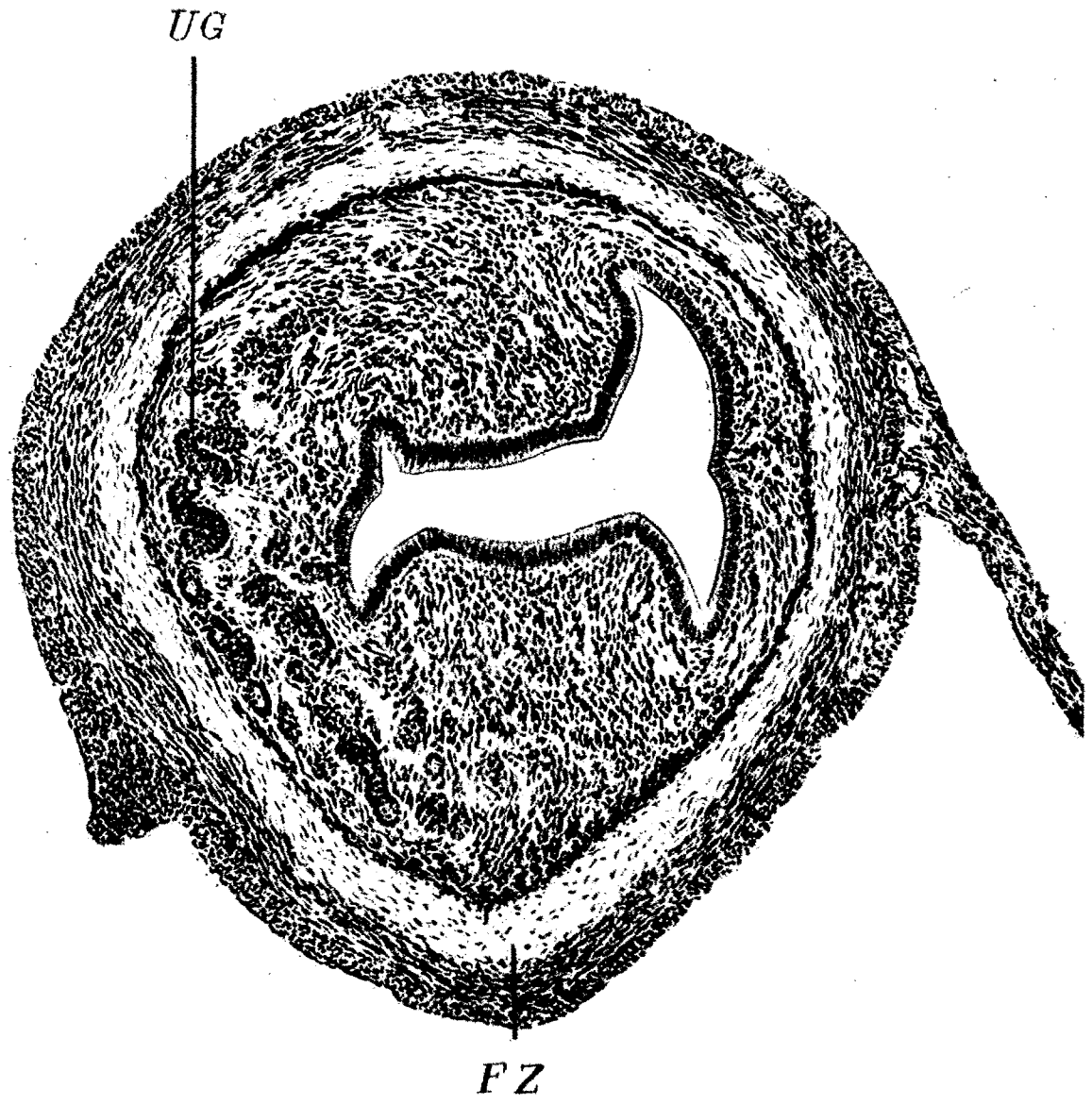

21

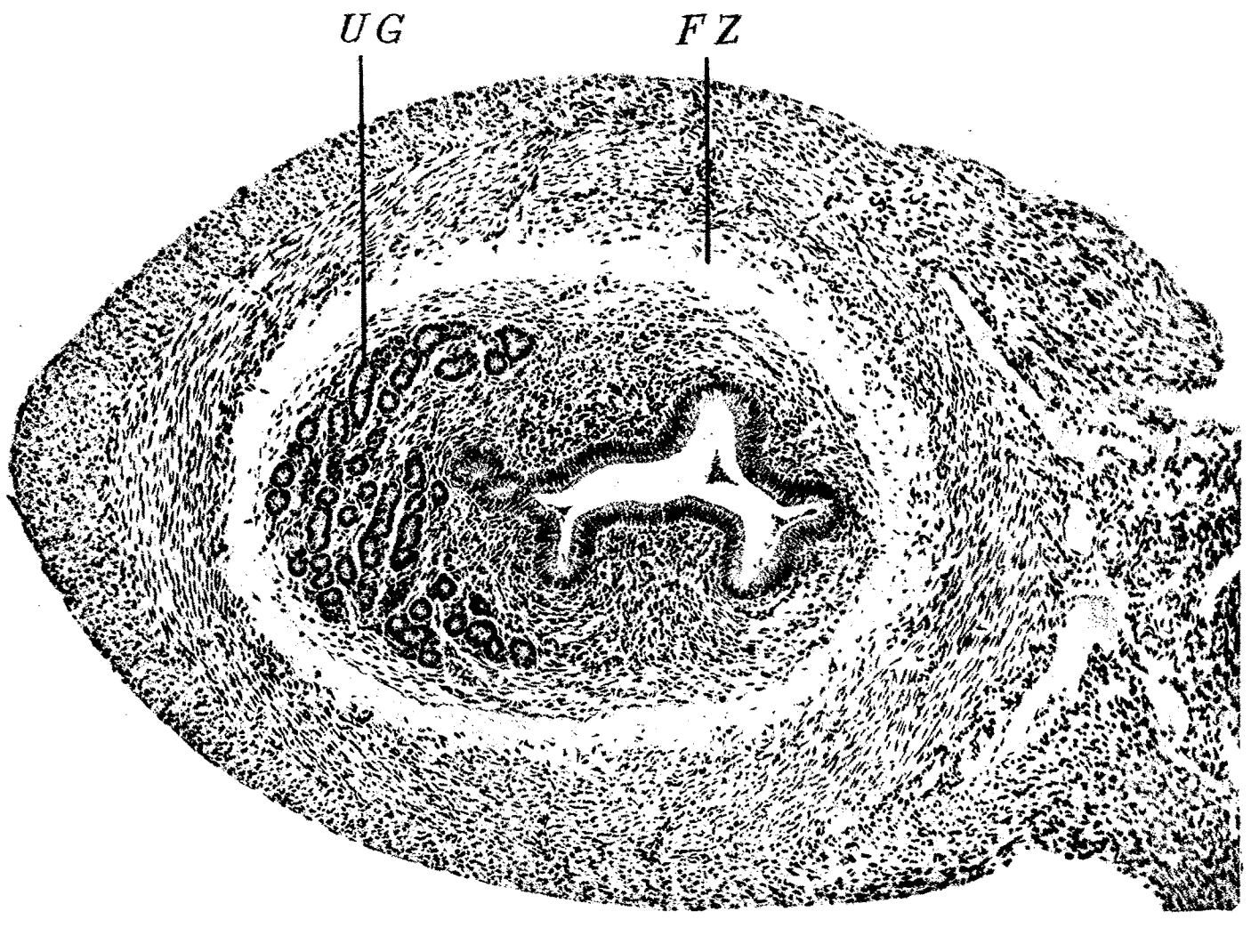

24

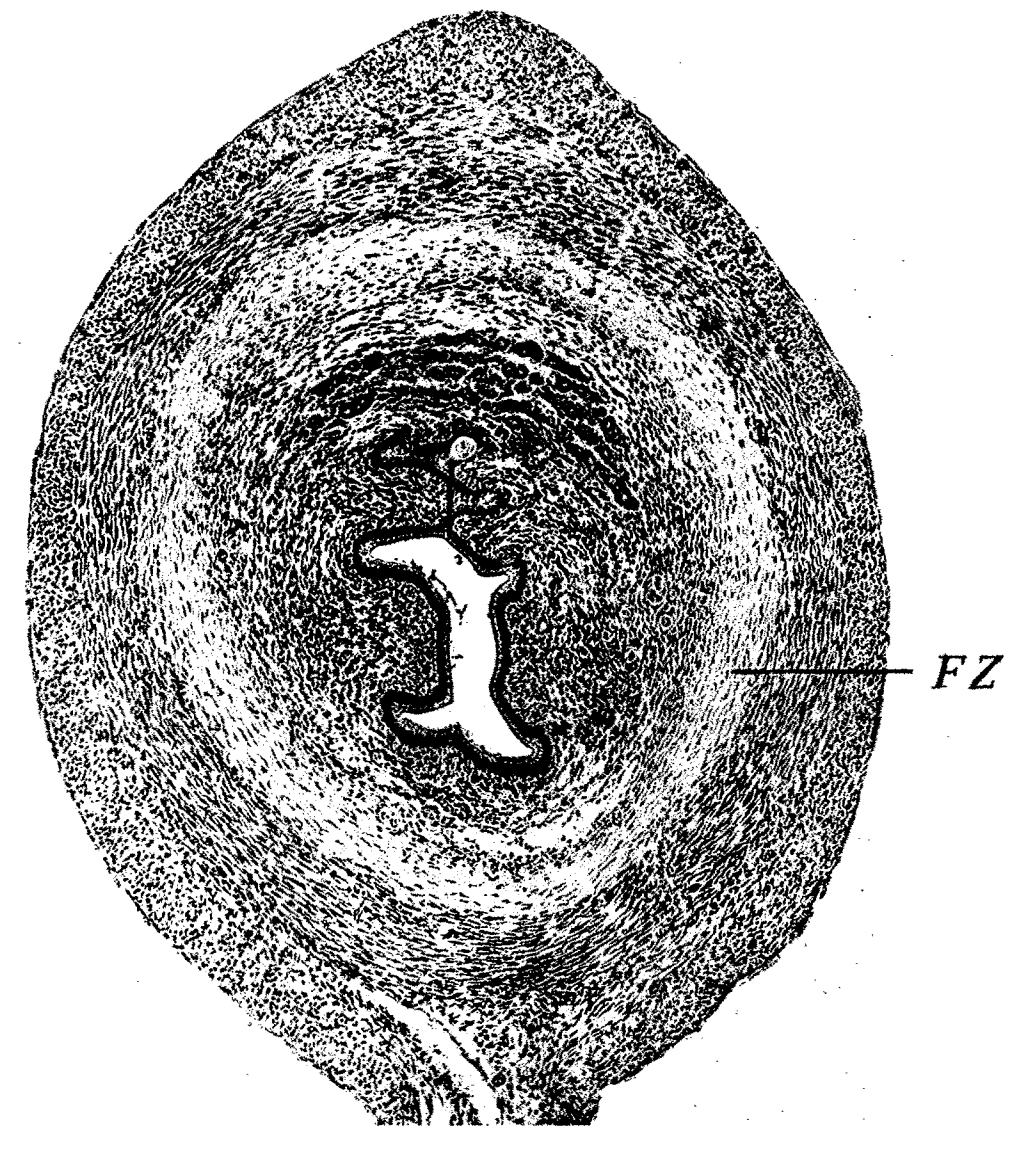

22

PLATE 4

FIG. 27—Photomicrograph of a part of the uterine epithelium (*UE*) of S. 940 shown in fig. 24. Leucocytes (*L*) are numerous in the mucosa and lumen. The epithelium is columnar with elongated nuclei arranged in a single row in the cells at the ends away from the lumen. × 234.

FIG. 28—Photomicrograph of a part of the uterine epithelium of a stage (S. 947) with blastocysts in the Fallopian tubes. The epithelium has changed completely in appearance owing to rearrangement of the nuclei in several rows in the cells. Leucocytes are very scarce in the mucosa. × 234.

FIG. 29—Photomicrograph of a transverse section of a parous uterus (S. 983) through a placental site (*PS*) which has not yet healed. The whole uterus is enlarged and intensely hyperæmic. The fibrous zone between the mucosa and muscularis found in non-parous uteri has entirely disappeared. Ova in the 4-cell stage are present in the Fallopian tubes. × 32.

FIG. 30—Photomicrograph of a transverse section of a parous uterus (S. 1047) through a placental site (*PS*). The mucosa has healed completely over the placental site although the ova of the post-partum œstrus are blastocysts still in the Fallopian tubes. The uterine glands (*UG*) are reforming and the hyperæmia has subsided. The blood vessels have the thick hyaline walls characteristic of œstrus. × 57.

FIG. 31—Photomicrograph of a transverse section of the uterus during lactation anœstrus (S. 200). × 78.

FIG. 32—Photomicrograph of a transverse section of the uterus during winter anœstrus (S. 646, February). The thick hyaline walls of the blood vessels (*HB*) and the absence of the characteristic zone of fibrous tissue between the mucosa and muscularis show that it is parous. The condition of the glands (*UG*) and uterine epithelium and its small size show that it is completely inactive. × 100.

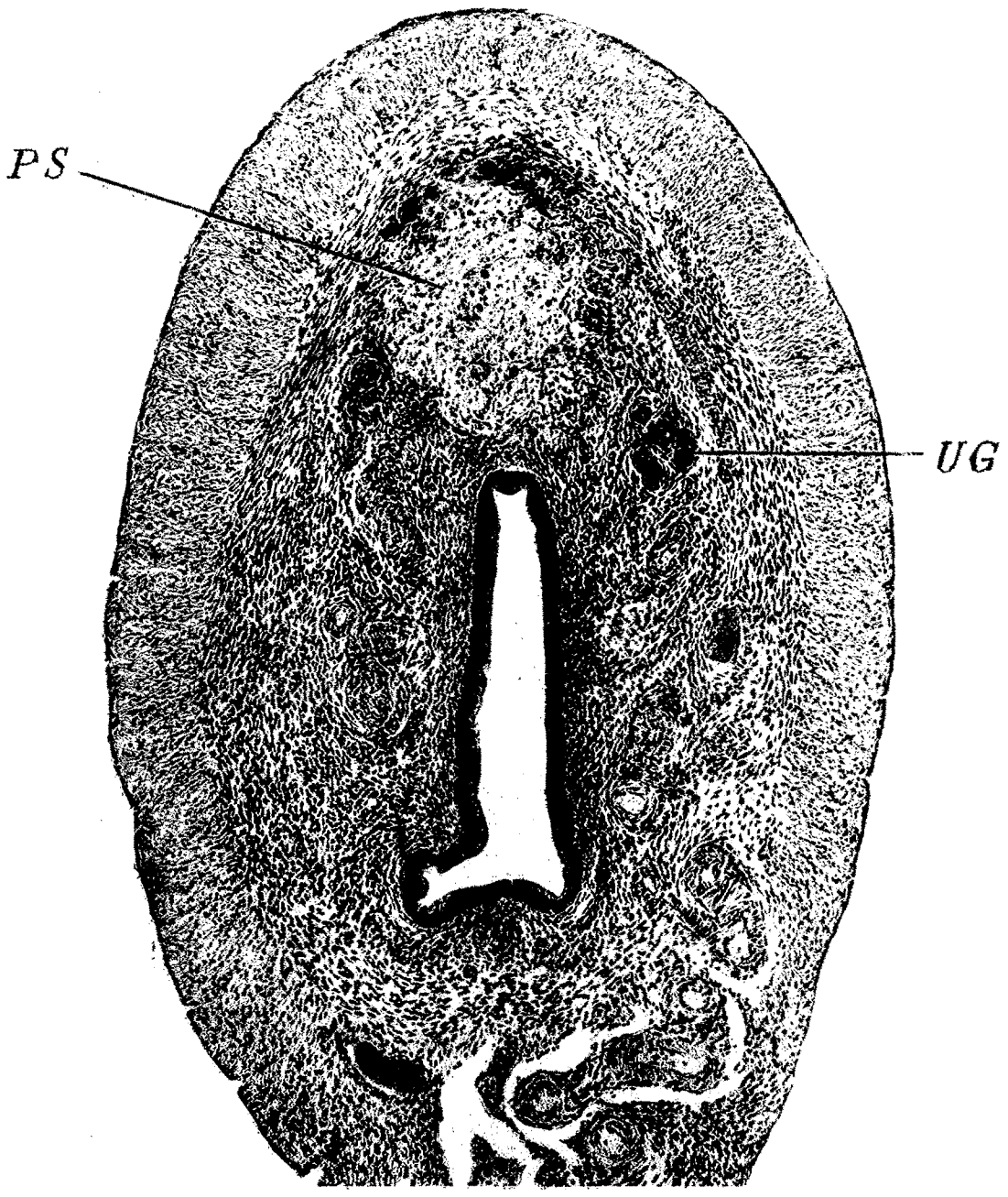

30

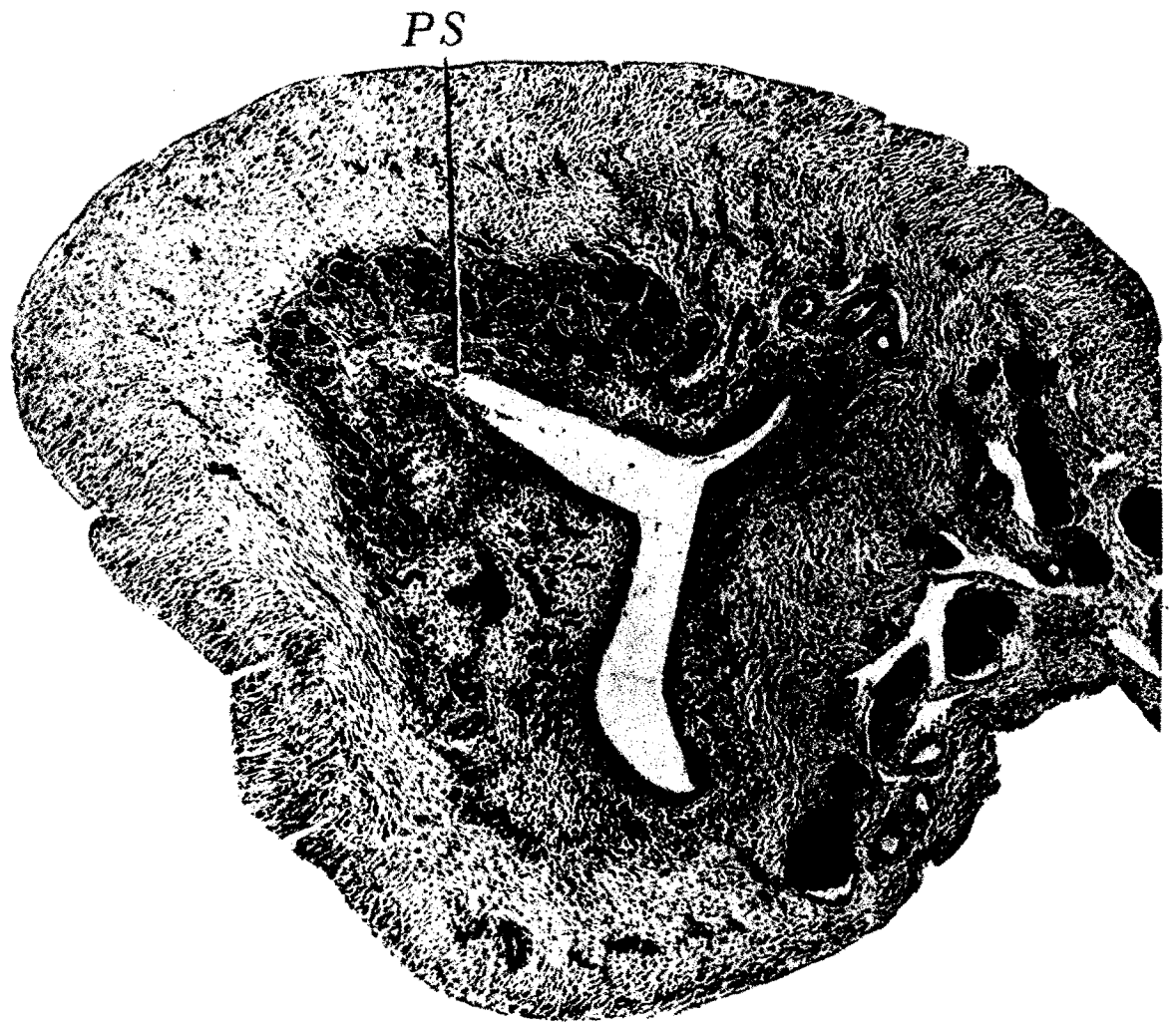

29

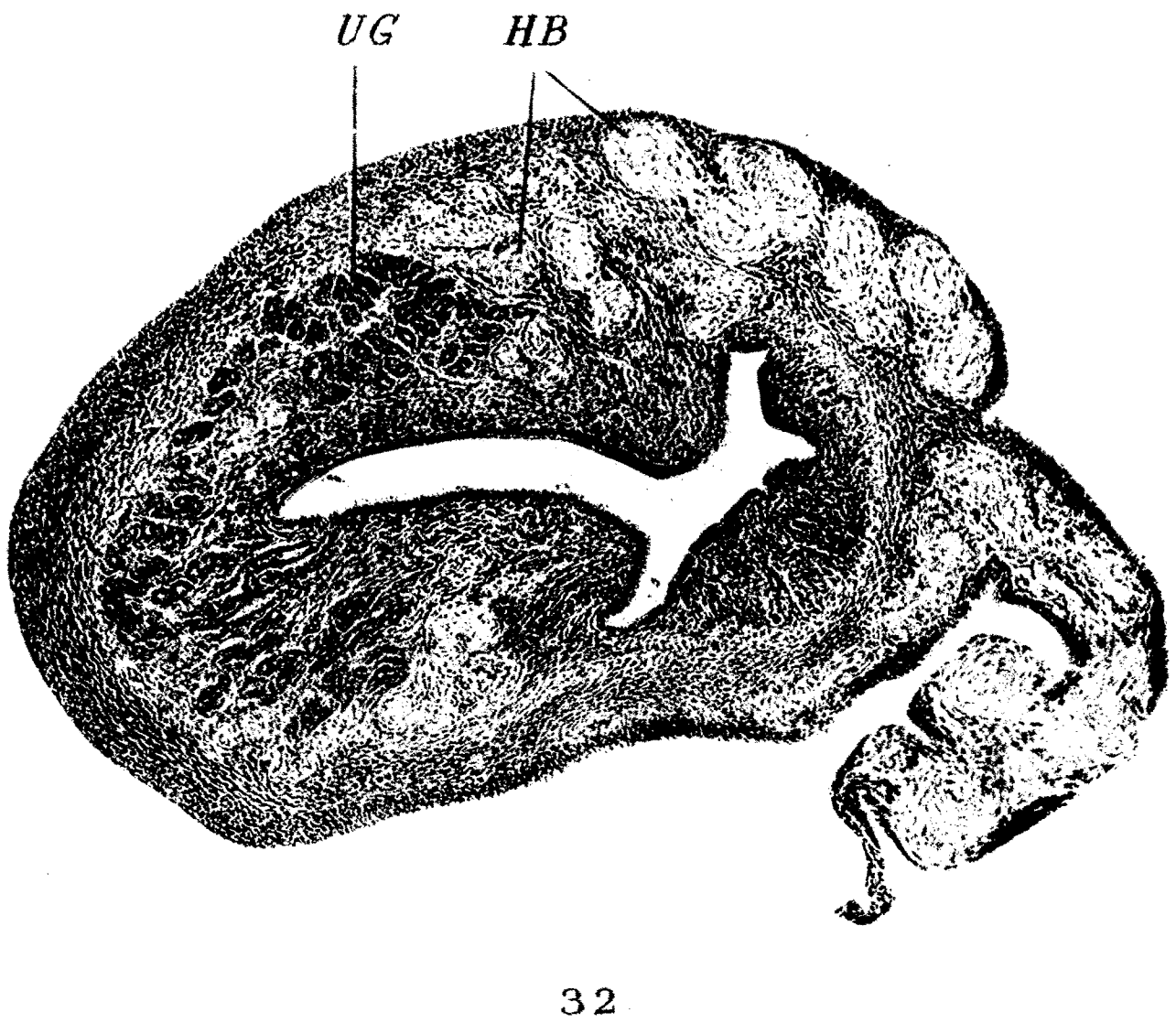

32

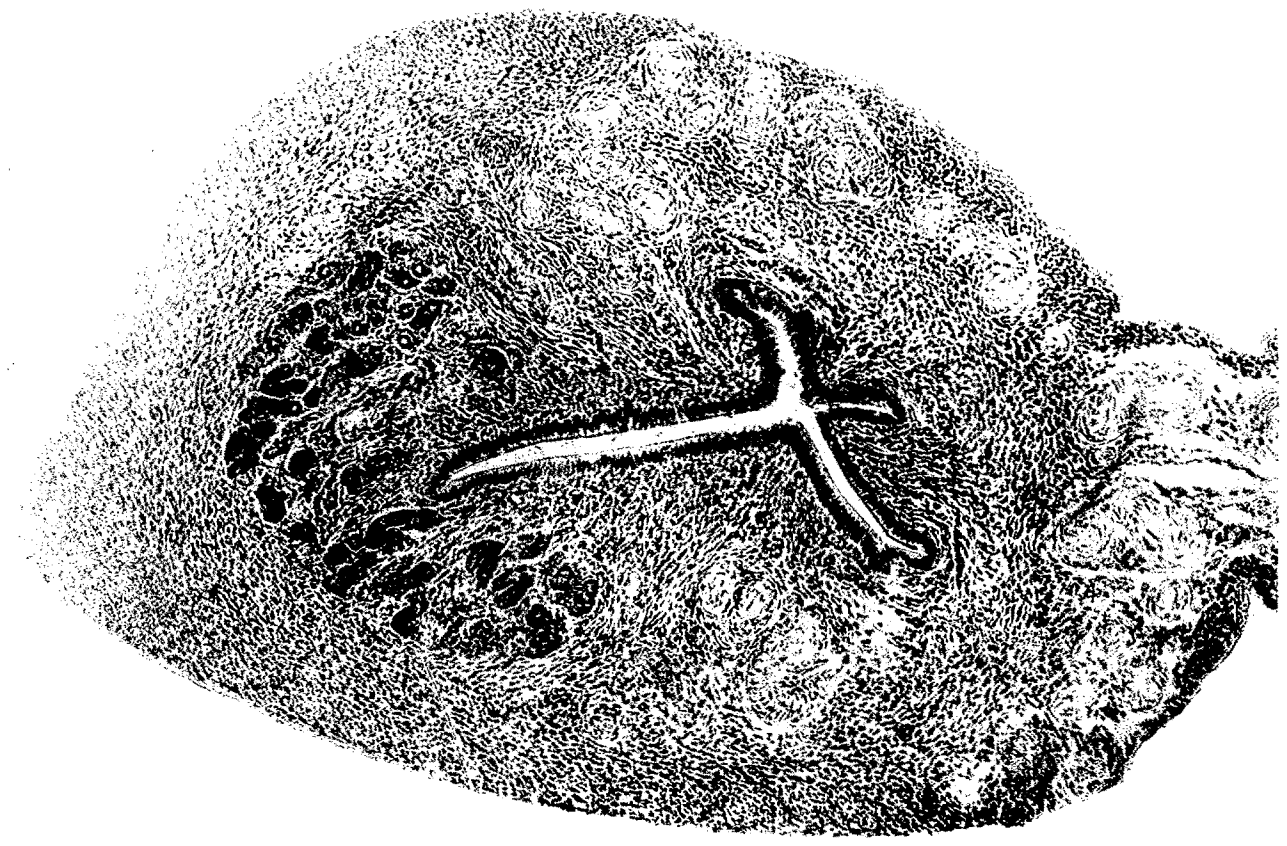

31

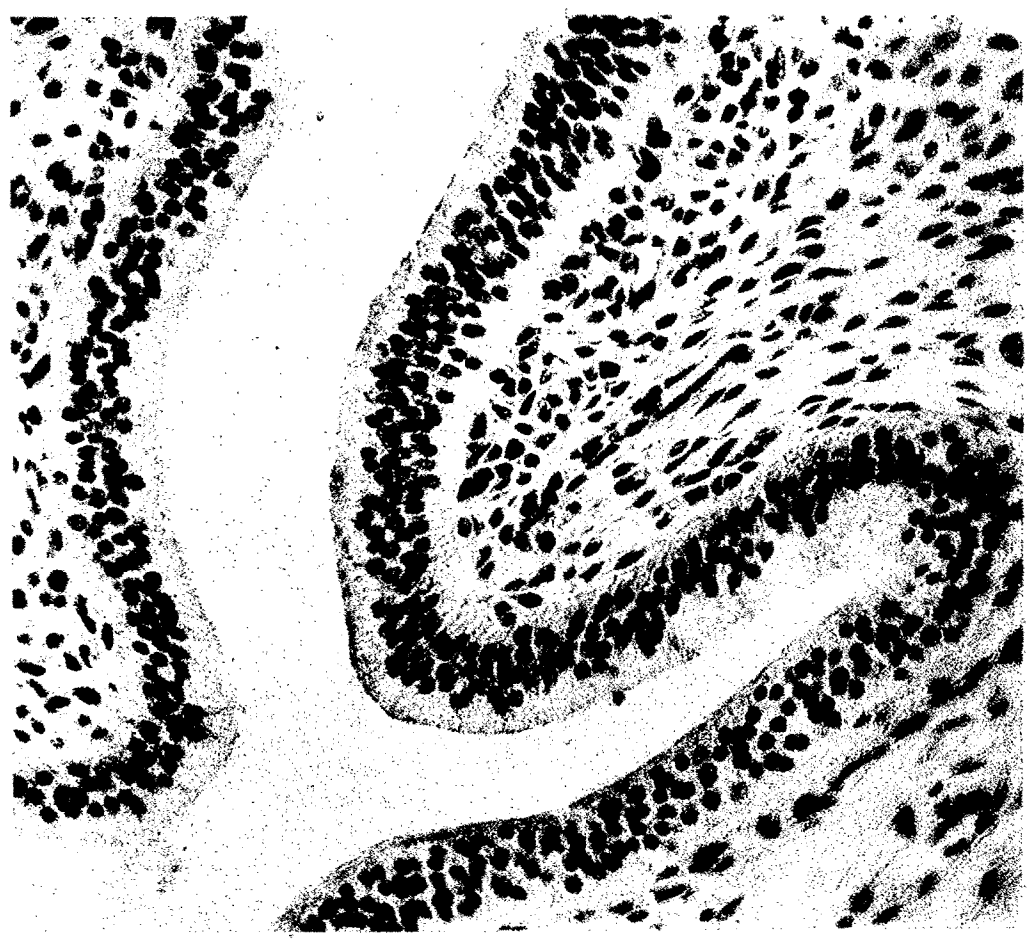

28

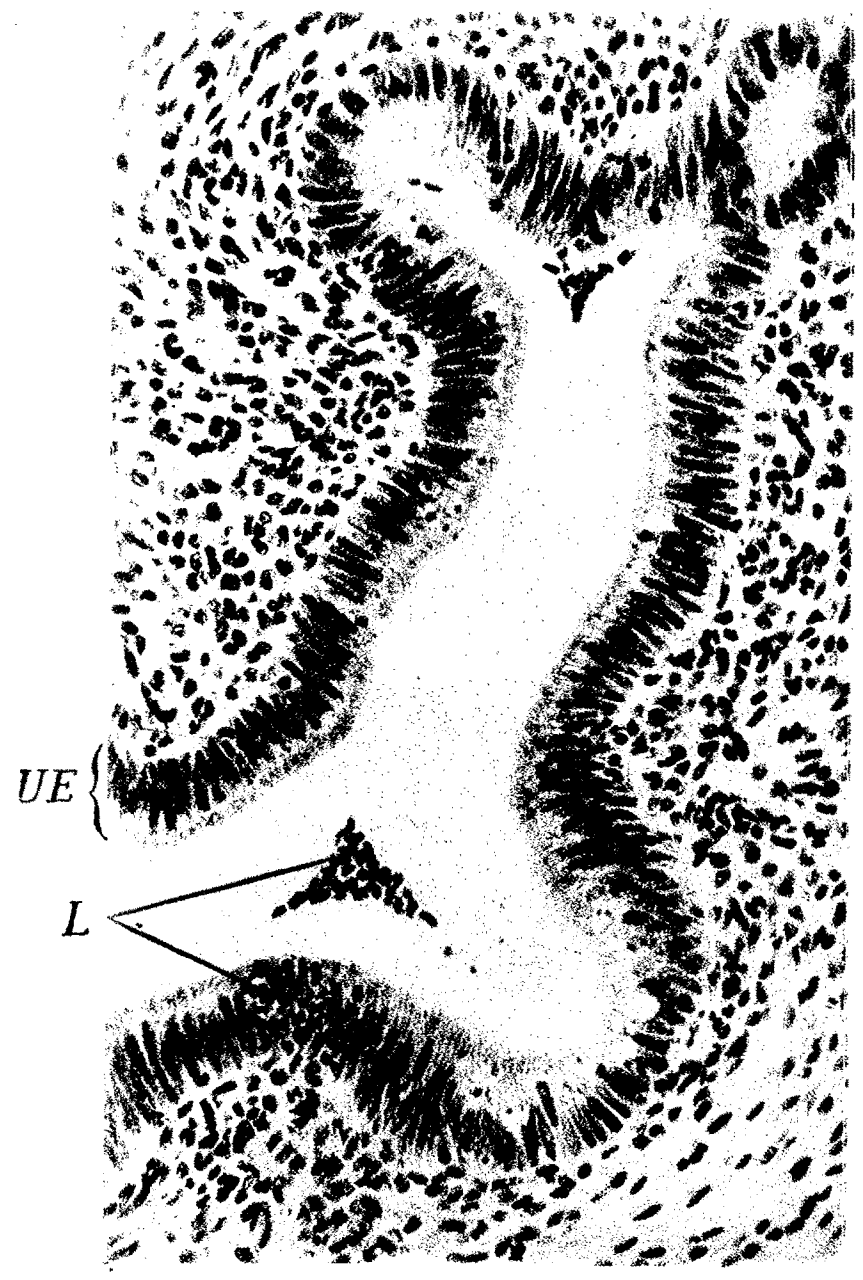

27

PLATE 5

FIG. 33—Photomicrograph of a transverse section of the uterine part of the Fallopian tube of an immature animal (S. 78). × 180.

FIG. 34—Photomicrograph of a transverse section of the uterine part of the Fallopian tube during post-partum œstrus (S. 1033). × 180.

FIG. 35—Photomicrograph of a transverse section of the uterine part of the Fallopian tube of a pregnant animal (S. 983) showing a 4-cell stage in the lumen. × 140.

FIG. 36—Photomicrograph of a transverse section of the uterine part of the Fallopian tube of a parous animal (S. 559) during anœstrus. × 180.

FIG. 37—Photomicrograph of a section of the ovarian part of the Fallopian tube of an immature animal (S. 78). × 152.

FIG. 38—Photomicrograph of a section of the ovarian part of the Fallopian tube during the first œstrus (S. 880). × 112.

FIG. 39—Photomicrograph of a mature follicle in a post-partum œstrous ovary (S. 1033). The ovum contains a 1st polar spindle. The arrangement of the cells of the membrana granulosa and the small size of the antrum can be seen. The intense hyperæmia of the thecal blood vessels is characteristic. × 240.


35


33

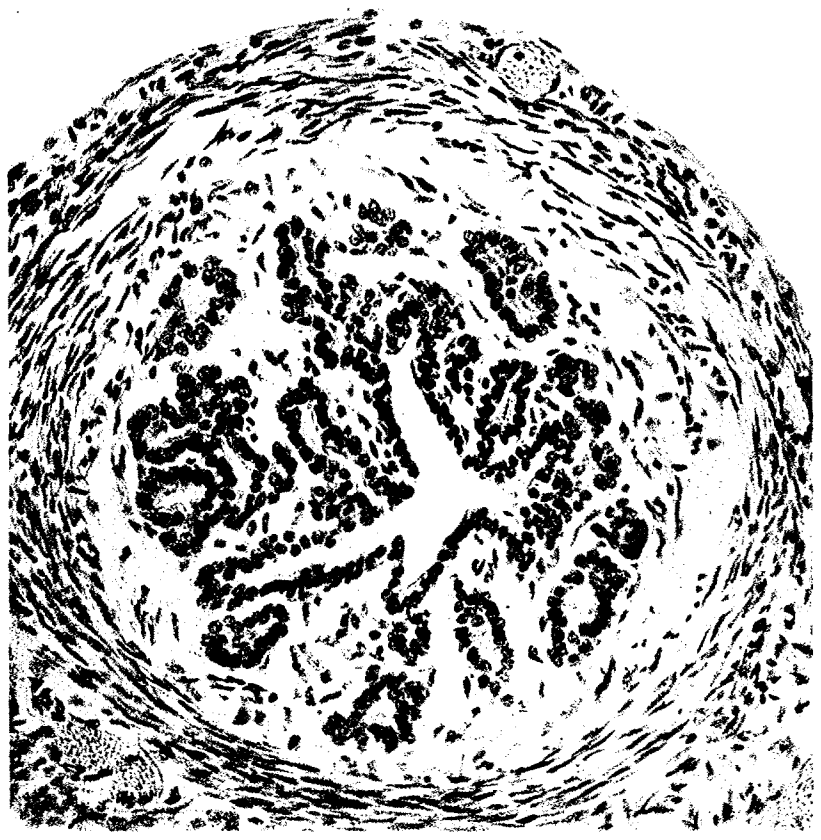
34


37

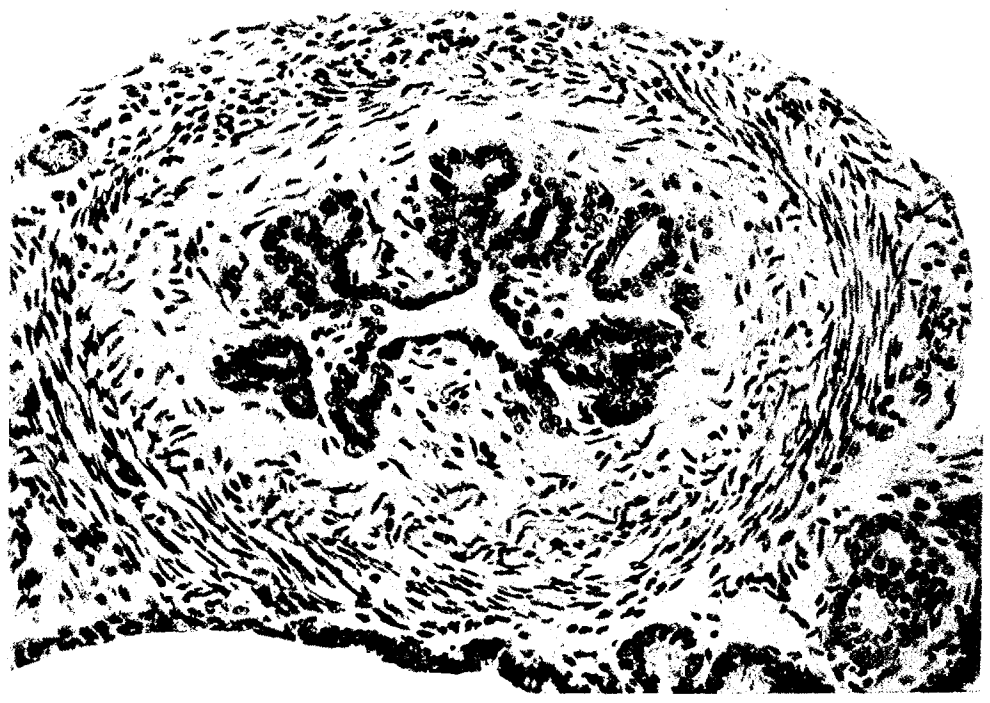
36

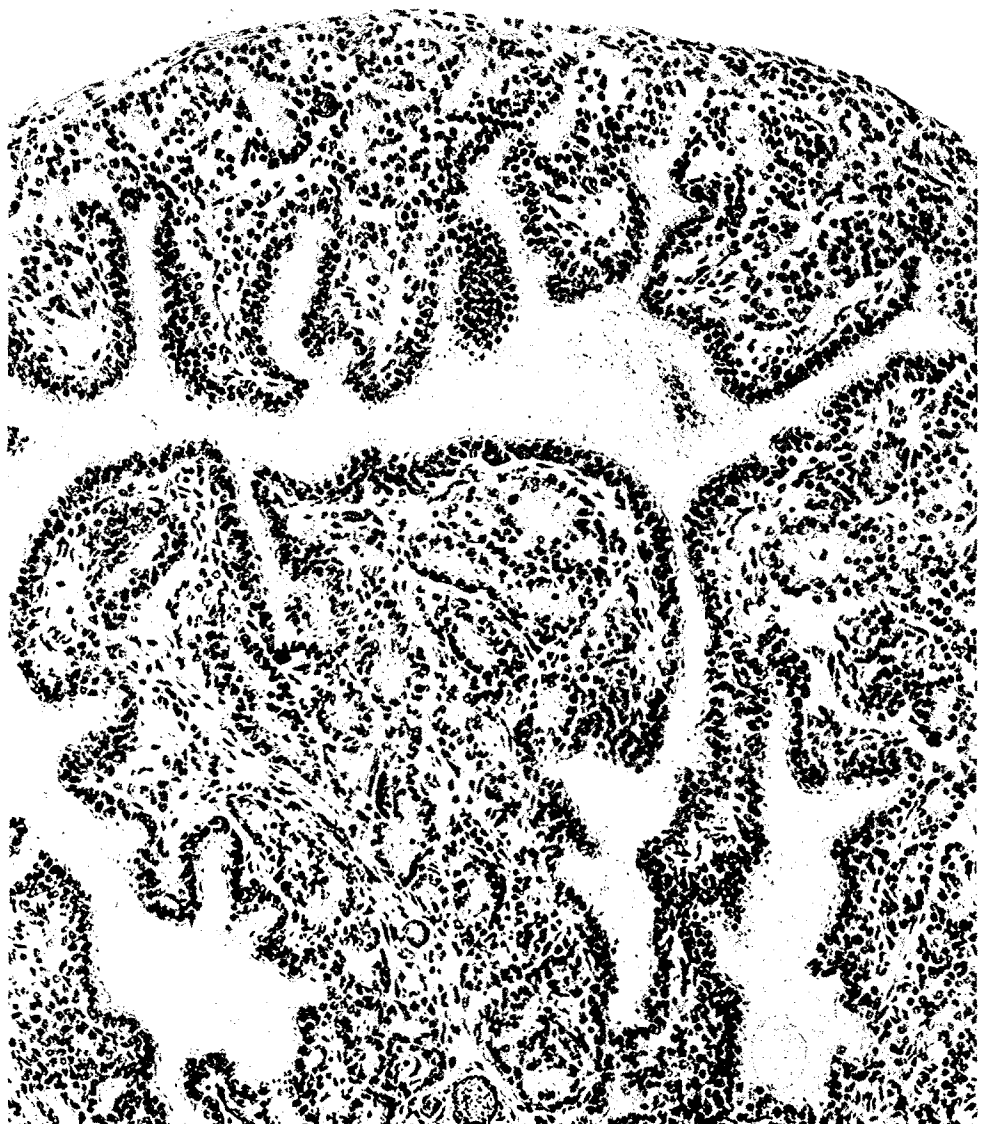
38

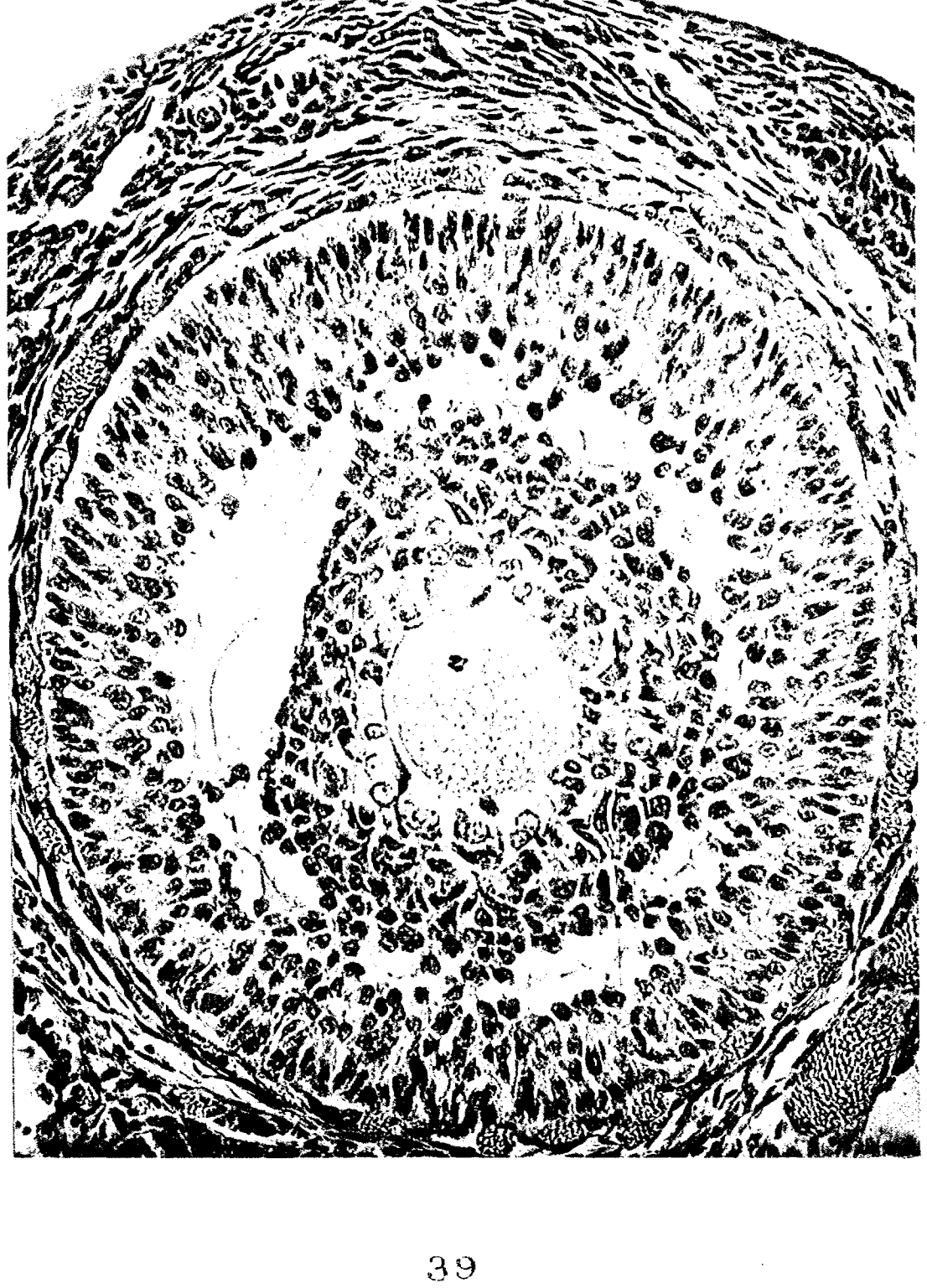
39

PLATE 6

FIG. 40—Photomicrograph of a transverse section of the upper part of the vagina of an immature animal (S. 170) showing the stratified nucleated epithelium and the wide zone of fibrous connective tissue (*FZ*) between the mucosa and the muscularis. × 78.

FIG. 41—Photomicrograph of a transverse section of the lower part of the vagina anterior to the urethral orifice of an immature animal (S. 605). The epithelium is in the form of a solid branching strand (*ES*). × 115.

FIG. 42—Photomicrograph of a transverse section of the lower part of the vagina posterior to the urethral orifice of an immature animal (S. 216). × 50.

FIG. 43—Photomicrograph of a transverse section of the upper part of the vagina during first œstrus (S. 818) showing intense cornification of the epithelium, only the basal layers of which are nucleated. It is folded longitudinally. A mass of semen is present in the lumen. × 42.

FIG. 44—Photomicrograph of a transverse section of the lower region of the vagina during the first œstrus (S. 903) showing the epithelial cornification. × 50.

FIG. 45—Photomicrograph of a part of the vaginal epithelium during post-partum œstrus (S. 1030). A plug of semen is present in the lumen. × 120.

FIG. 46—Photomicrograph of a transverse section of the upper part of the vagina during mid-pregnancy (S. 1001) showing the complete occlusion of the lumen owing to fusion of the epithelial folds. × 57.

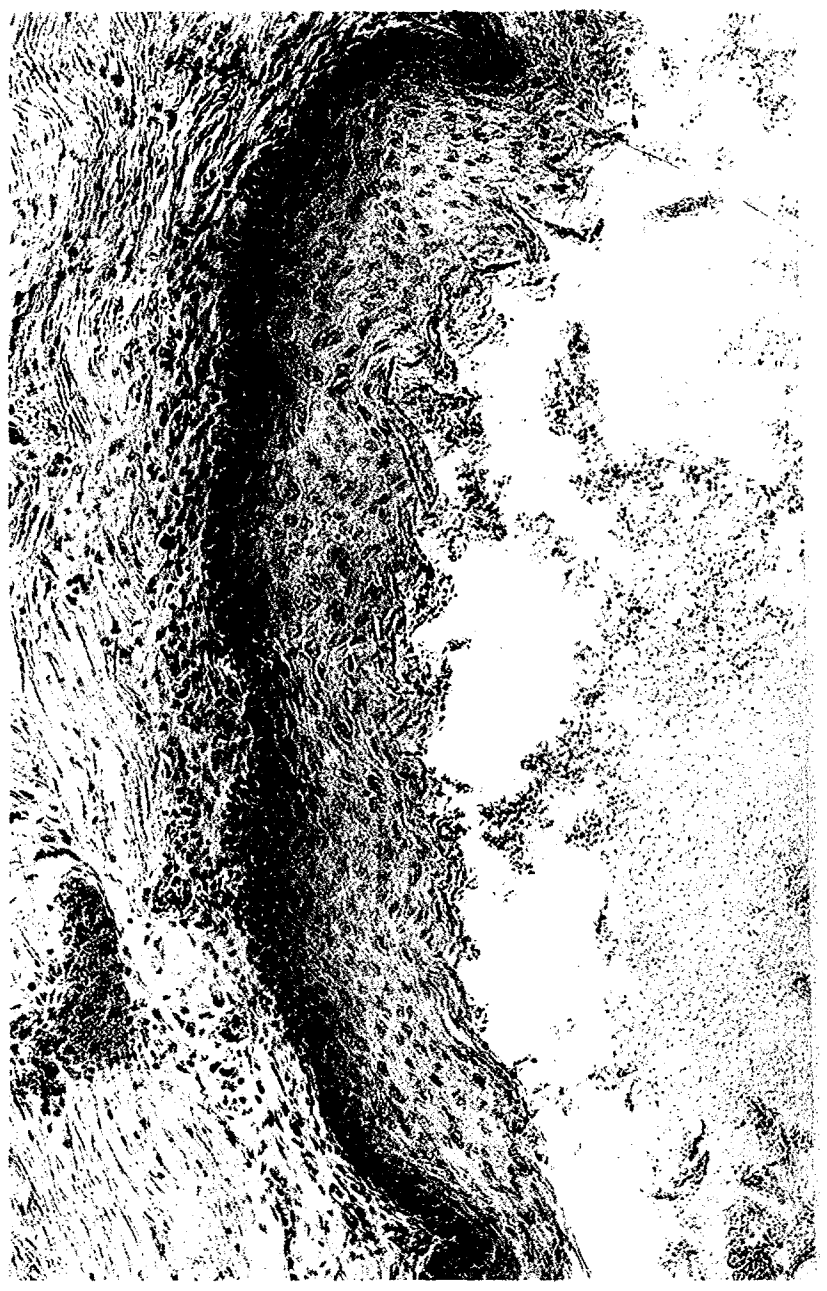

45

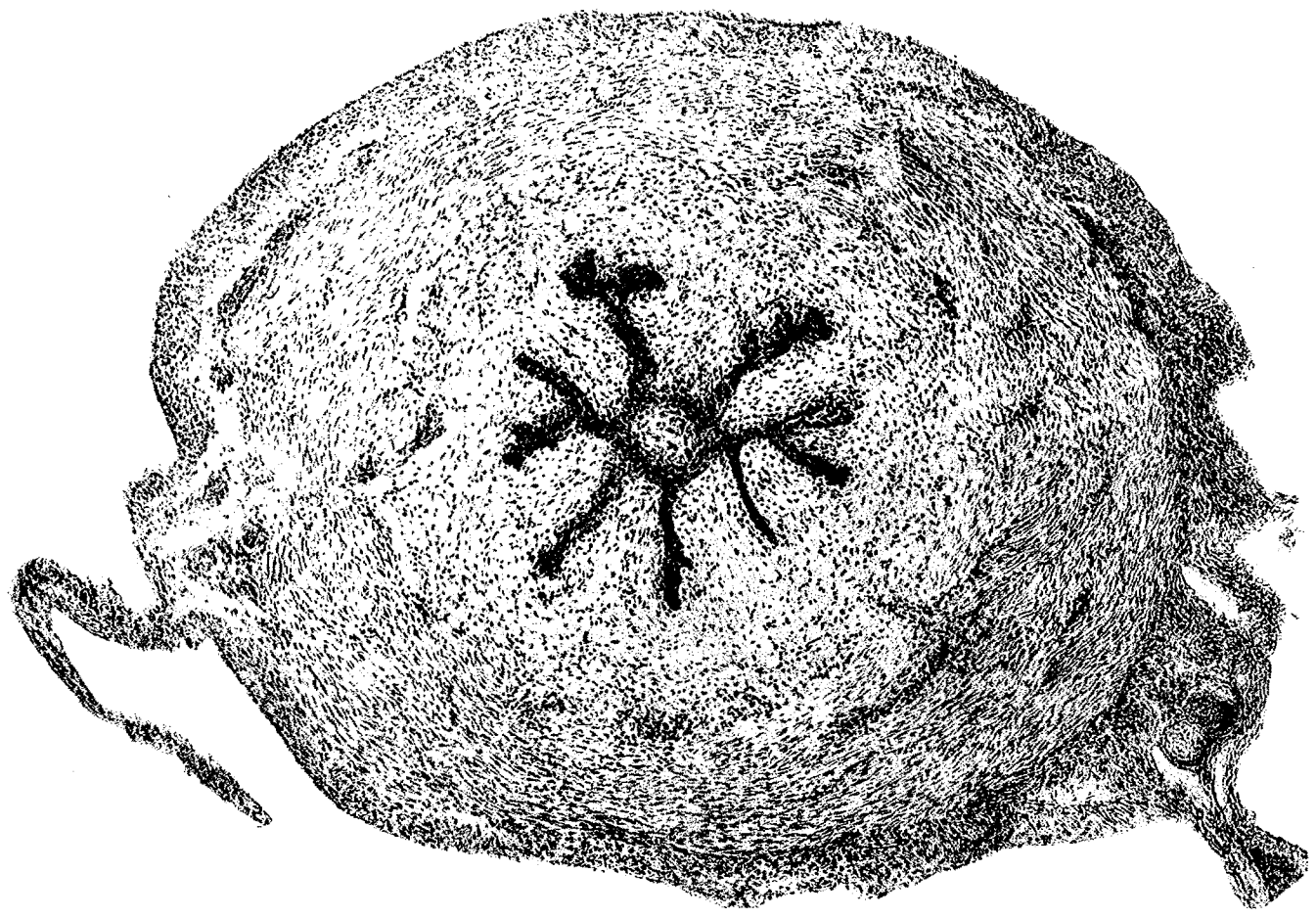

46

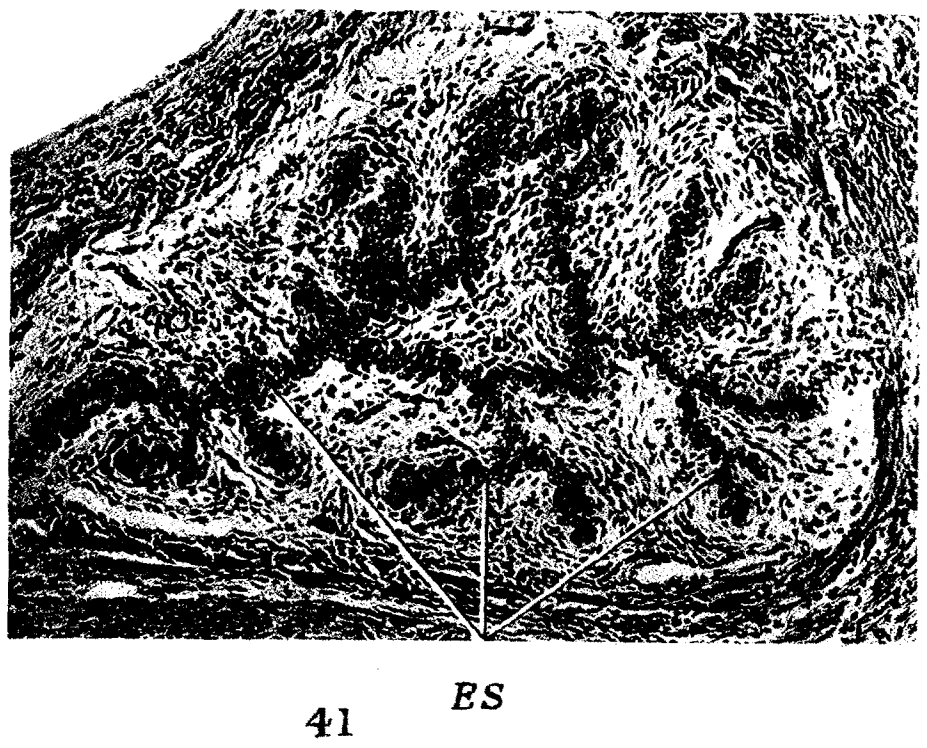

41

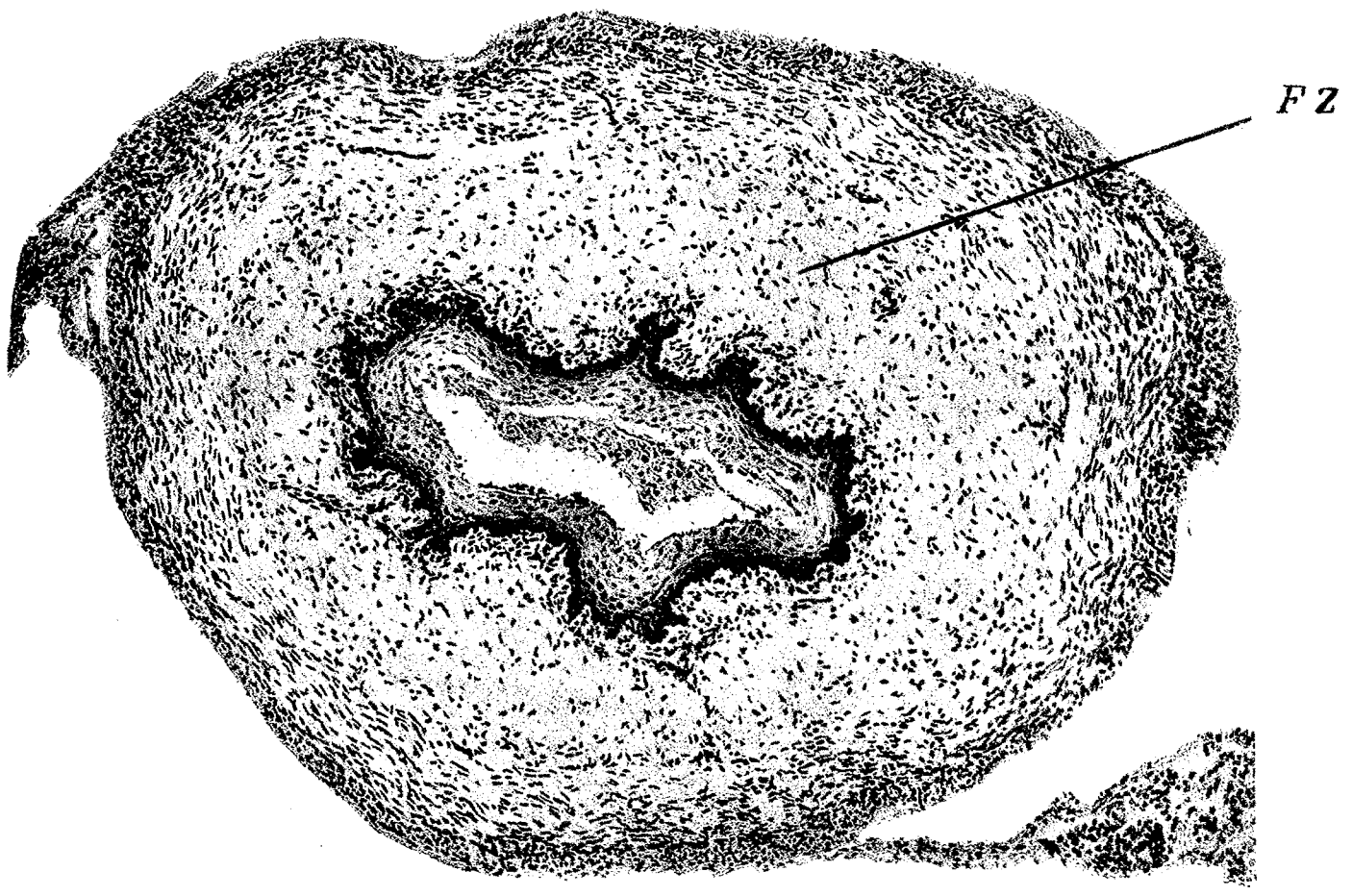

40

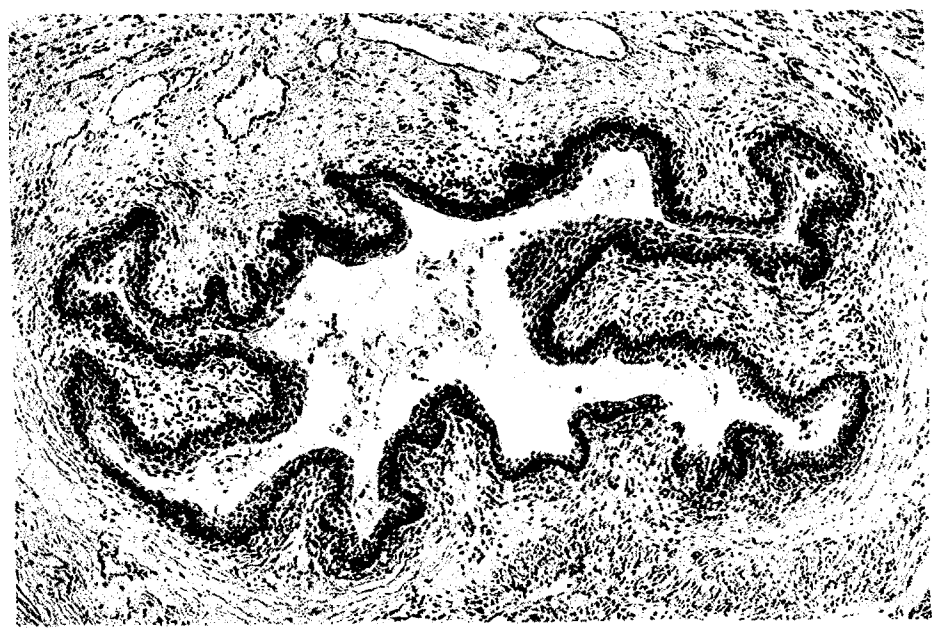

42



43



44

PLATE 7

FIG. 47—Photomicrograph of portion of the section shown in fig. 43 showing the cornified epithelium (*CE*), the nucleated epithelium (*NE*) and the semen (*S*) in the lumen. × 128.

FIG. 48—Photomicrograph of a portion of a transverse section of the upper part of the vagina shortly after ovulation (S. 879). The epithelial cornification is so intense that only small patches of nucleated epithelium (*NE*) remain in the basal layers in the valleys between the folds. The mucosa is intensely hyperæmic and extravasation (*EB*) has occurred. The epithelium is thin, owing to the amount which has been sloughed, and it is ruptured in one place (*R*). × 160.

FIG. 49—Photomicrograph of a part of the vagina of an animal during lactation (S. 1214) showing cornification and numerous leucocytes suggesting metœstrus. × 100.

FIG. 50—Photomicrograph of a part of a transverse section of the lower part of the vagina at the end of gestation (S. 949) showing the thick nucleated epithelium. × 100.

49

47

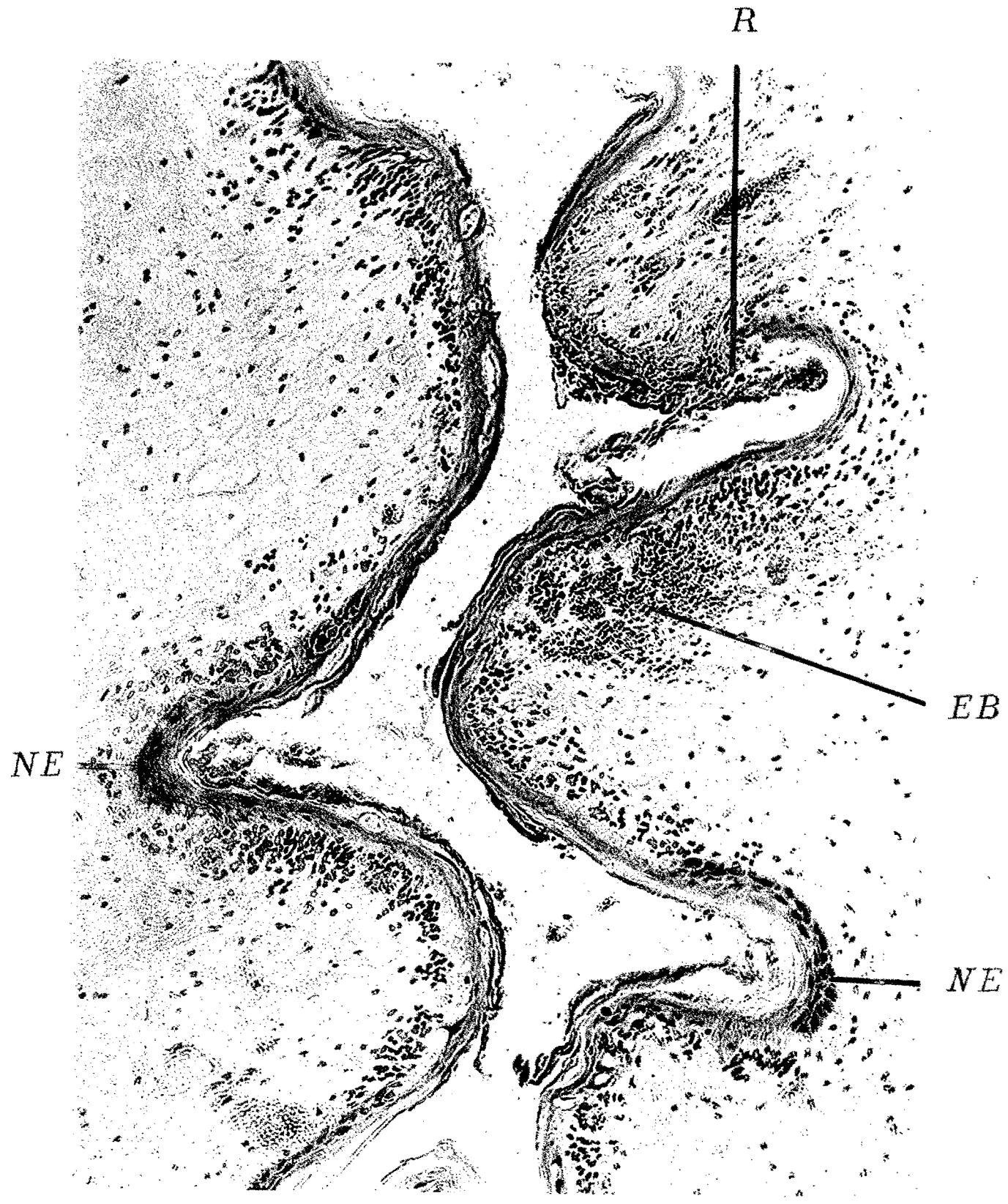

48

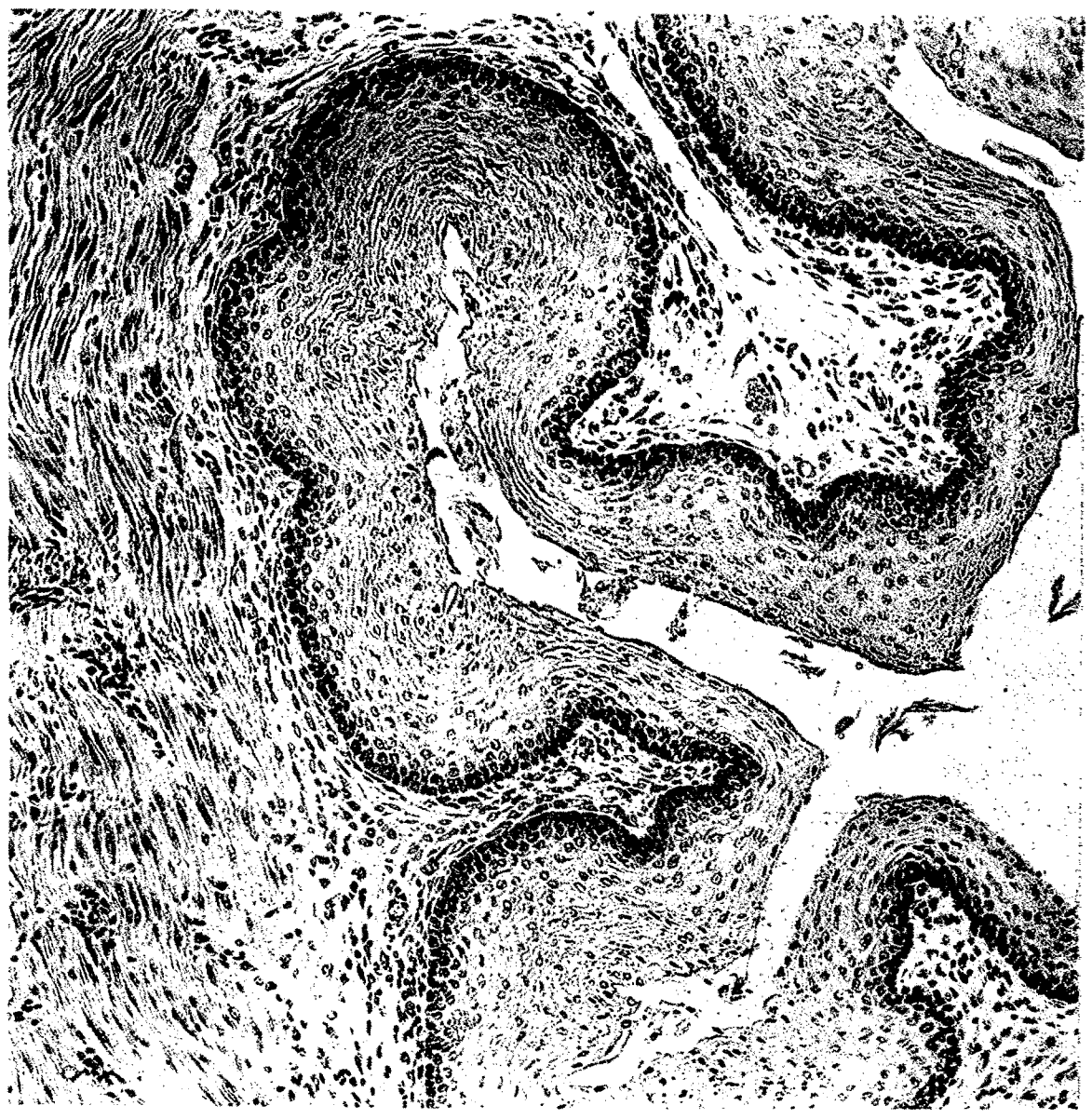

50

Plate 8

Fig. 51—Photomicrograph of a whole mount of the second mammary gland of a non-parous animal (S. 940) with 8-cell stages of the Fallopian tubes. The bulbous endings (*DB*) of the ducts can be seen. The ducts have only extended some 2 mm from the nipple (N^2). × 33.

Fig. 52—Photograph of a whole mount of the mammary glands of a non-parous animal (S. 989) during late pregnancy. The alveoli can be distinguished in the first pair of glands. × 1·8.

Fig. 53—Photograph of a whole mount of the mammary glands during the height of lactation (S. 1062). M^1 = anterior gland. M^2 = median gland. M^3 = posterior gland. N^1 = nipple of anterior gland. *LG* = lymphatic gland. × 1·9.

Fig. 54—Photograph of a whole mount of the mammary glands of a parous non-lactating shrew (S. 1159) during late pregnancy. The glands have retrogressed but can be distinguished from those of non-parous pregnant animals by their homogeneous appearance. × 1·7.

Fig. 55—Photomicrograph of the ovary of an immature shrew (S. 330) in November showing the pockets of primordial follicles in the cortex. All larger follicles have disappeared. × 147.

Fig. 56—Photomicrograph of the ovary during winter anœstrus (S. 646, February). The ovary is very small and there are very few follicles larger than primordial follicles. × 117.

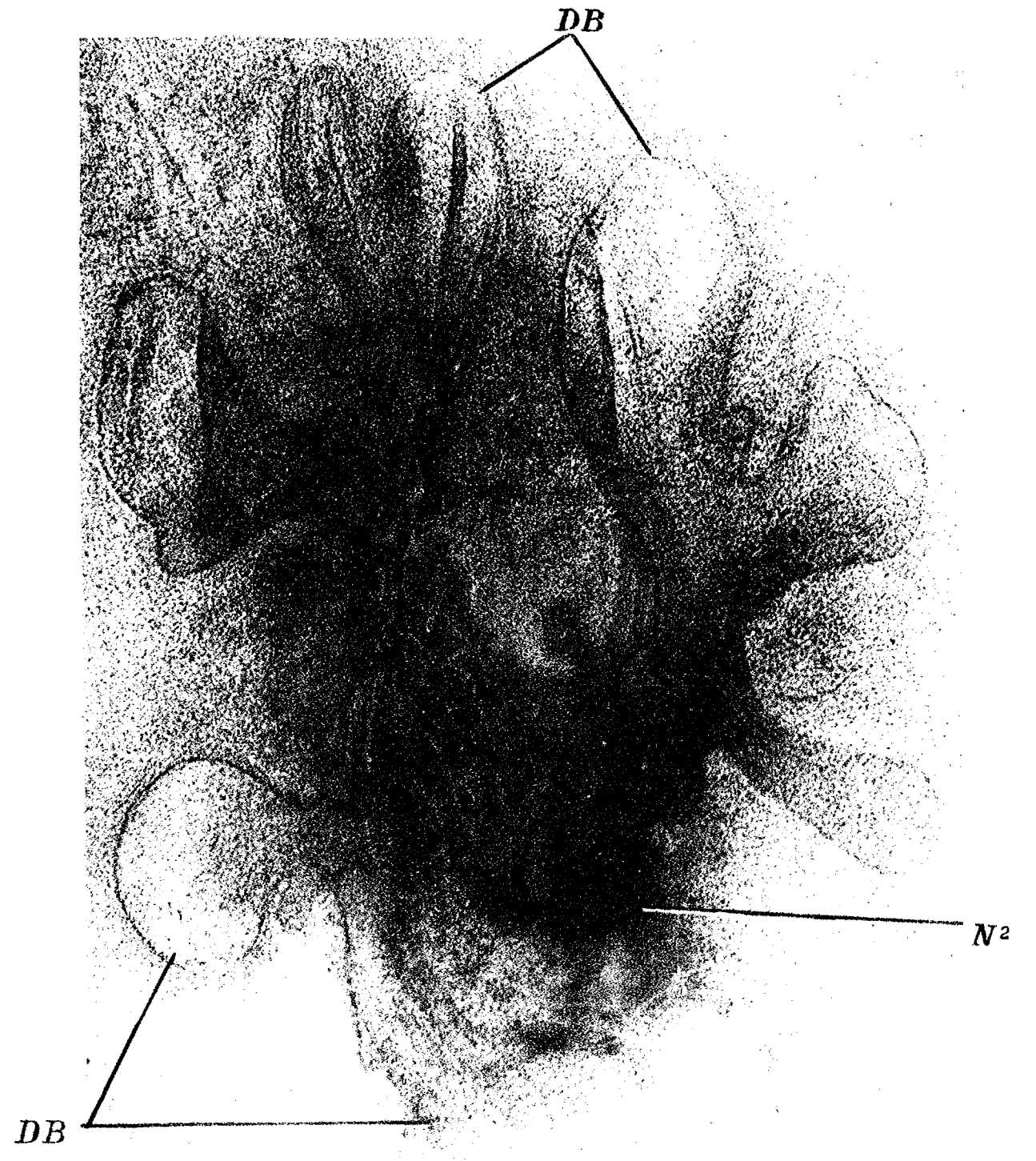

51

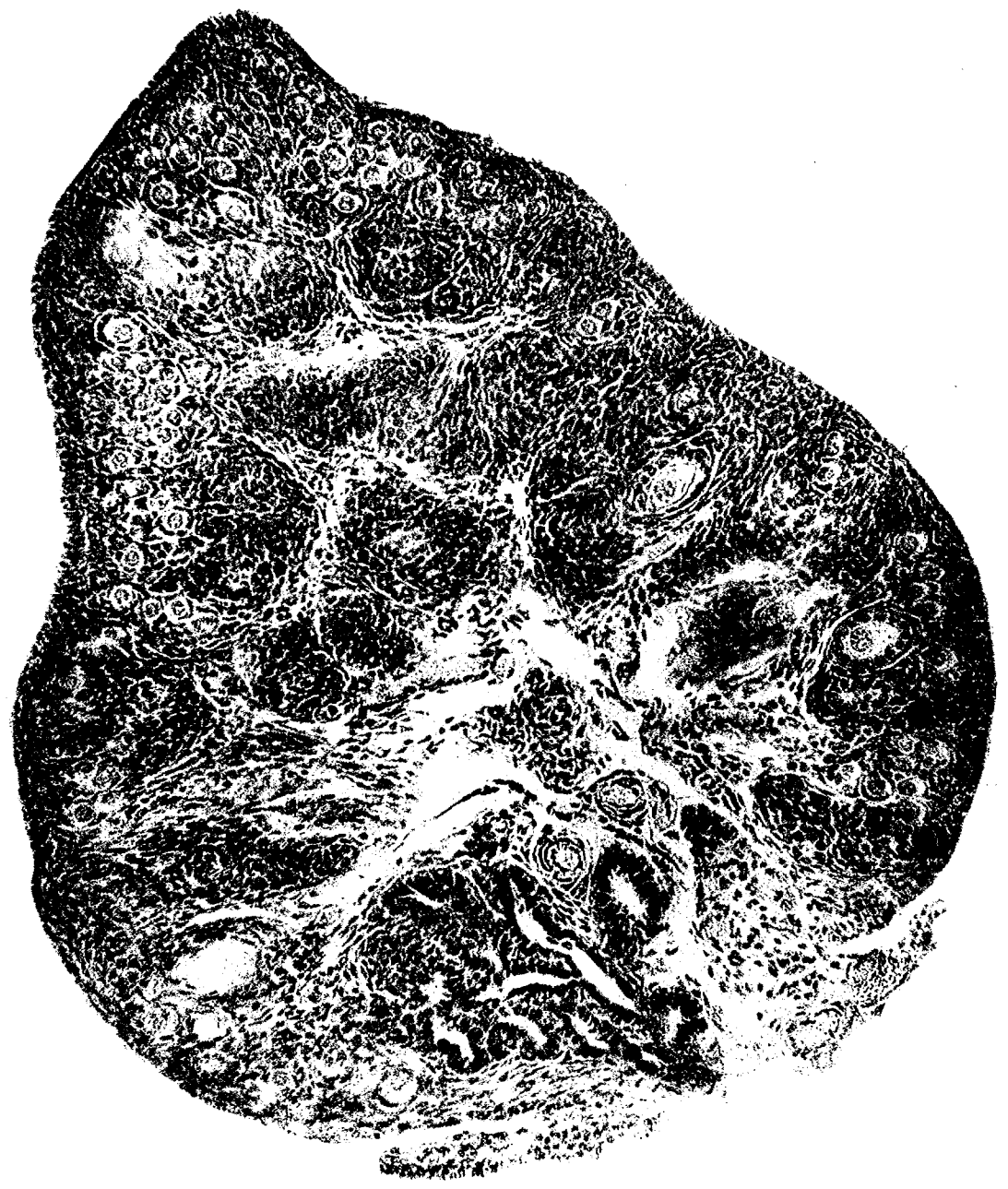

55

52

54

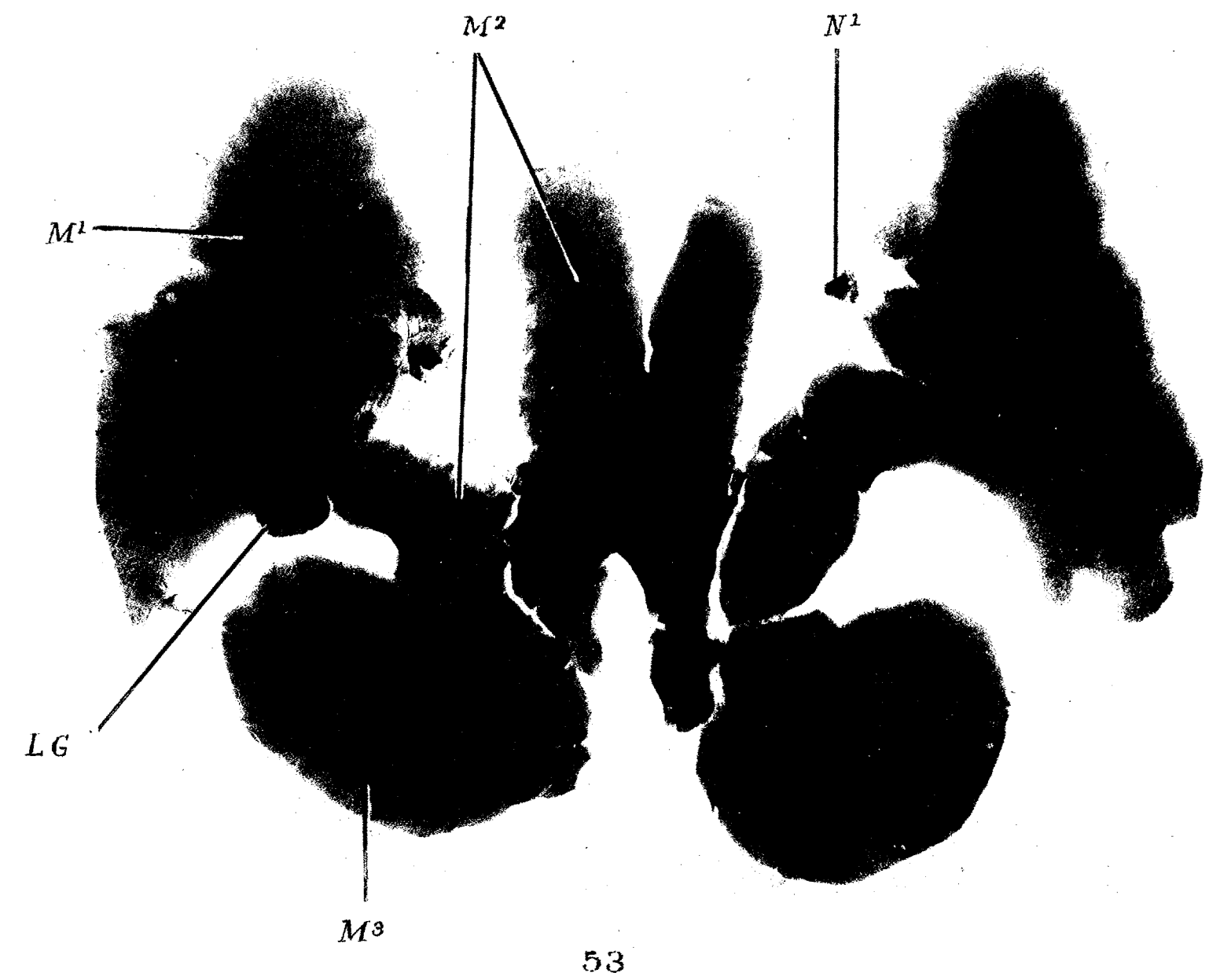

53

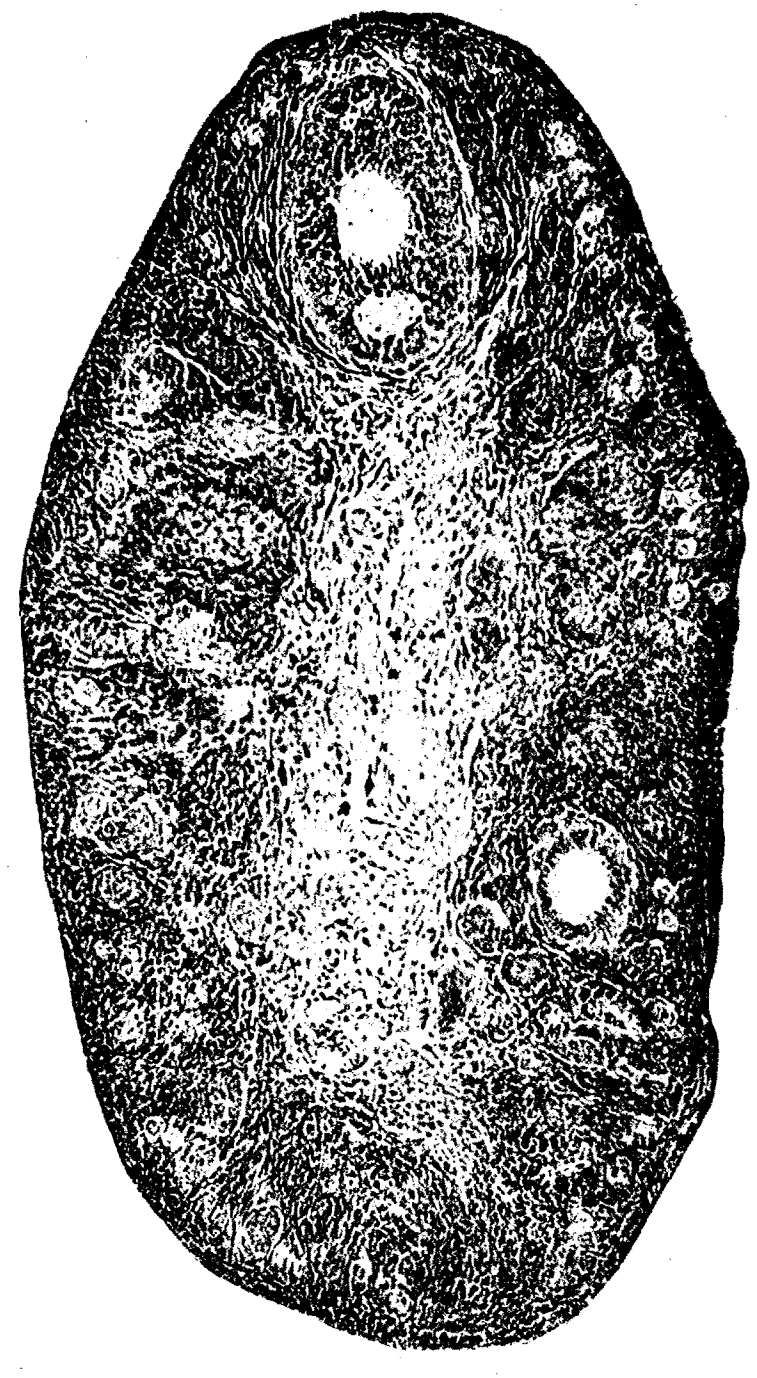

56

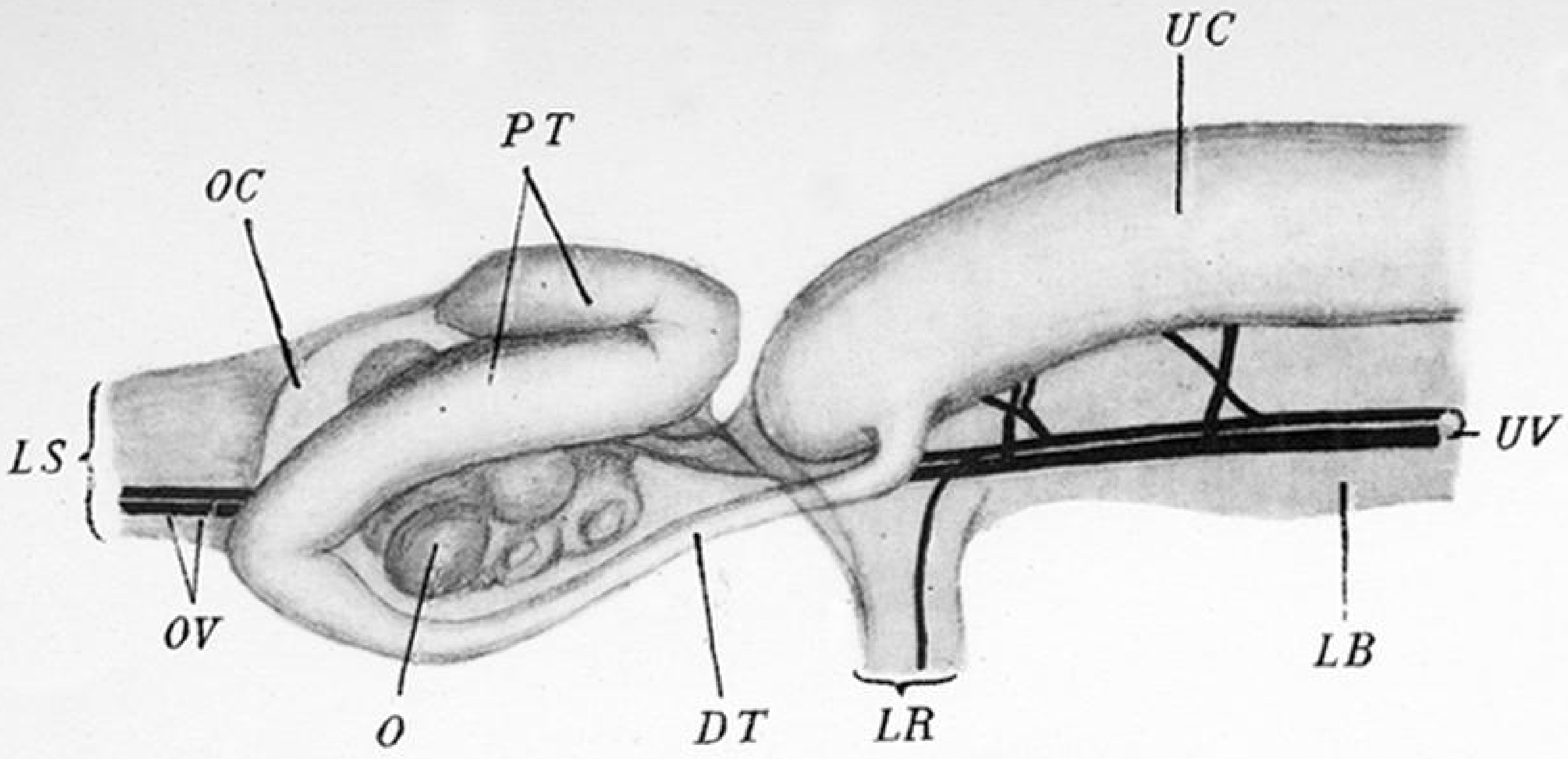

13

14

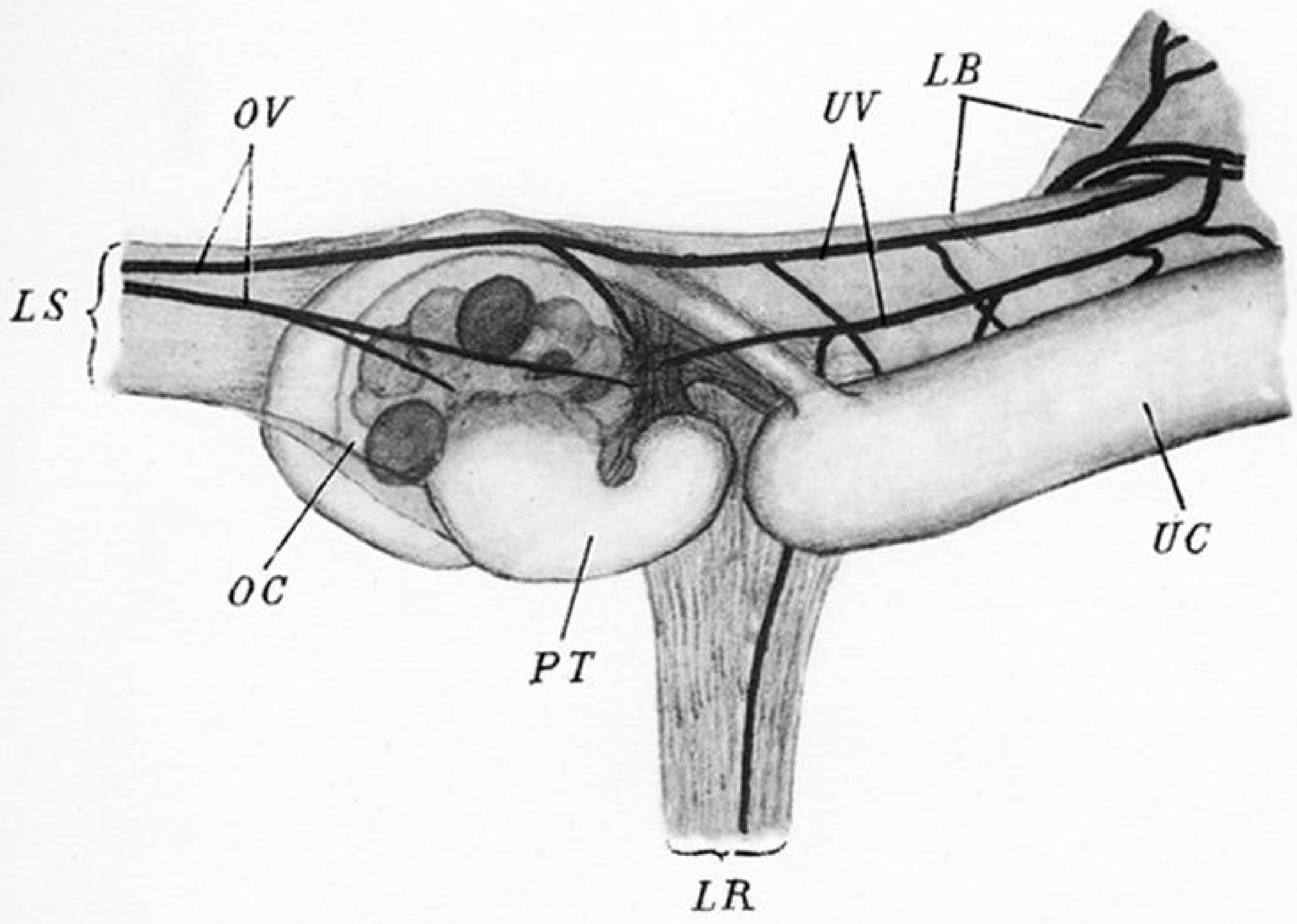

12

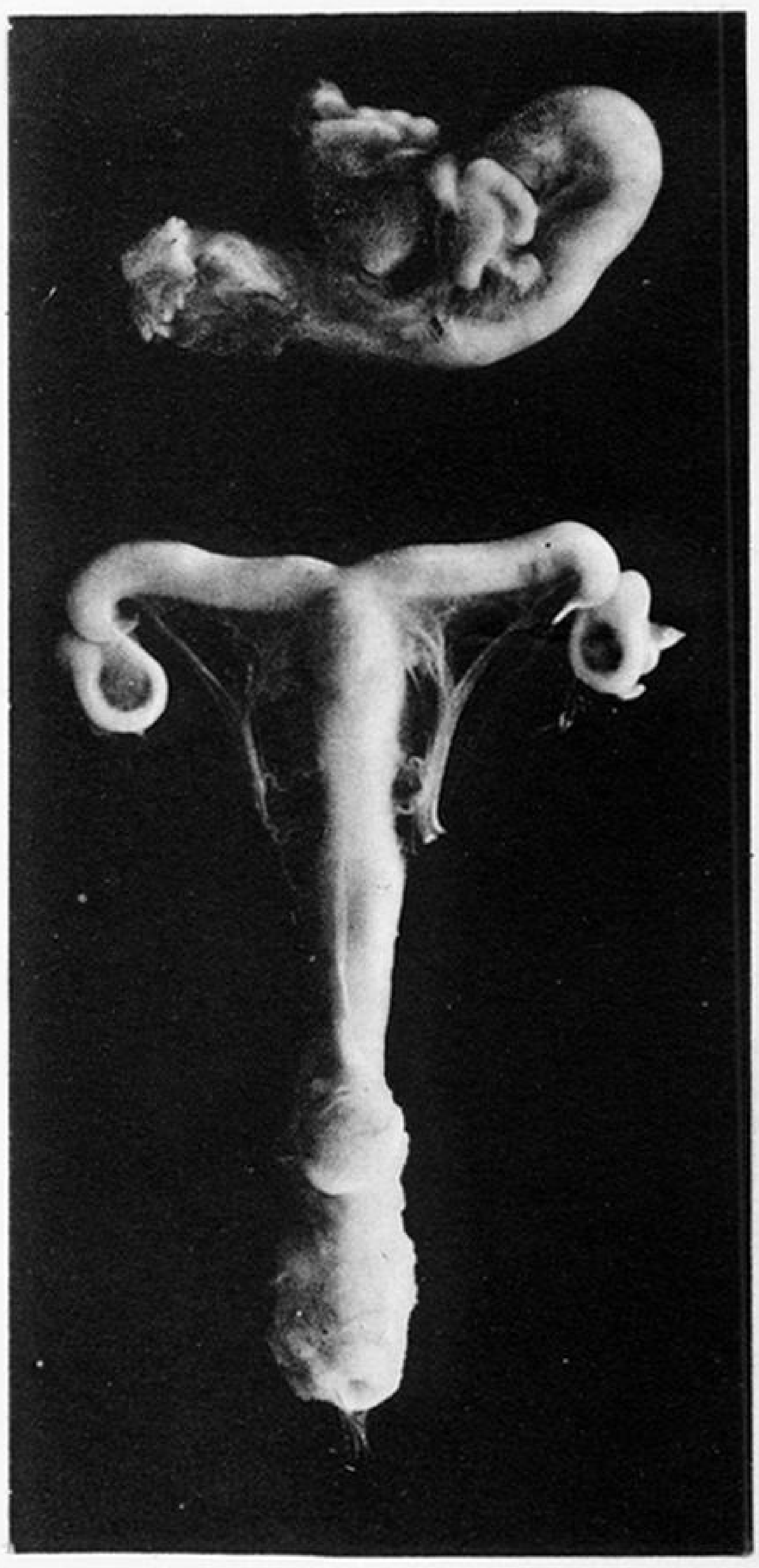

11

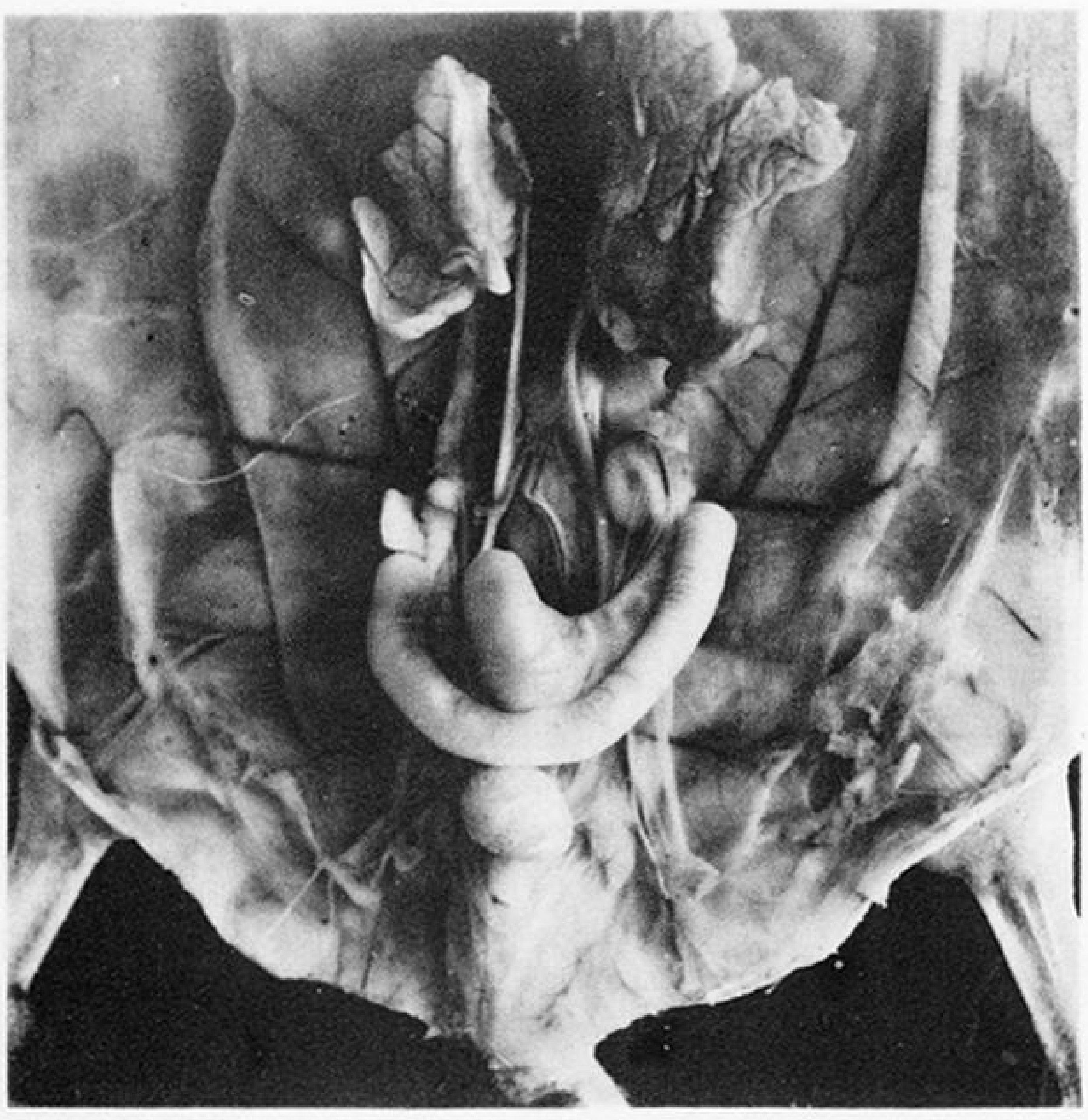

10

PLATE 1

FIG. 10—Photograph of the ventral aspect of a dissection of the reproductive organs *in situ* of a female Common Shrew. The upper part of the long vagina is bent back ventrally so that the uterus crosses the lower part just in front of the bladder. × 2·5.

FIG. 11—Photograph of the female reproductive organs dissected out. The lower part of the figure shows the organs displayed from the ventral surface. The great length of the vagina and the loops of the Fallopian tubes around the ovaries are seen. The upper part of the figure is a lateral view of a specimen showing the vaginal flexure. × 2·7.

FIGS. 12 and 13—Drawings of the ovary, Fallopian tube and associated structures. Fig. 12 is of the apparent ventral but true dorsal aspect. In fig. 13 the ovary is flexed to show the true ventral aspect. The wide proximal (*PT*) and narrow distal (*DT*) regions of the Fallopian tube can be distinguished and the junction with the tip of the uterine cornu (*UC*) laterally. The ovarian (*OV*) and uterine (*UV*) vessels are shown. The ovarian capsule (*OC*) is thin and transparent and completely encloses the ovary (*O*). The broad ligament (*LB*), suspensory ligament (*LS*), and round ligament (*LR*) are shown. × 10 approx.

FIG. 14—Semi-diagrammatic drawing of a longitudinal section of the upper part of the uterine cornu showing the opening of the Fallopian tube (*FT*) into it. *VE* = uterine epithelium. *M* = sub-epithelial mucosa. *FZ* = fibrous connective tissue zone present in non-parous animals only. *CM* = circular muscle. *LM* = longitudinal muscle. × 42 approx.

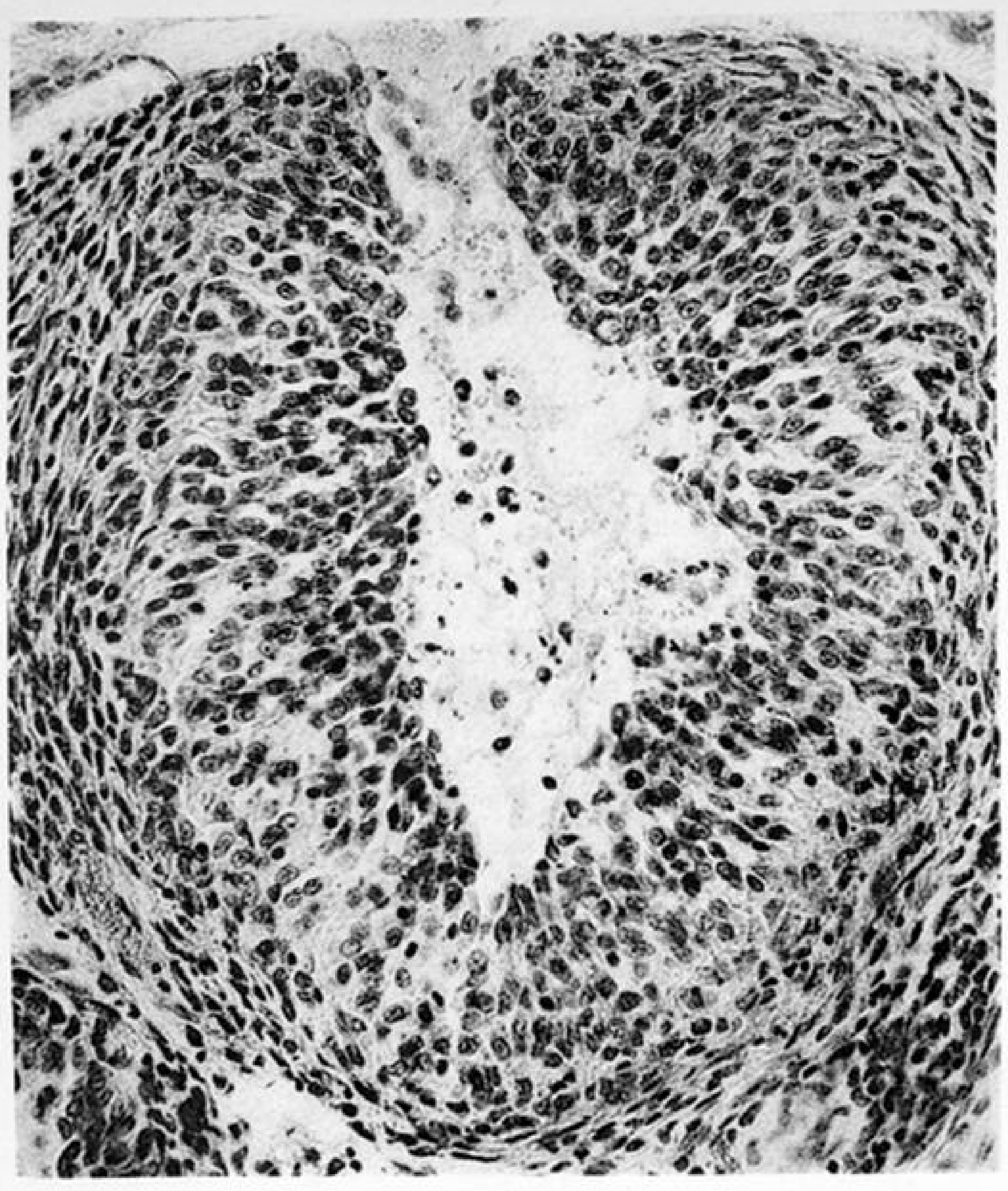

15

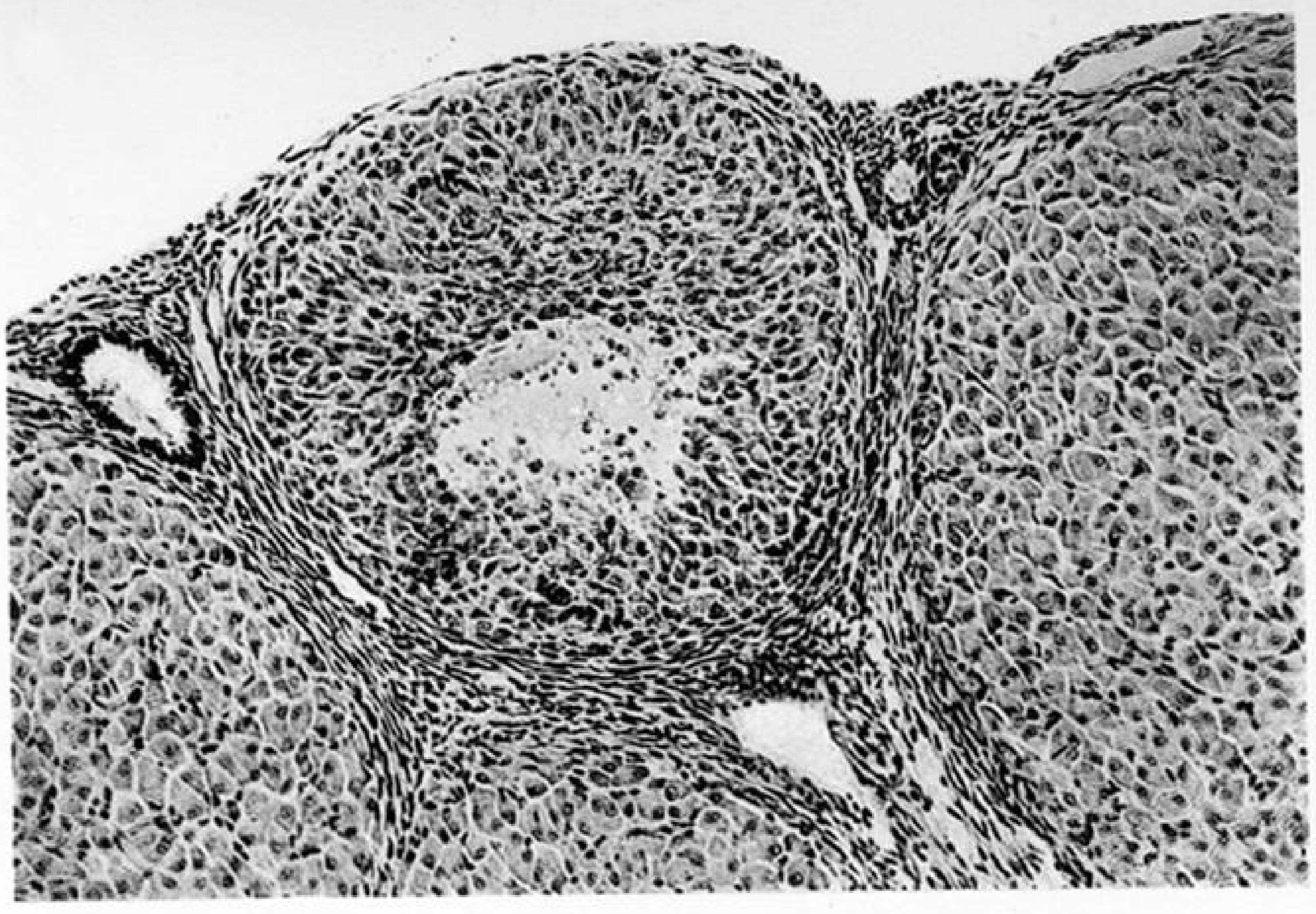

20

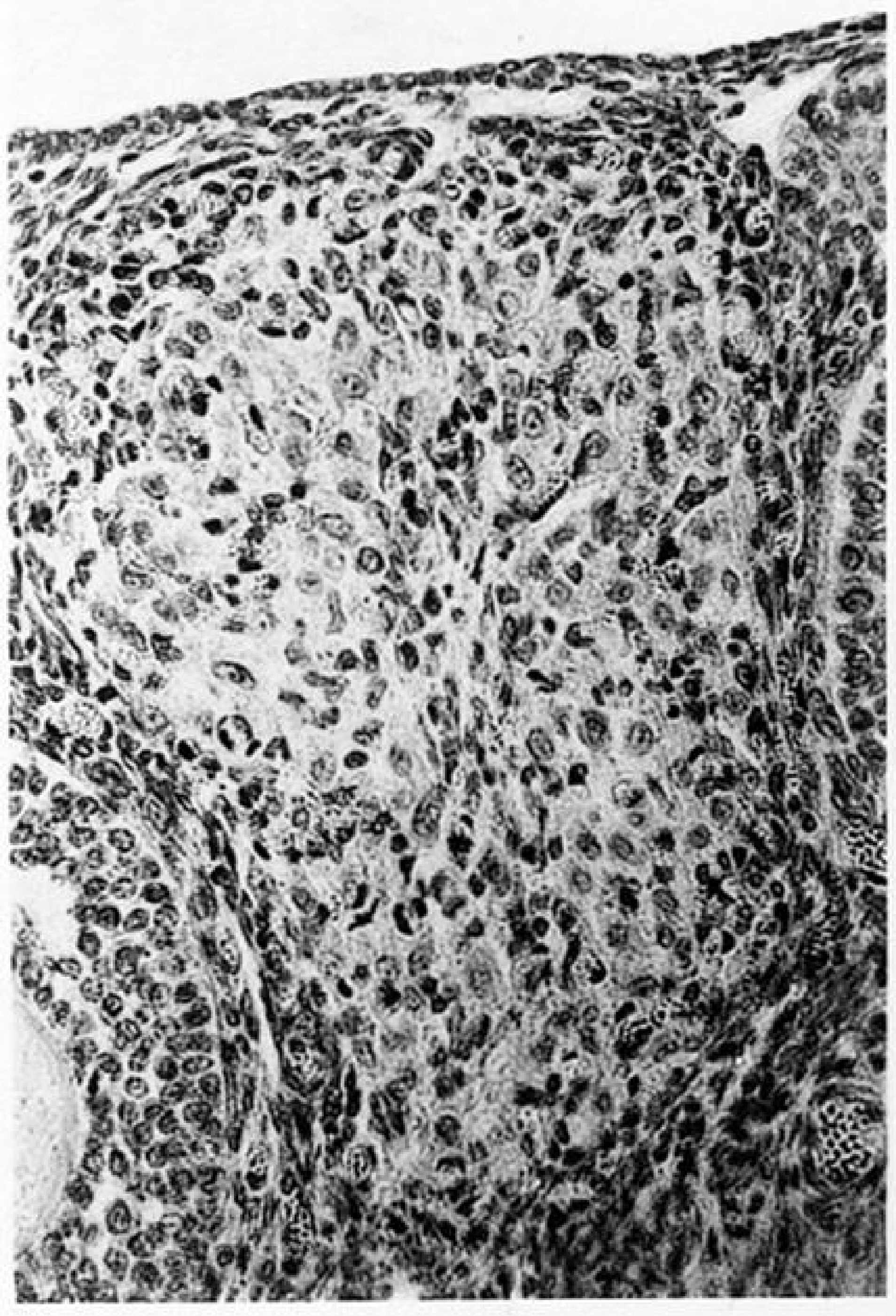

19

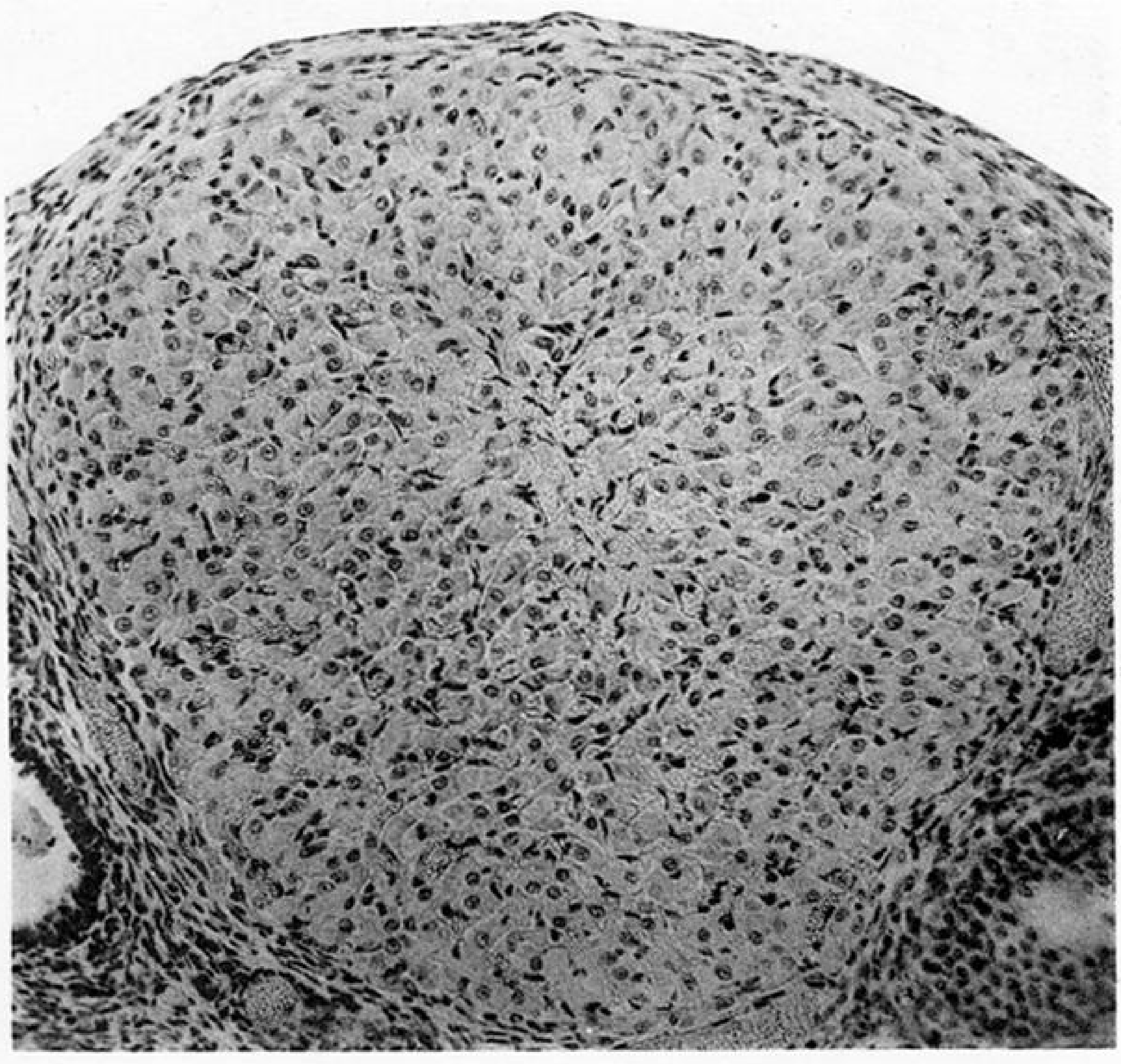

17

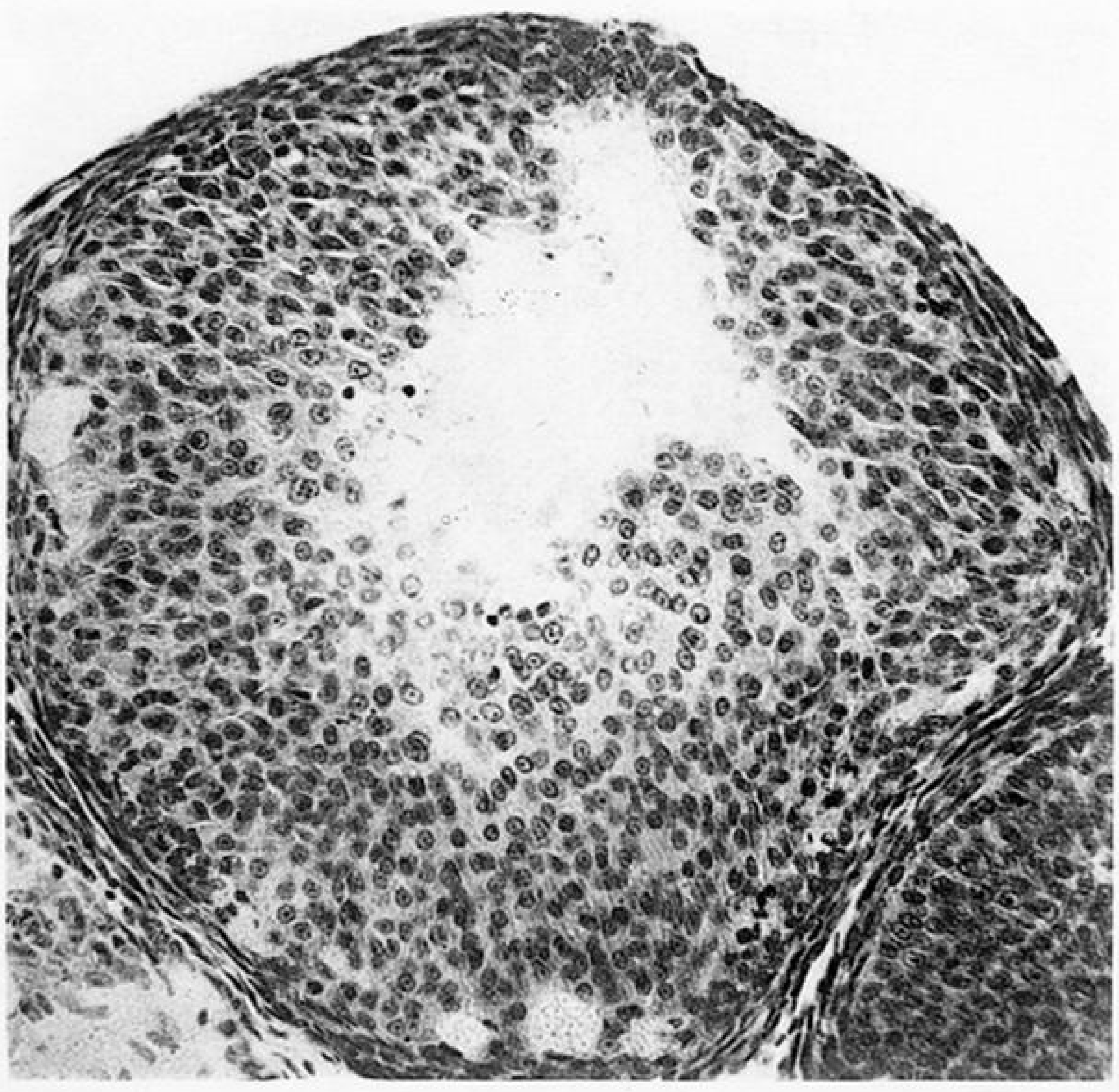

16

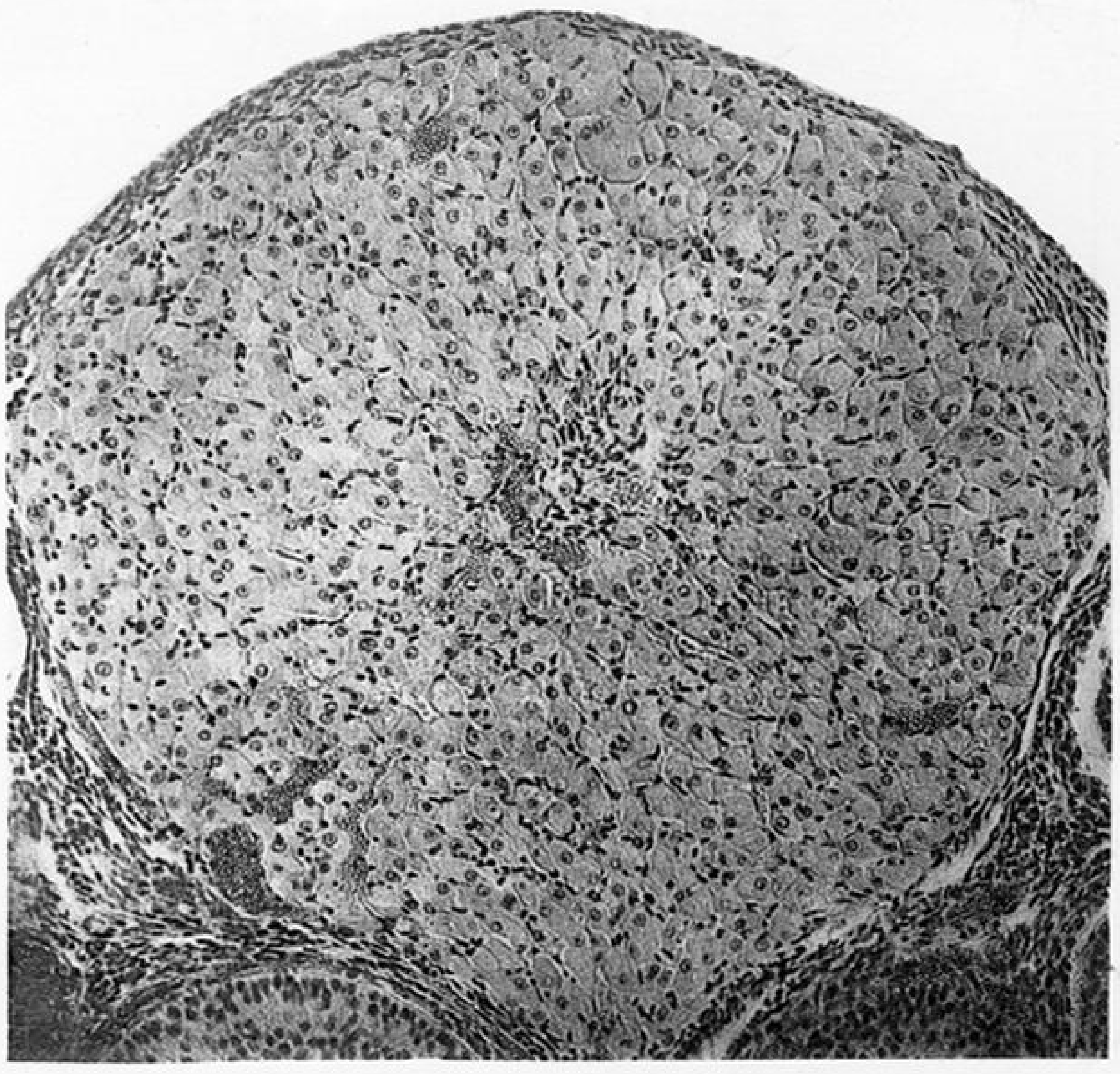

18

PLATE 2

FIG. 15—Photomicrograph of a recently ruptured follicle (S. 879) showing that the follicular wall is not folded. The ova, in the proximal part of the Fallopian tube, contain 2nd polar spindles and sperms are present in the vagina. × 220.

FIG. 16—Photomicrograph of the developing corpus luteum (S. 20) showing the first indications of connective tissue ingrowth from the theca. The cavity is still patent. The ingrowth of the membrana granulosa is active ; the cells are enlarging and their nuclei are becoming rounded. The ova are in the proximal part of the Fallopian tube and exhibit 1st cleavage spindles. × 200.

FIG. 17—Photomicrograph of the corpus luteum at the stage (S. 943) when the blastocysts have passed recently into the uterus. The luteal cells are large with rounded nuclei and the corpus luteum is hyperæmic. The connective tissue reticulum is not fully developed. × 167.

FIG. 18—Photomicrograph of the corpus luteum at its maximum development (S. 1129) shortly before implantation of the blastocysts. The luteal cells are very large and the connective tissue reticulum is well developed. The corpus luteum is hyperæmic and its centre is occupied by a small clot. × 127.

FIG. 19—Photomicrograph of the corpus luteum at approximately full time (S. 949). It is small, shrunken and obviously retrogressing. × 253.

FIG. 20—Photomicrograph of a section of the ovary of S. 944 which exhibited super-ovulation. One of the newer set of corpora lutea, corresponding to the 2-cell tubal ova, is in the centre with parts of three of the older set of corpora lutea, corresponding to the uterine blastocysts, surrounding it. × 133.

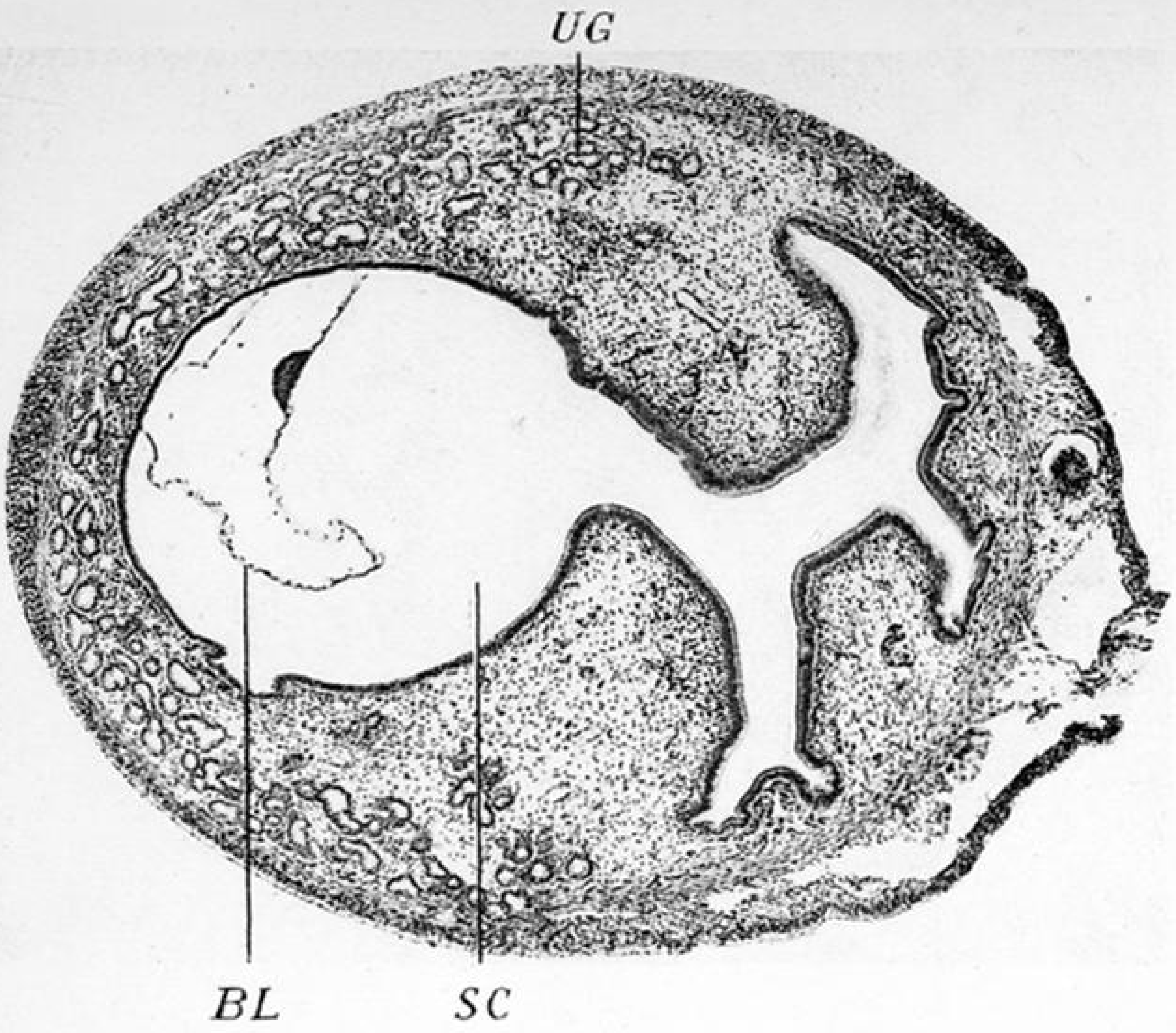

26

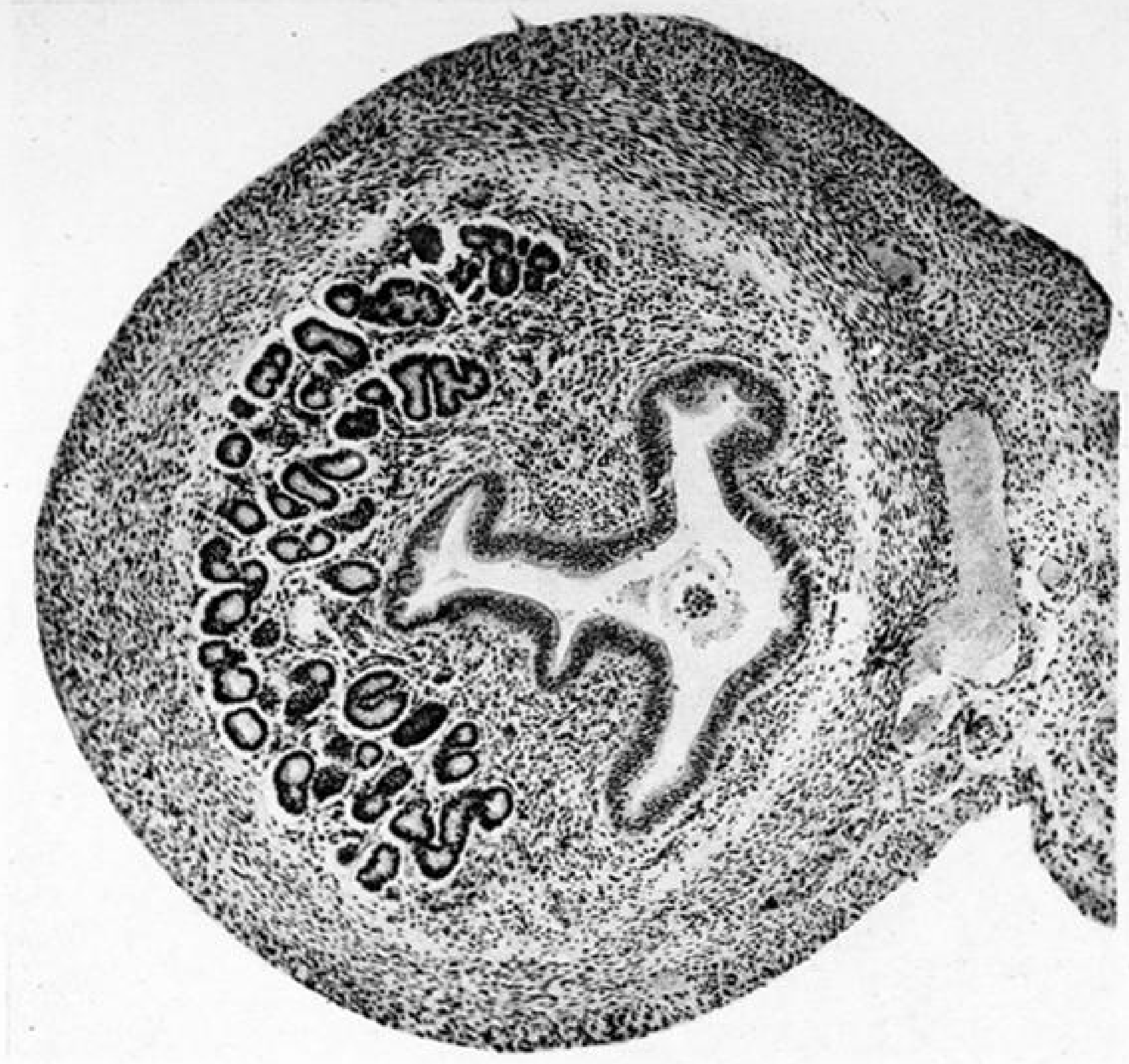

25

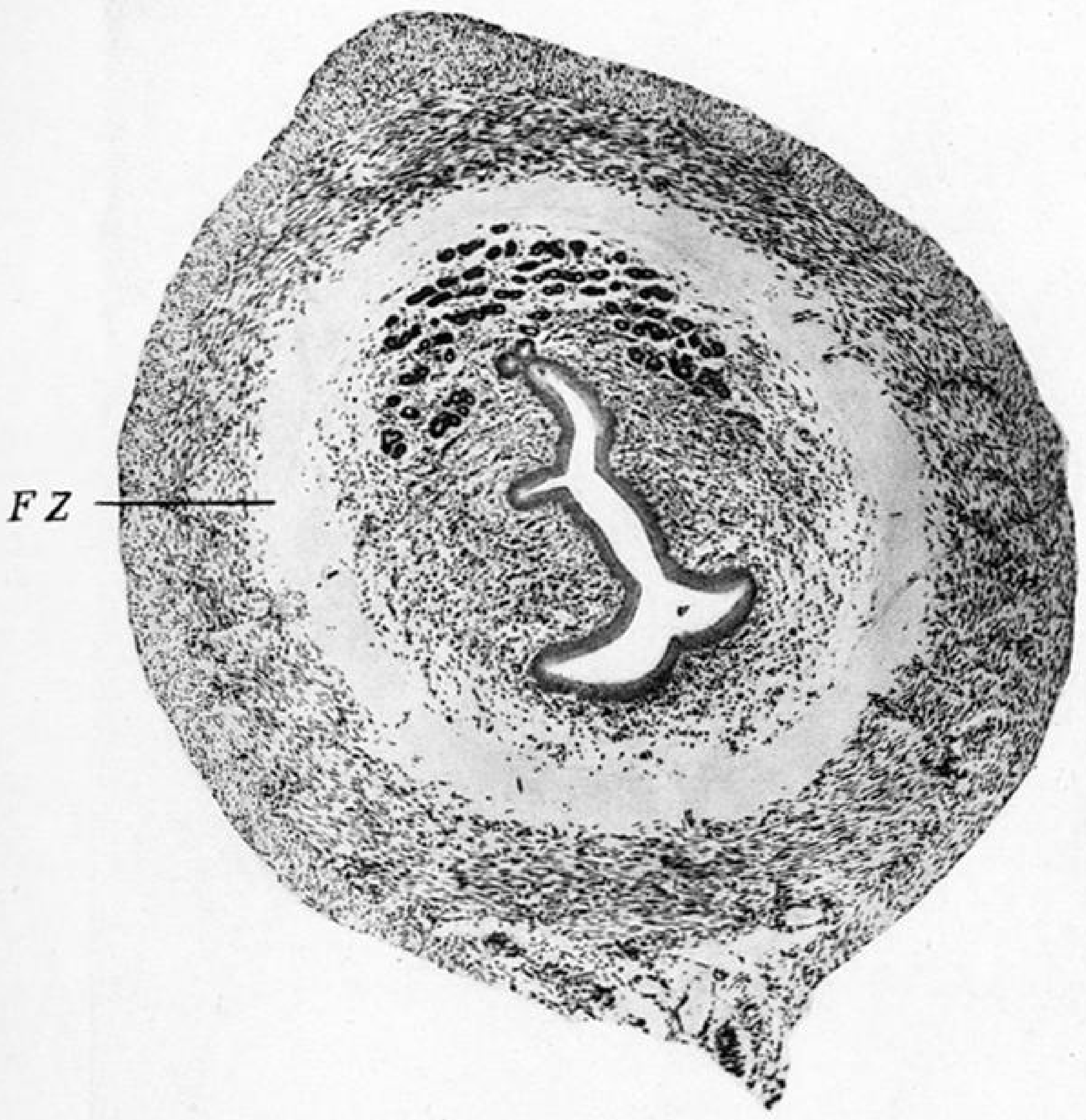

23

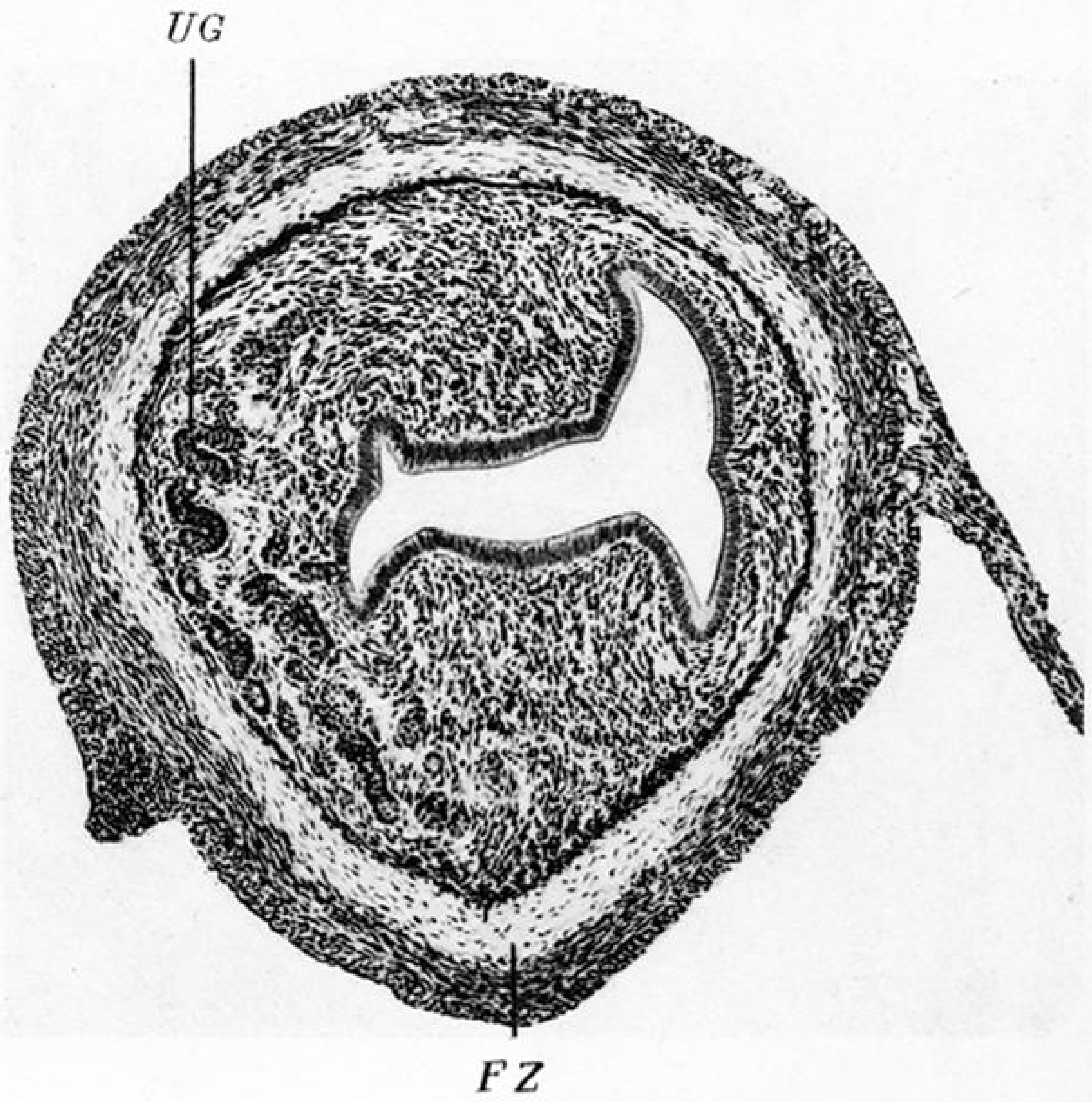

21

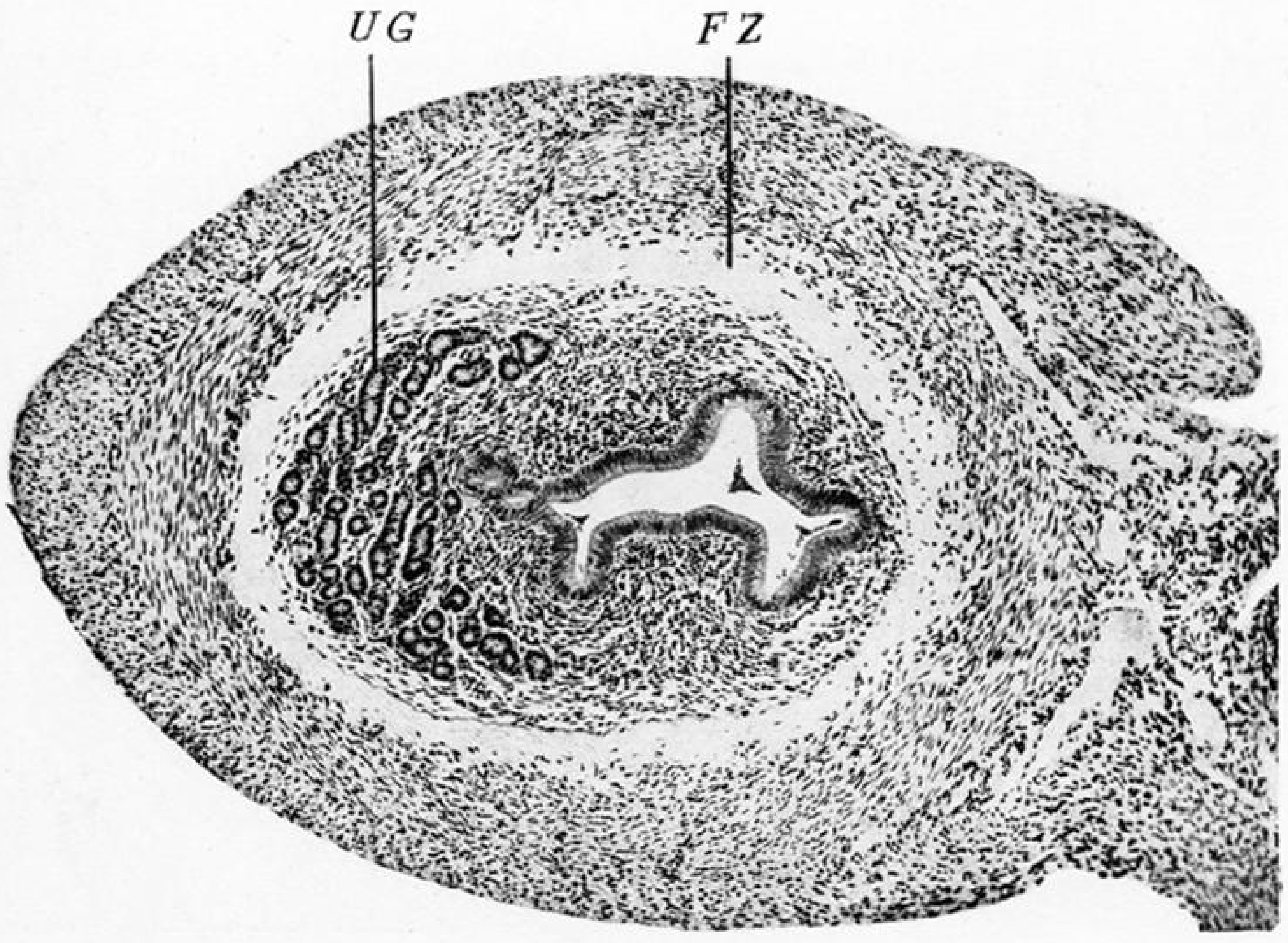

24

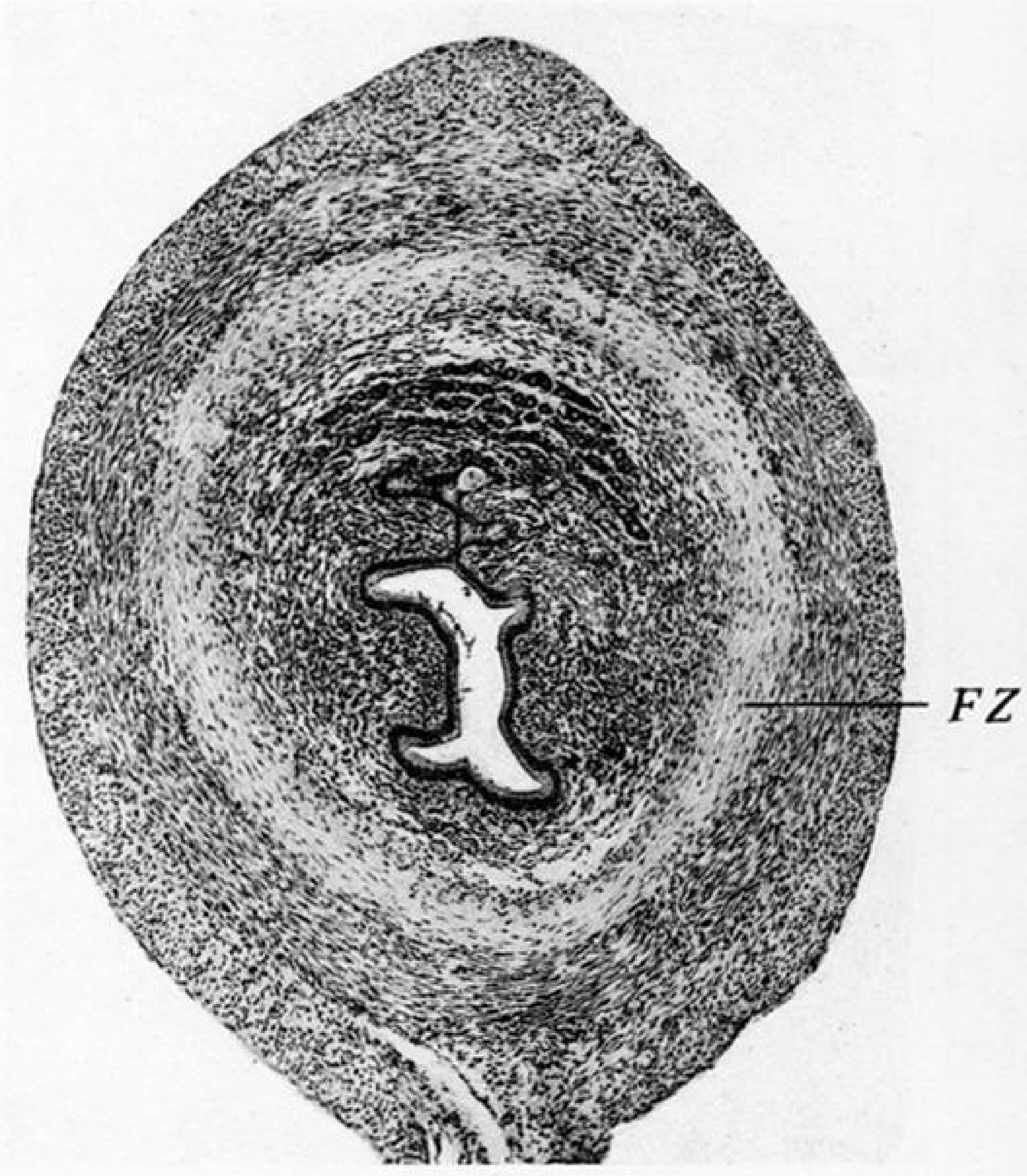

22

PLATE 3

FIG. 21—Photomicrograph of a transverse section of an immature uterus (S. 78) showing the absence of blood vessels with hyaline walls and the presence of the characteristic zone (*FZ*) between the mucosa and the muscularis. The uterine glands (*UG*) are small. × 104.

FIG. 22—Photomicrograph of a transverse section of the uterus during first œstrus (S. 911) showing the same features as fig. 21 but the mucosa and the muscularis are enlarged and both secretion and sperms are present in the lumen. The fibrous connective tissue zone (*FZ*) is shown. × 69.

FIG. 23—Photomicrograph of a transverse section of the uterus of a non-parous shrew immediately after ovulation (S. 879). It has enlarged still further and the uterine glands have extended. The fibrous zone (*FZ*) is very plain. × 53.

FIG. 24—Photomicrograph of a transverse section of the uterus of a non-parous shrew with 8-cell stages in the Fallopian tubes (S. 940). The glands (*UG*) are enlarged and have extended laterally. The uterine epithelium has become thicker. *FZ* = fibrous connective tissue zone. × 66.

FIG. 25—Photomicrograph of a transverse section of the uterus at a stage (S. 943) with early uterine blastocysts, one of which is shown. The uterine epithelium has become very thick and the glands are much enlarged and have extended considerably. × 60.

FIG. 26—Photomicrograph of a transverse section of the uterus (S. 1143) showing a late blastocyst (*BL*) in a spherical chamber (*SC*) becoming attached to the uterine wall. The uterine wall has become stretched and thin on the anti-mesometrial side and the uterine glands (*UG*) have extended round the sides. × 36.

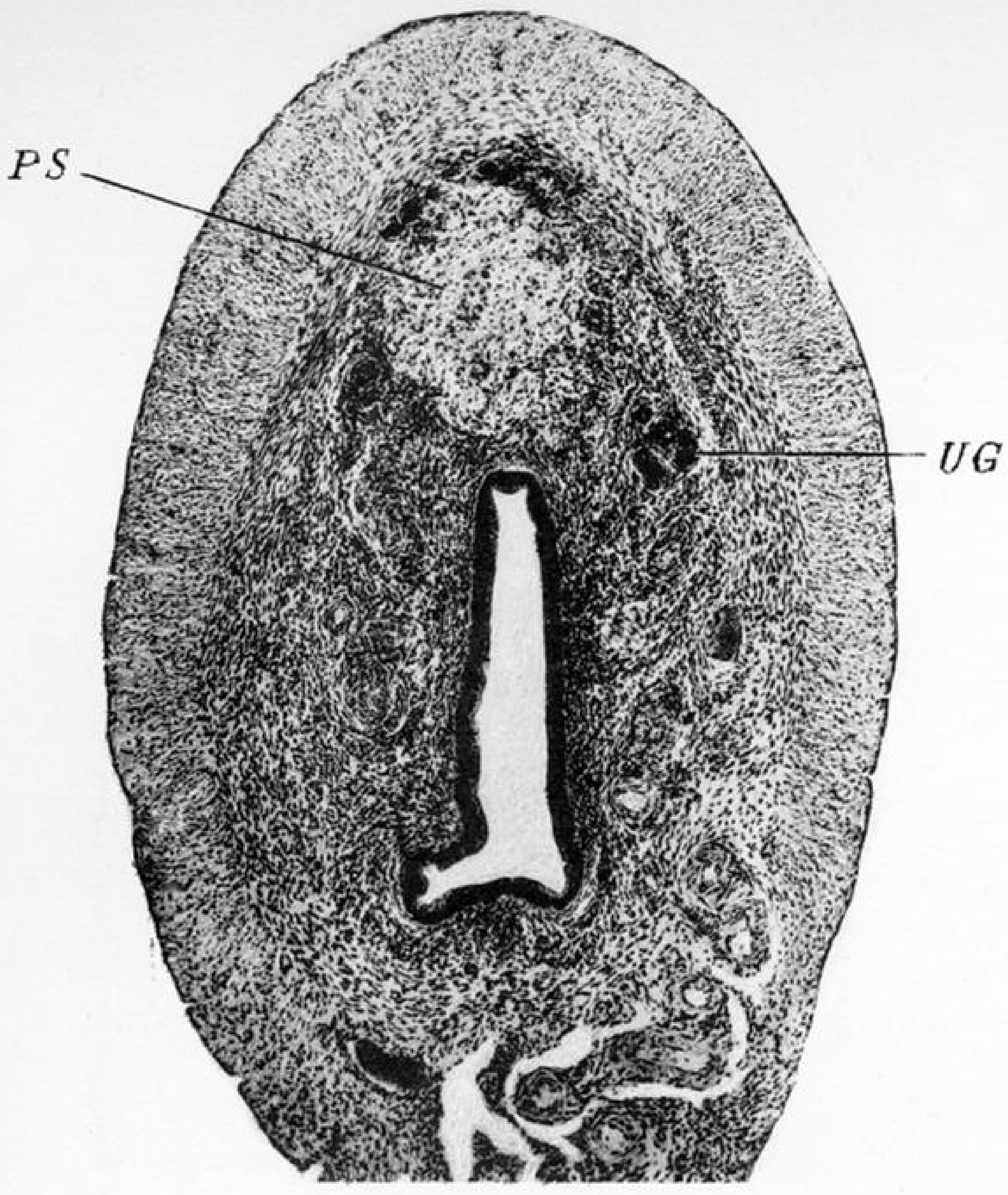

30

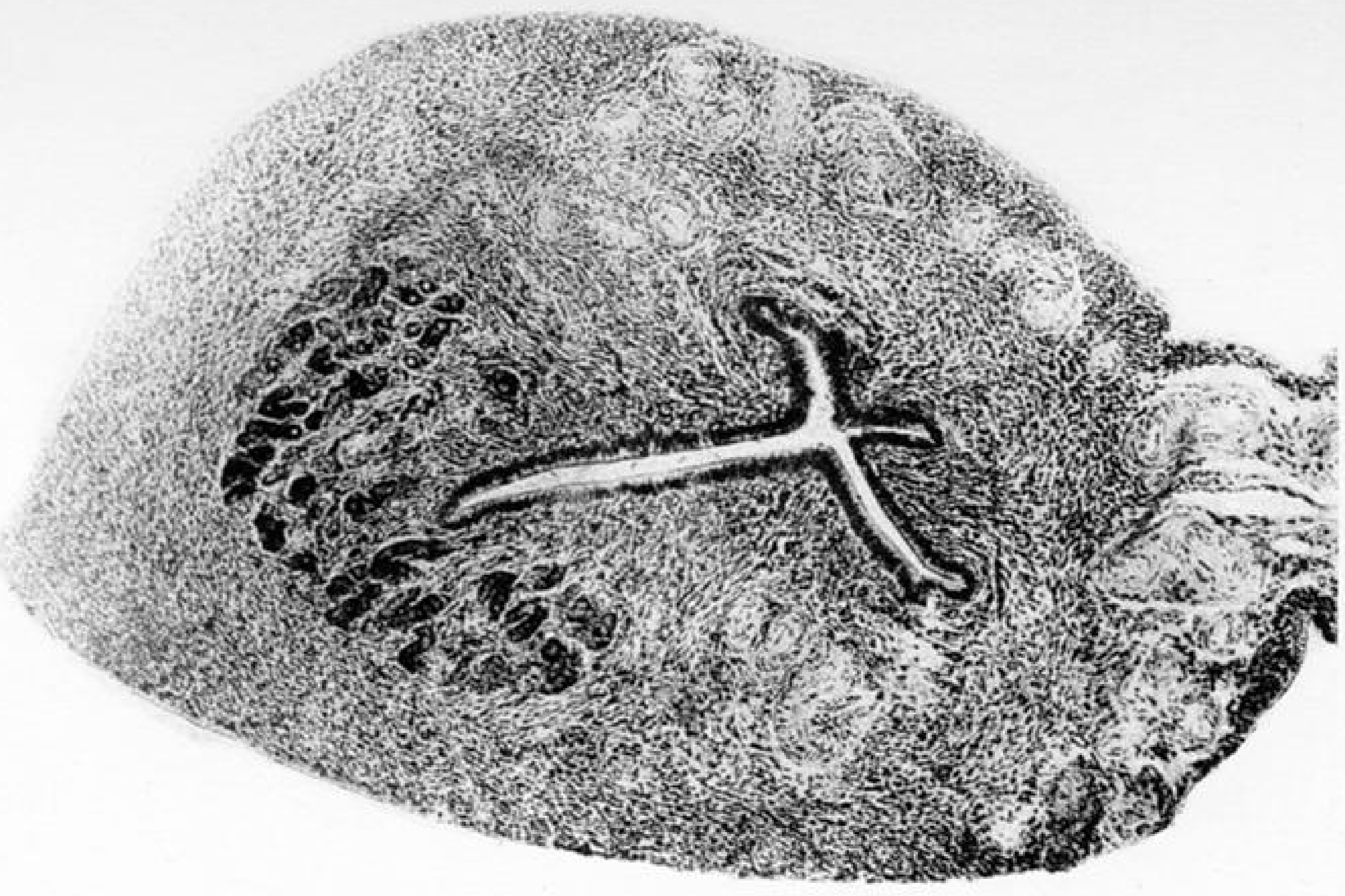

31

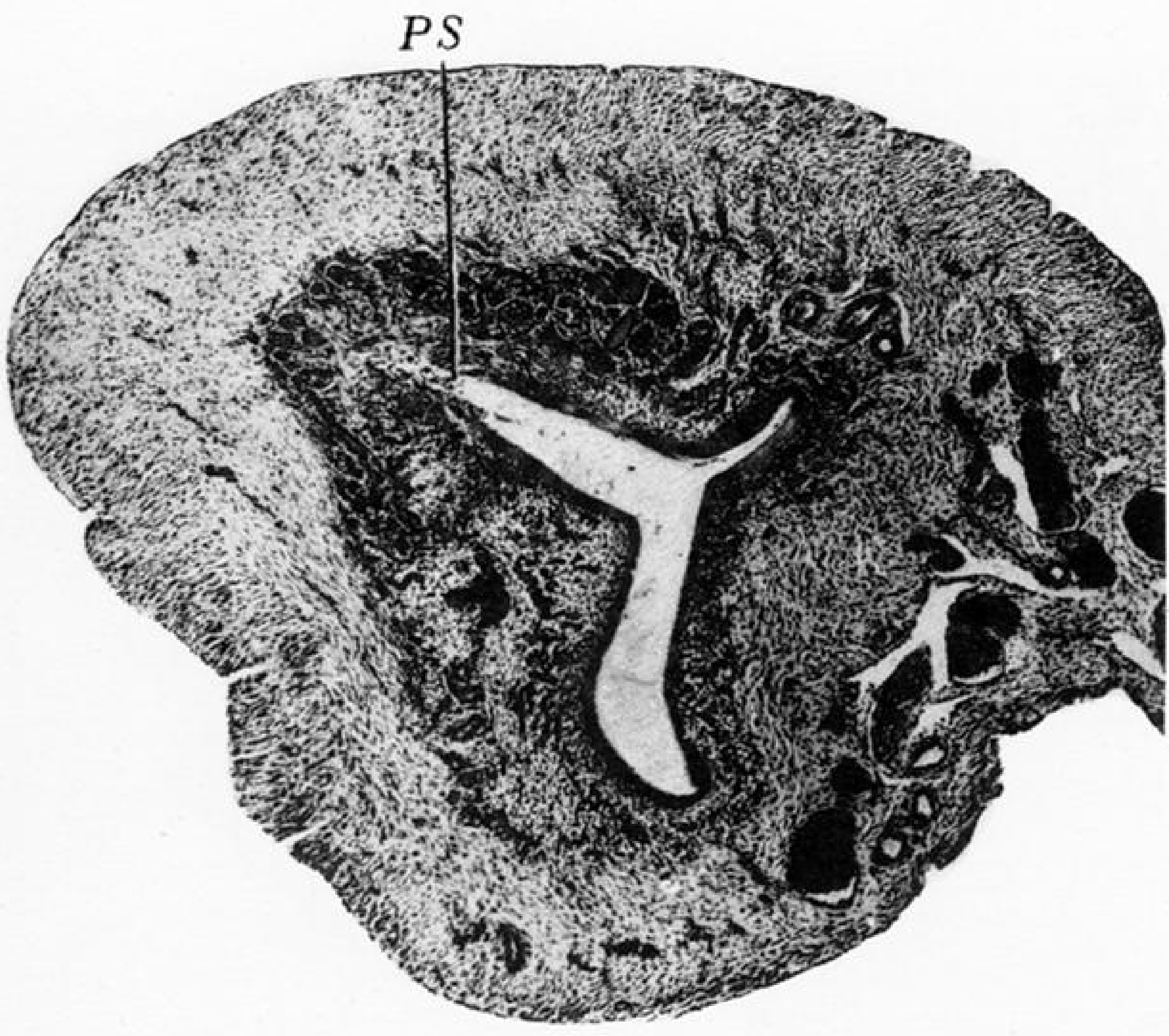

29

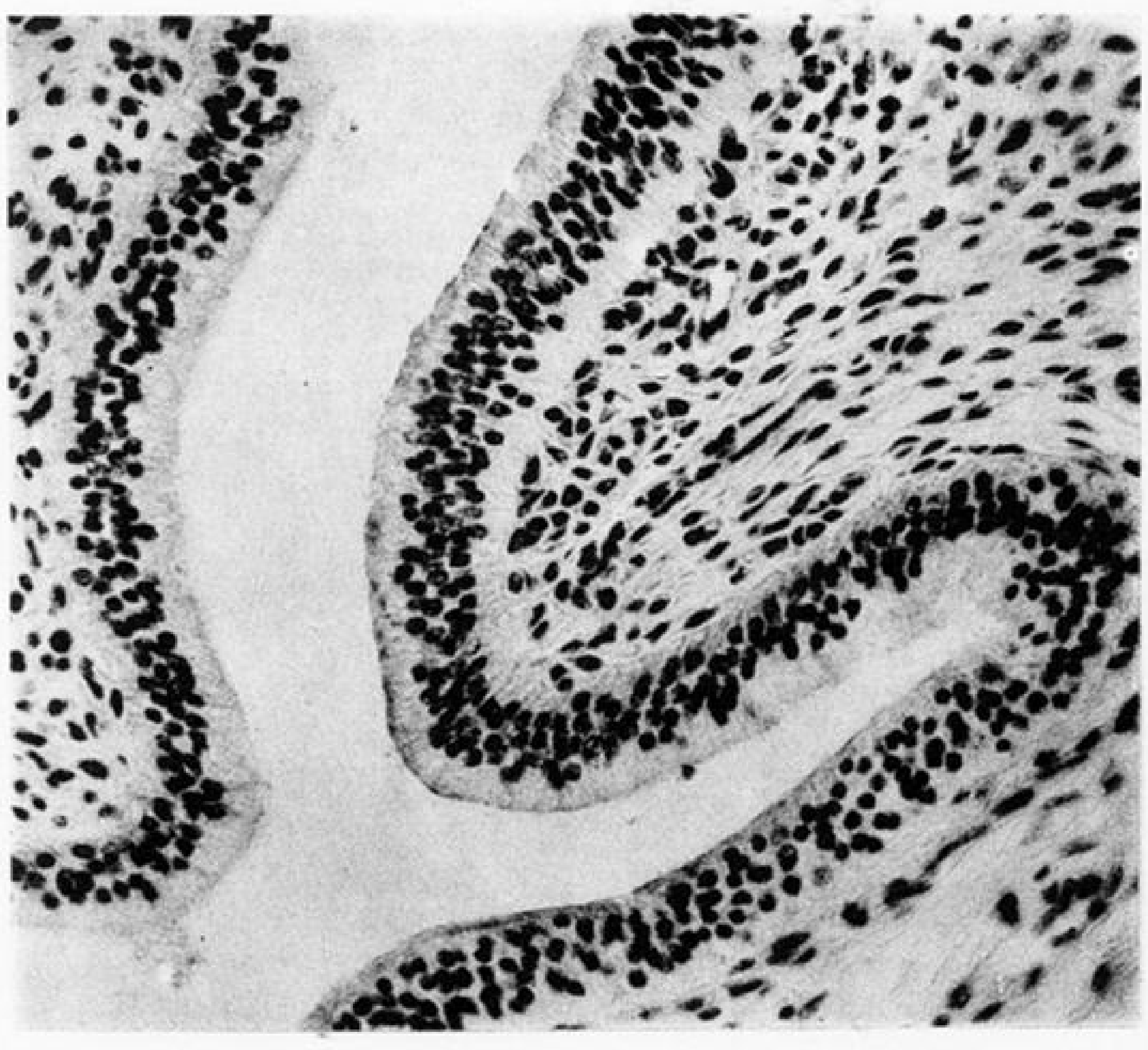

28

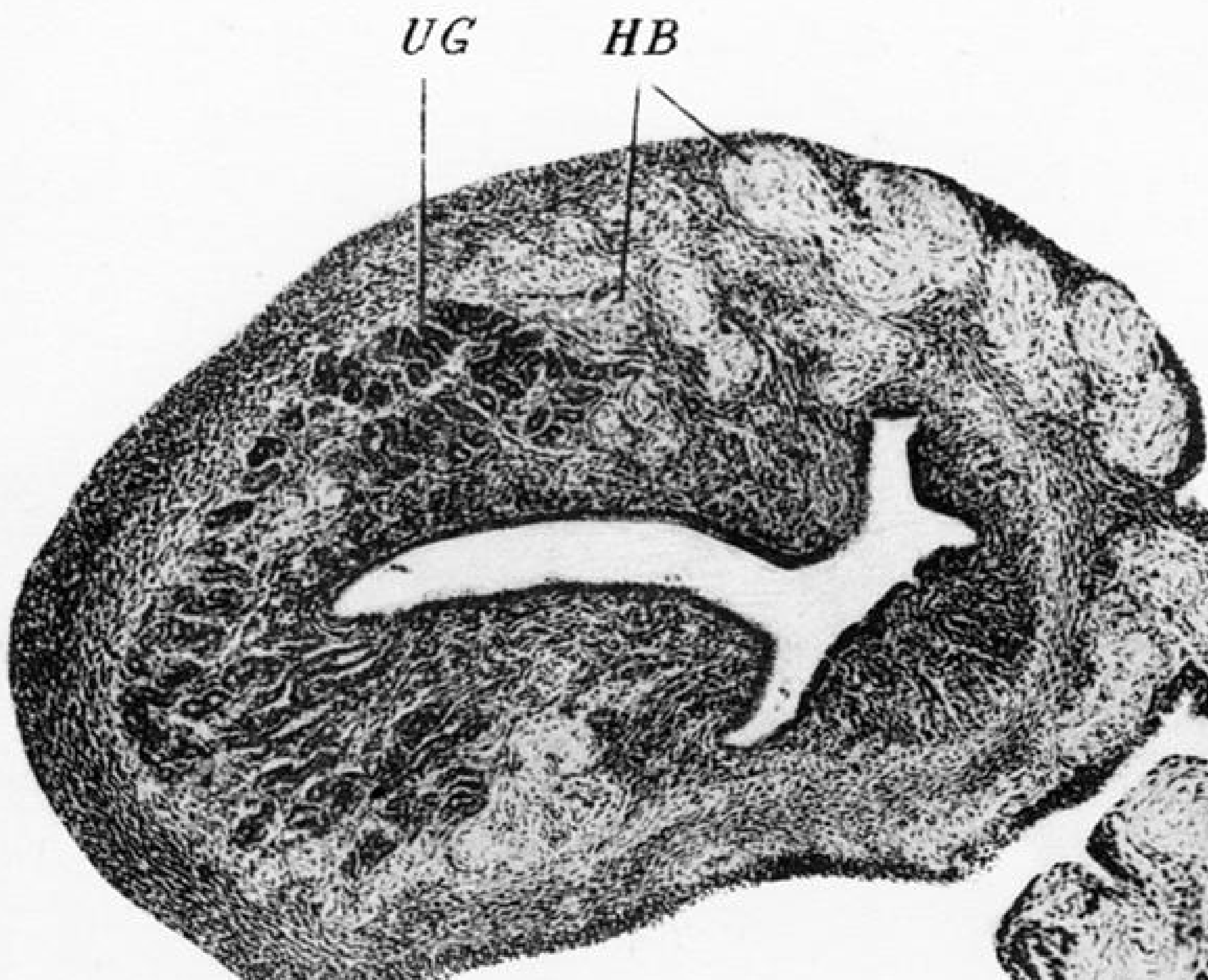

32

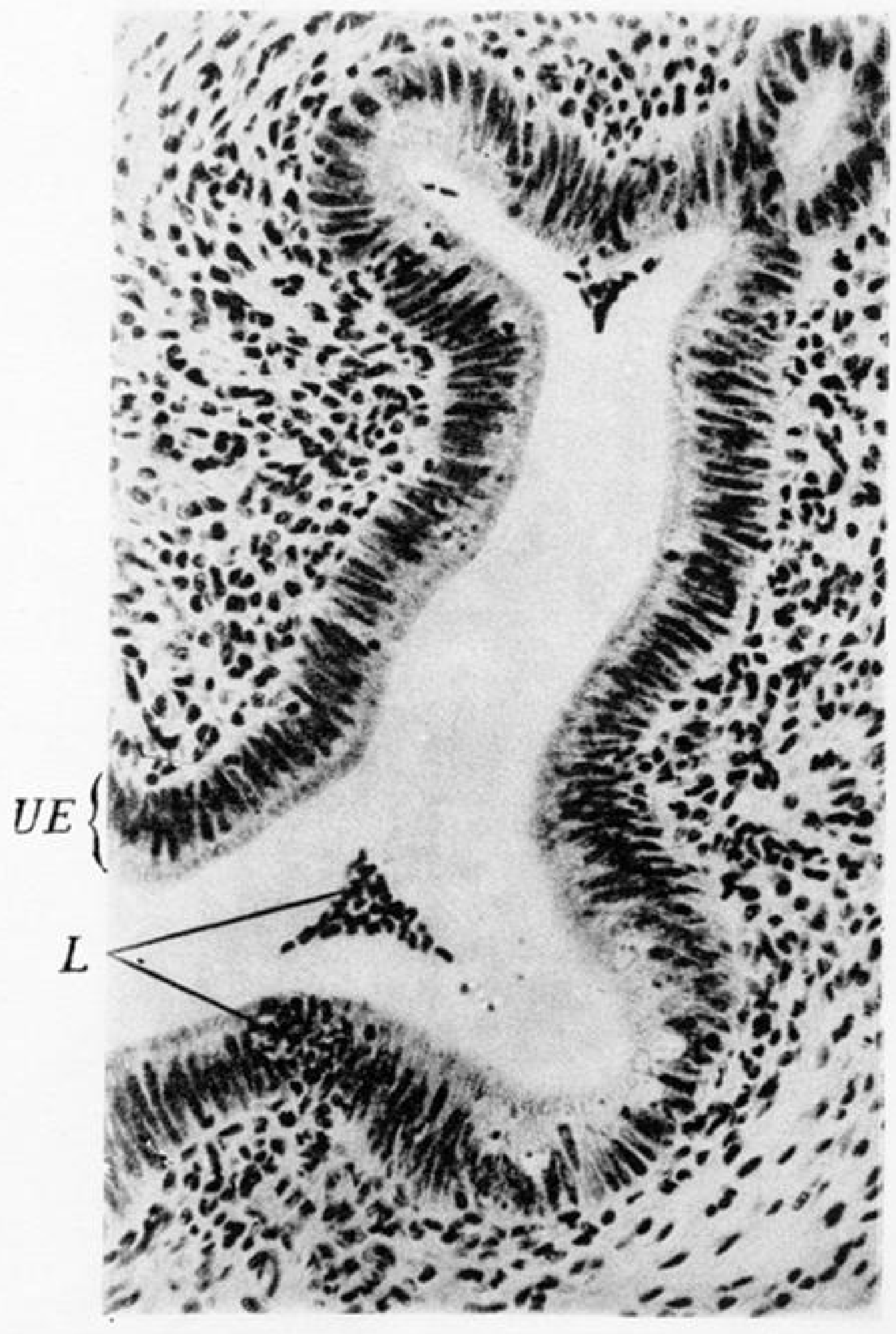

27

PLATE 4

FIG. 27—Photomicrograph of a part of the uterine epithelium (*UE*) of S. 940 shown in fig. 24. Leucocytes (*L*) are numerous in the mucosa and lumen. The epithelium is columnar with elongated nuclei arranged in a single row in the cells at the ends away from the lumen. × 234.

FIG. 28—Photomicrograph of a part of the uterine epithelium of a stage (S. 947) with blastocysts in the Fallopian tubes. The epithelium has changed completely in appearance owing to rearrangement of the nuclei in several rows in the cells. Leucocytes are very scarce in the mucosa. × 234.

FIG. 29—Photomicrograph of a transverse section of a parous uterus (S. 983) through a placental site (*PS*) which has not yet healed. The whole uterus is enlarged and intensely hyperæmic. The fibrous zone between the mucosa and muscularis found in non-parous uteri has entirely disappeared. Ova in the 4-cell stage are present in the Fallopian tubes. × 32.

FIG. 30—Photomicrograph of a transverse section of a parous uterus (S. 1047) through a placental site (*PS*). The mucosa has healed completely over the placental site although the ova of the post-partum œstrus are blastocysts still in the Fallopian tubes. The uterine glands (*UG*) are reforming and the hyperæmia has subsided. The blood vessels have the thick hyaline walls characteristic of œstrus. × 57.

FIG. 31—Photomicrograph of a transverse section of the uterus during lactation anœstrus (S. 200). × 78.

FIG. 32—Photomicrograph of a transverse section of the uterus during winter anœstrus (S. 646, February). The thick hyaline walls of the blood vessels (*HB*) and the absence of the characteristic zone of fibrous tissue between the mucosa and muscularis show that it is parous. The condition of the glands (*UG*) and uterine epithelium and its small size show that it is completely inactive. × 100.

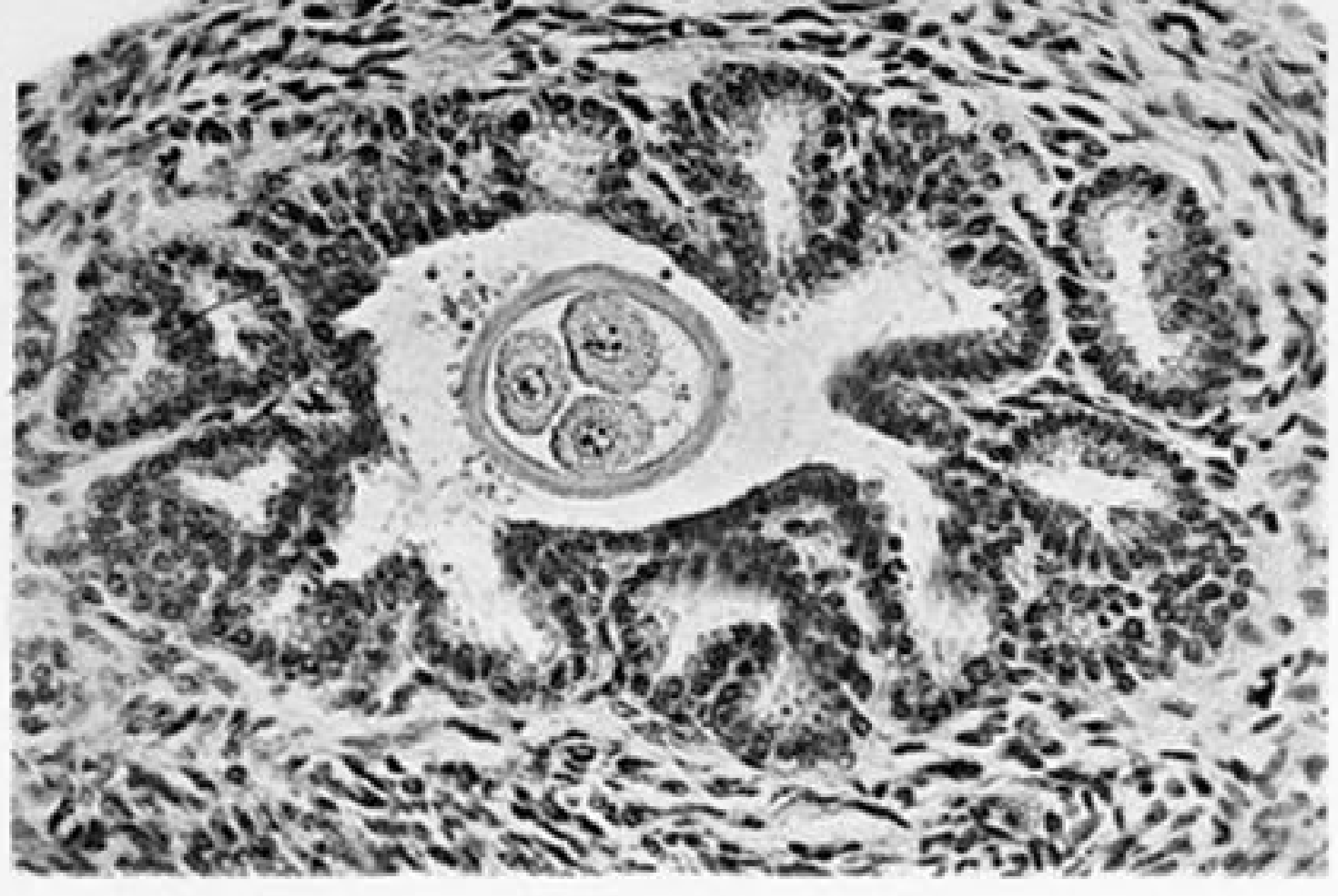

35

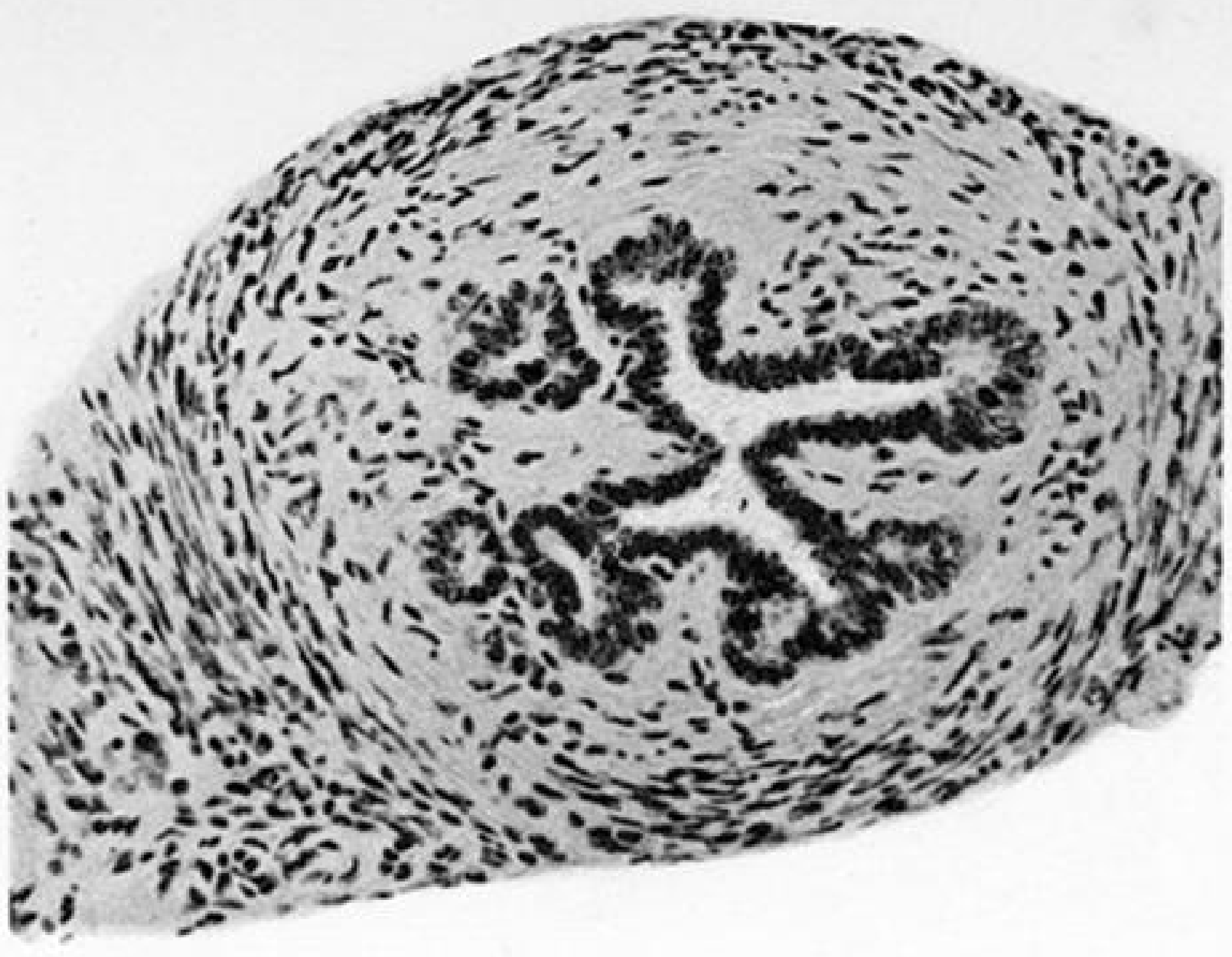

33

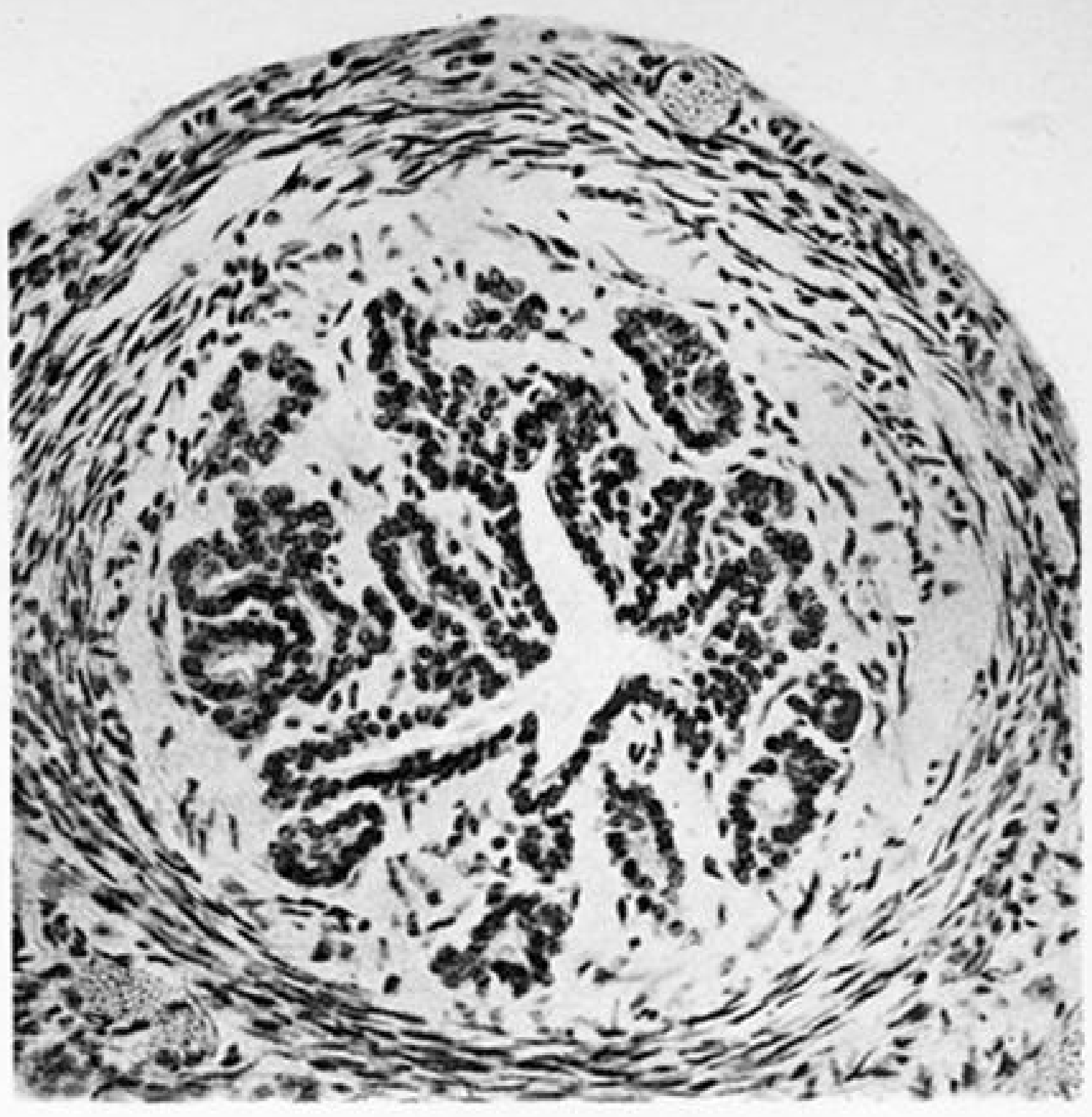

34

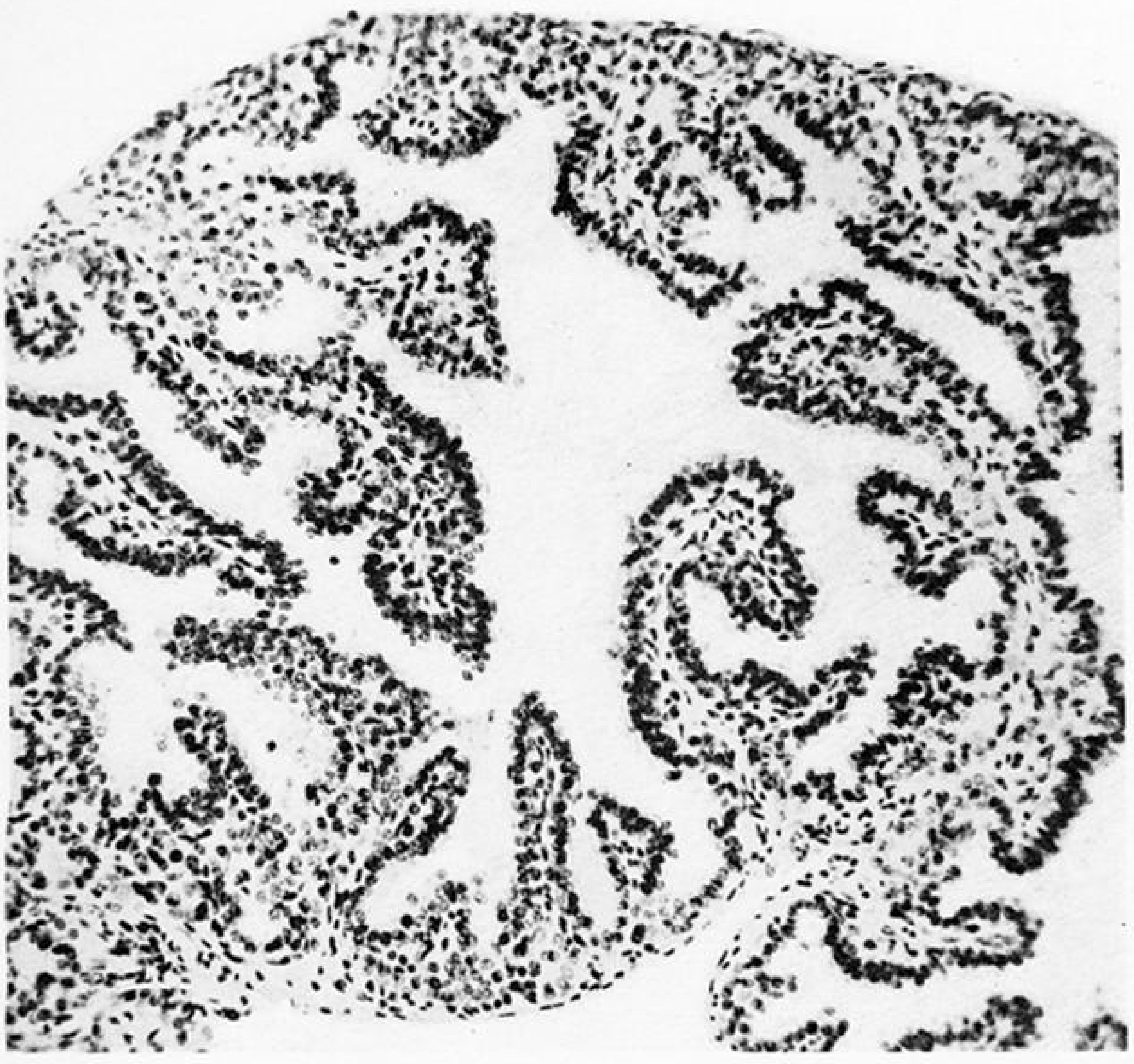

37

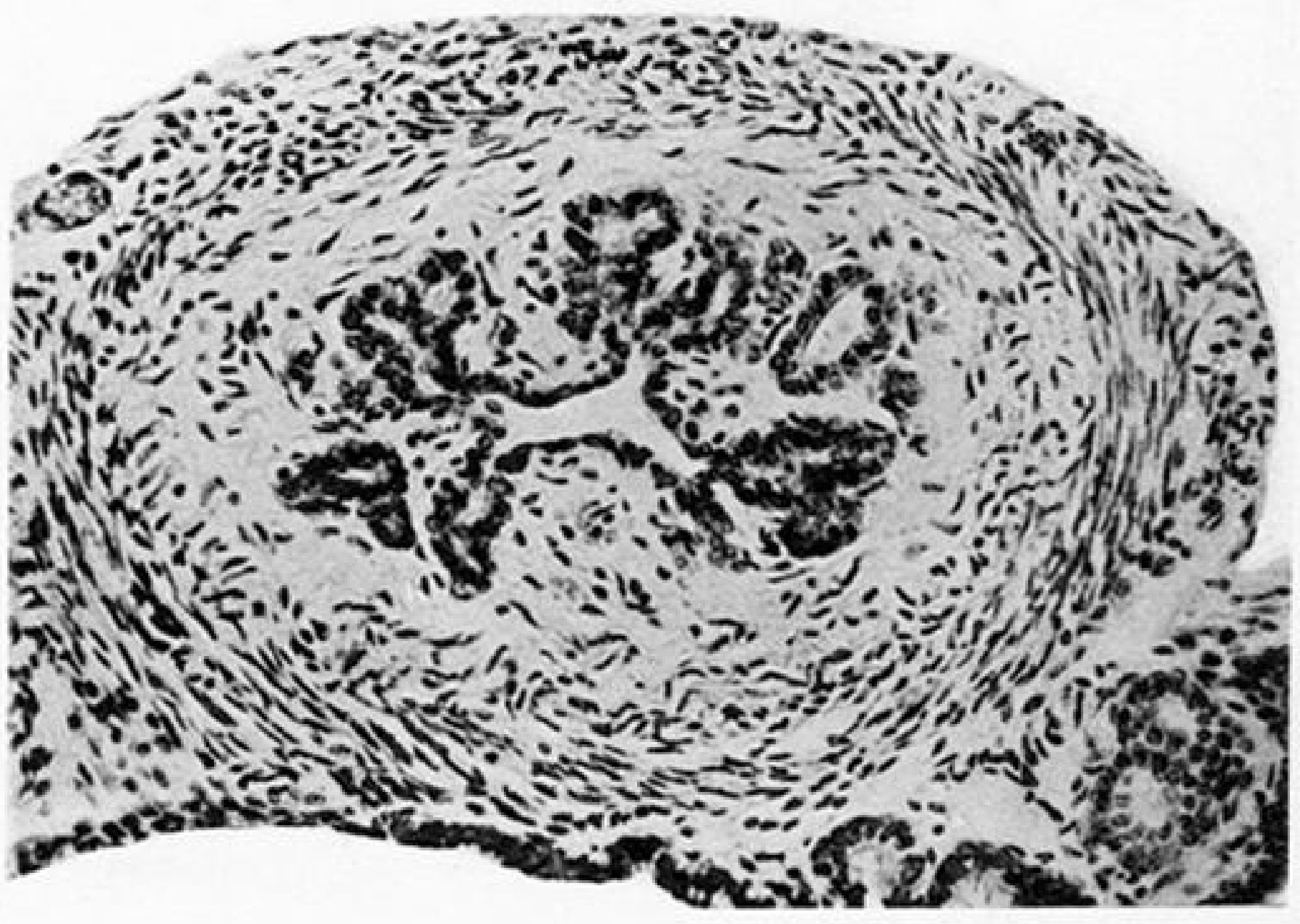

36

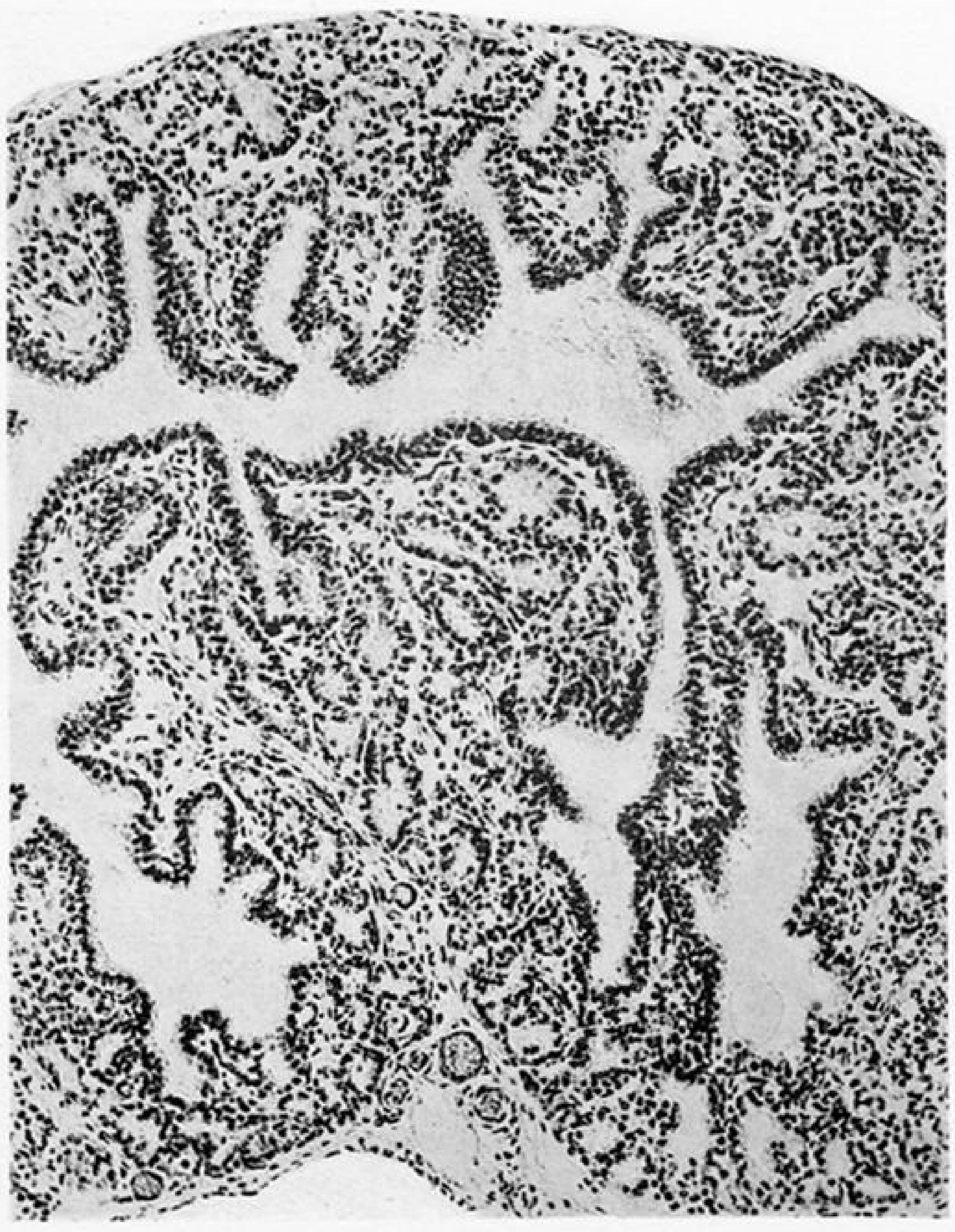

38

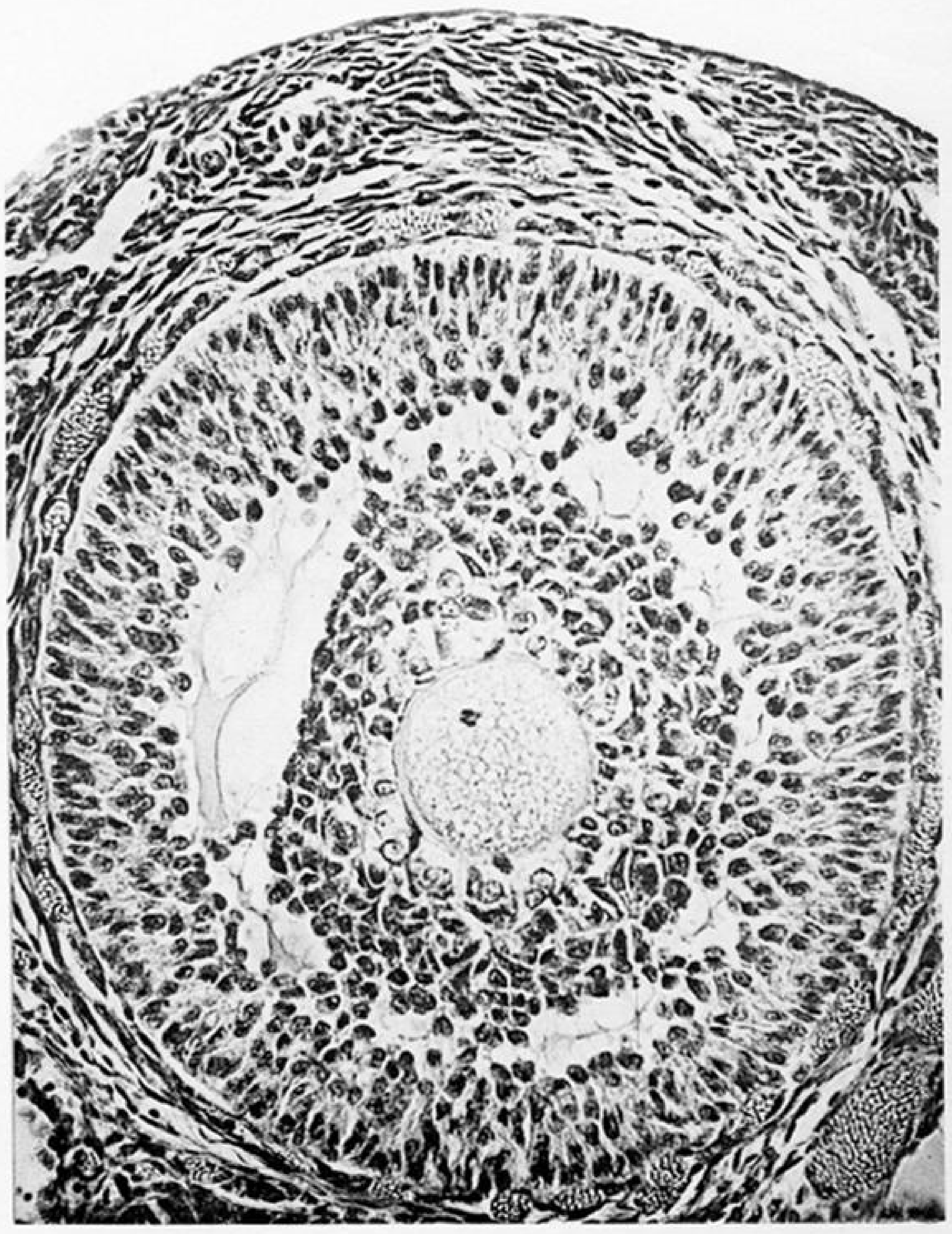

39

PLATE 5

FIG. 33—Photomicrograph of a transverse section of the uterine part of the Fallopian tube of an immature animal (S. 78). × 180.

FIG. 34—Photomicrograph of a transverse section of the uterine part of the Fallopian tube during post-partum œstrus (S. 1033). × 180.

FIG. 35—Photomicrograph of a transverse section of the uterine part of the Fallopian tube of a pregnant animal (S. 983) showing a 4-cell stage in the lumen. × 140.

FIG. 36—Photomicrograph of a transverse section of the uterine part of the Fallopian tube of a parous animal (S. 559) during anœstrus. × 180.

FIG. 37—Photomicrograph of a section of the ovarian part of the Fallopian tube of an immature animal (S. 78). × 152.

FIG. 38—Photomicrograph of a section of the ovarian part of the Fallopian tube during the first œstrus (S. 880). × 112.

FIG. 39—Photomicrograph of a mature follicle in a post-partum œstrous ovary (S. 1033). The ovum contains a 1st polar spindle. The arrangement of the cells of the membrana granulosa and the small size of the antrum can be seen. The intense hyperæmia of the thecal blood vessels is characteristic. × 240.

45



46



41

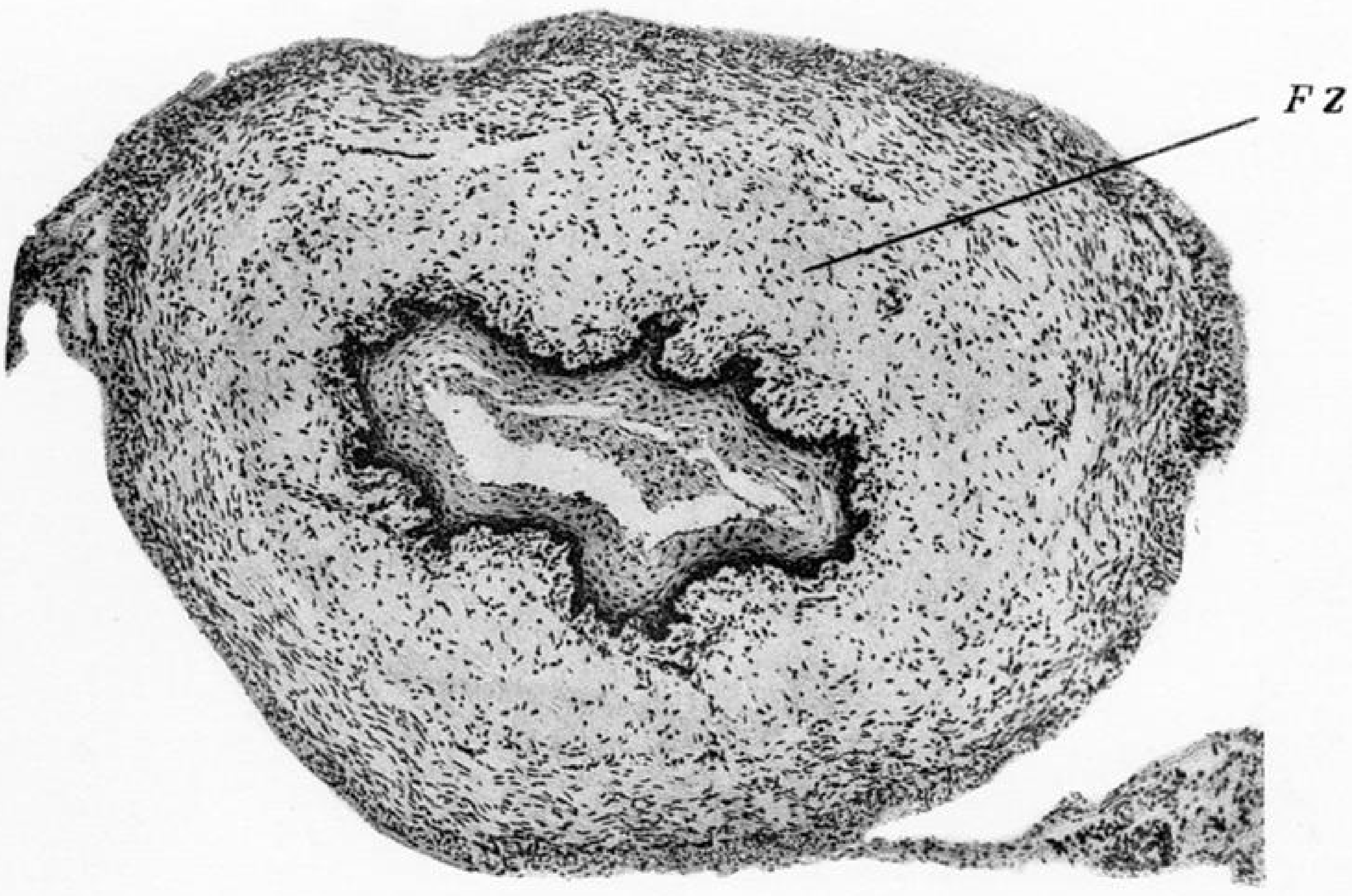

40

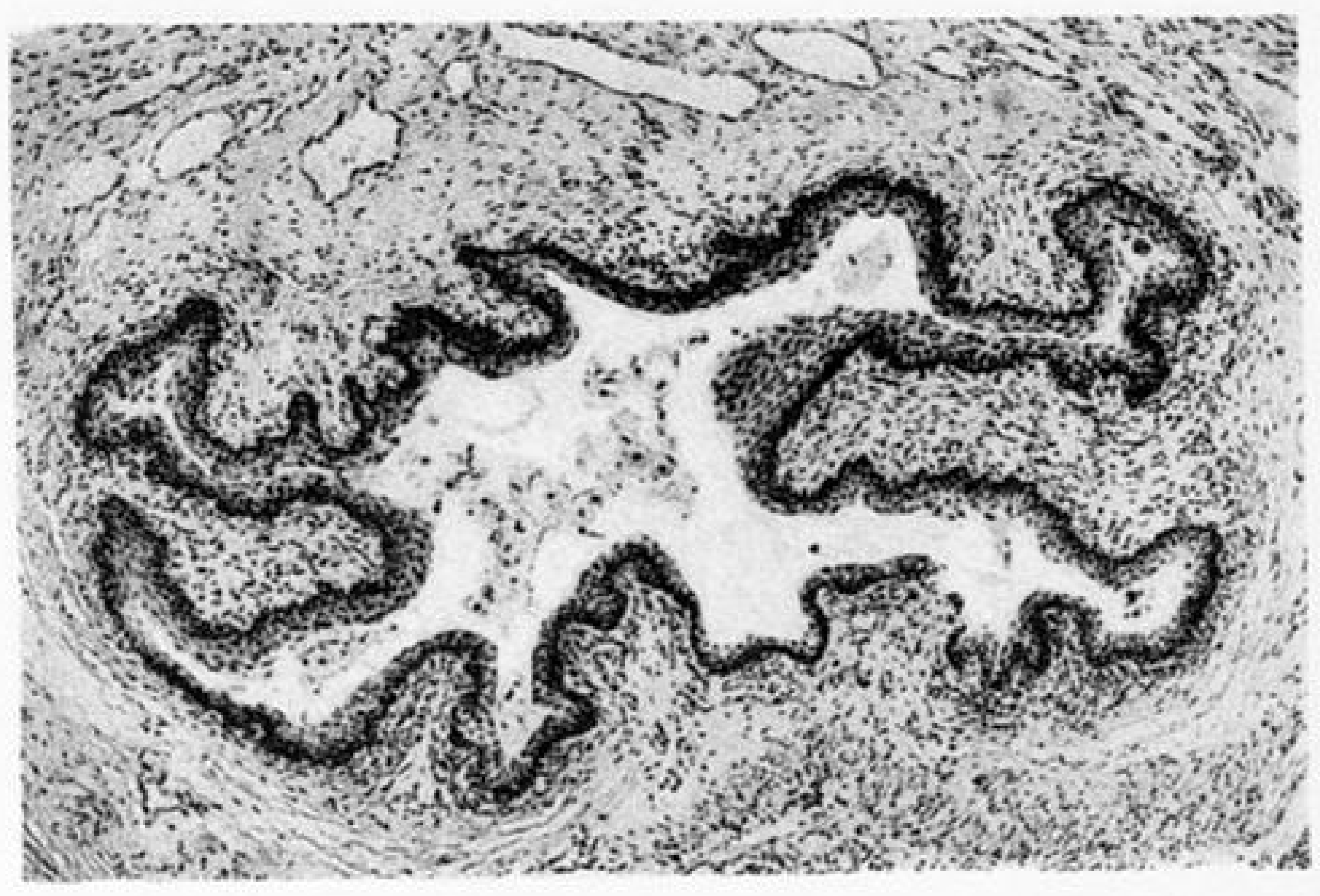

42



43

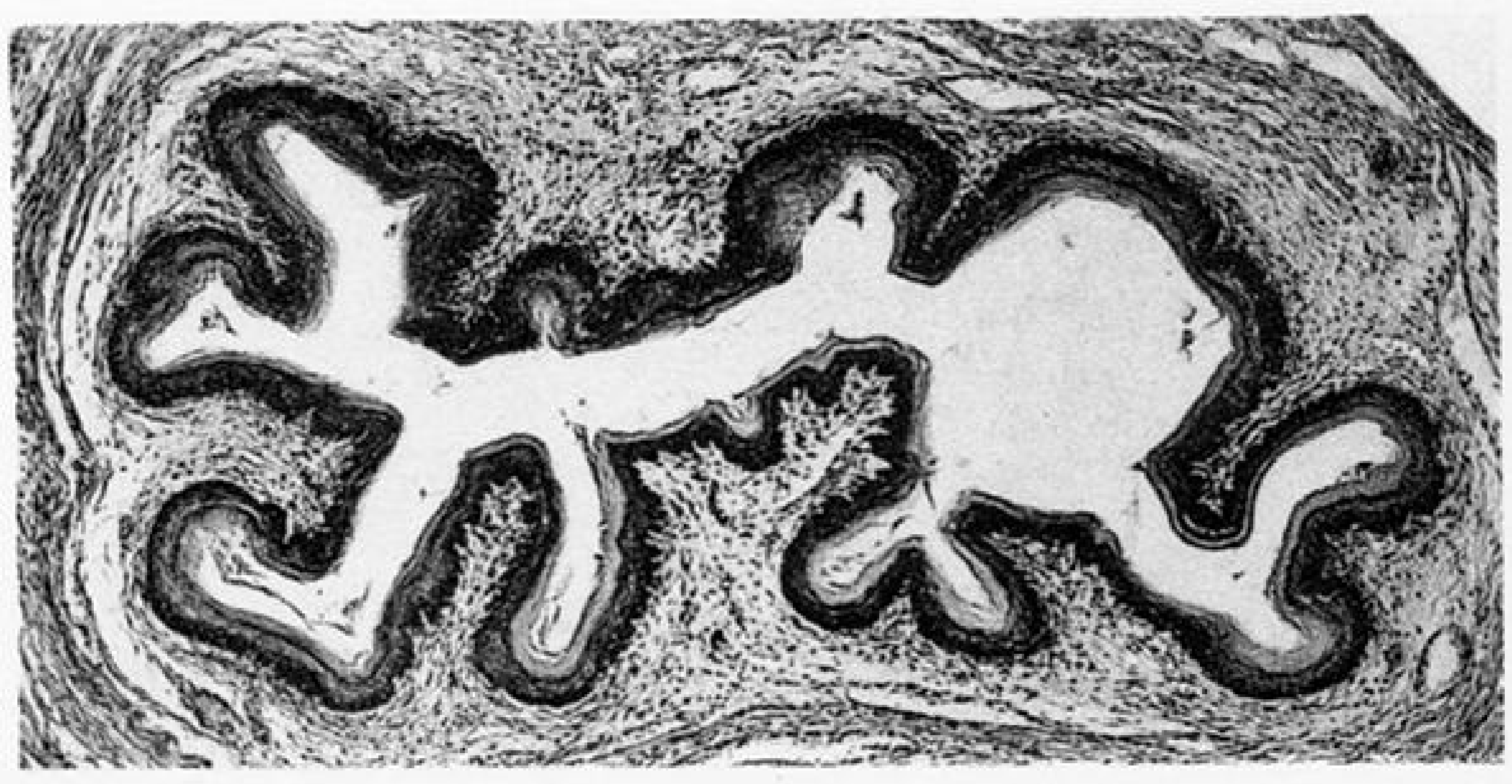

44

PLATE 6

FIG. 40—Photomicrograph of a transverse section of the upper part of the vagina of an immature animal (S. 170) showing the stratified nucleated epithelium and the wide zone of fibrous connective tissue (*FZ*) between the mucosa and the muscularis. × 78.

FIG. 41—Photomicrograph of a transverse section of the lower part of the vagina anterior to the urethral orifice of an immature animal (S. 605). The epithelium is in the form of a solid branching strand (*ES*). × 115.

FIG. 42—Photomicrograph of a transverse section of the lower part of the vagina posterior to the urethral orifice of an immature animal (S. 216). × 50.

FIG. 43—Photomicrograph of a transverse section of the upper part of the vagina during first œstrus (S. 818) showing intense cornification of the epithelium, only the basal layers of which are nucleated. It is folded longitudinally. A mass of semen is present in the lumen. × 42.

FIG. 44—Photomicrograph of a transverse section of the lower region of the vagina during the first œstrus (S. 903) showing the epithelial cornification. × 50.

FIG. 45—Photomicrograph of a part of the vaginal epithelium during post-partum œstrus (S. 1030). A plug of semen is present in the lumen. × 120.

FIG. 46—Photomicrograph of a transverse section of the upper part of the vagina during mid-pregnancy (S. 1001) showing the complete occlusion of the lumen owing to fusion of the epithelial folds. × 57.

49

47

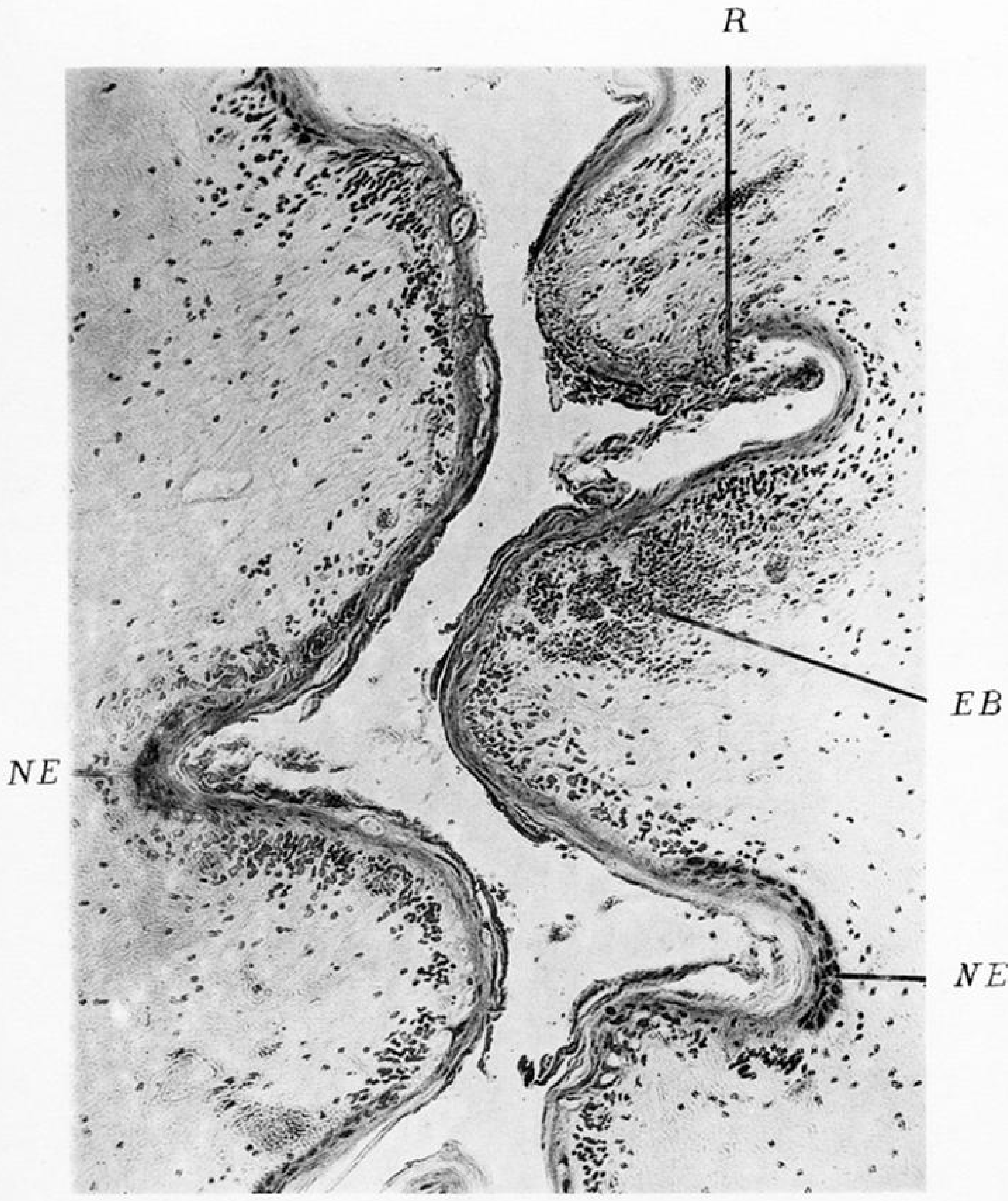

48

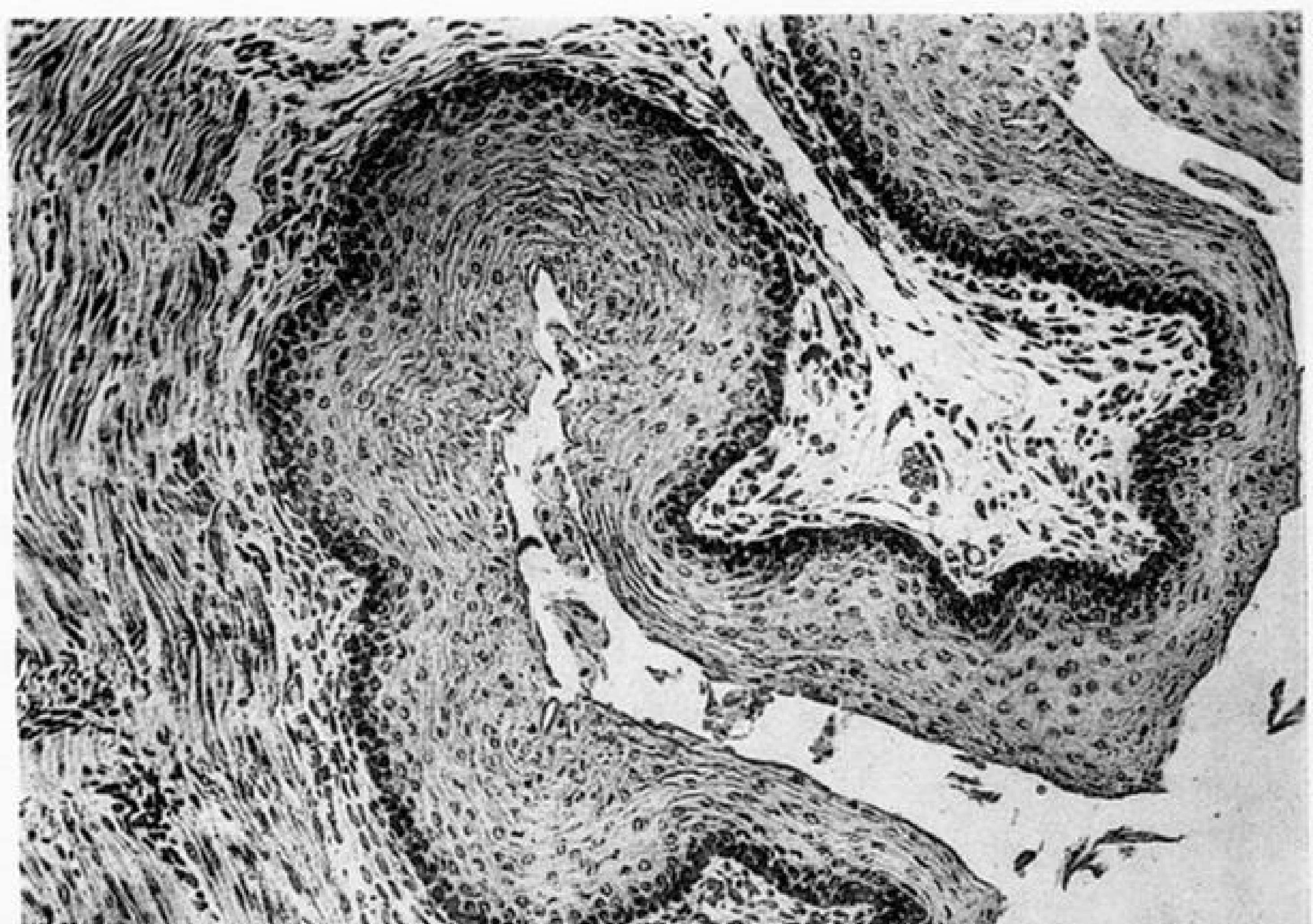

50

PLATE 7

FIG. 47—Photomicrograph of portion of the section shown in fig. 43 showing the cornified epithelium (*CE*), the nucleated epithelium (*NE*) and the semen (*S*) in the lumen. × 128.

FIG. 48—Photomicrograph of a portion of a transverse section of the upper part of the vagina shortly after ovulation (S. 879). The epithelial cornification is so intense that only small patches of nucleated epithelium (*NE*) remain in the basal layers in the valleys between the folds. The mucosa is intensely hyperæmic and extravasation (*EB*) has occurred. The epithelium is thin, owing to the amount which has been sloughed, and it is ruptured in one place (*R*). × 160.

FIG. 49—Photomicrograph of a part of the vagina of an animal during lactation (S. 1214) showing cornification and numerous leucocytes suggesting metœstrus. × 100.

FIG. 50—Photomicrograph of a part of a transverse section of the lower part of the vagina at the end of gestation (S. 949) showing the thick nucleated epithelium. × 100.

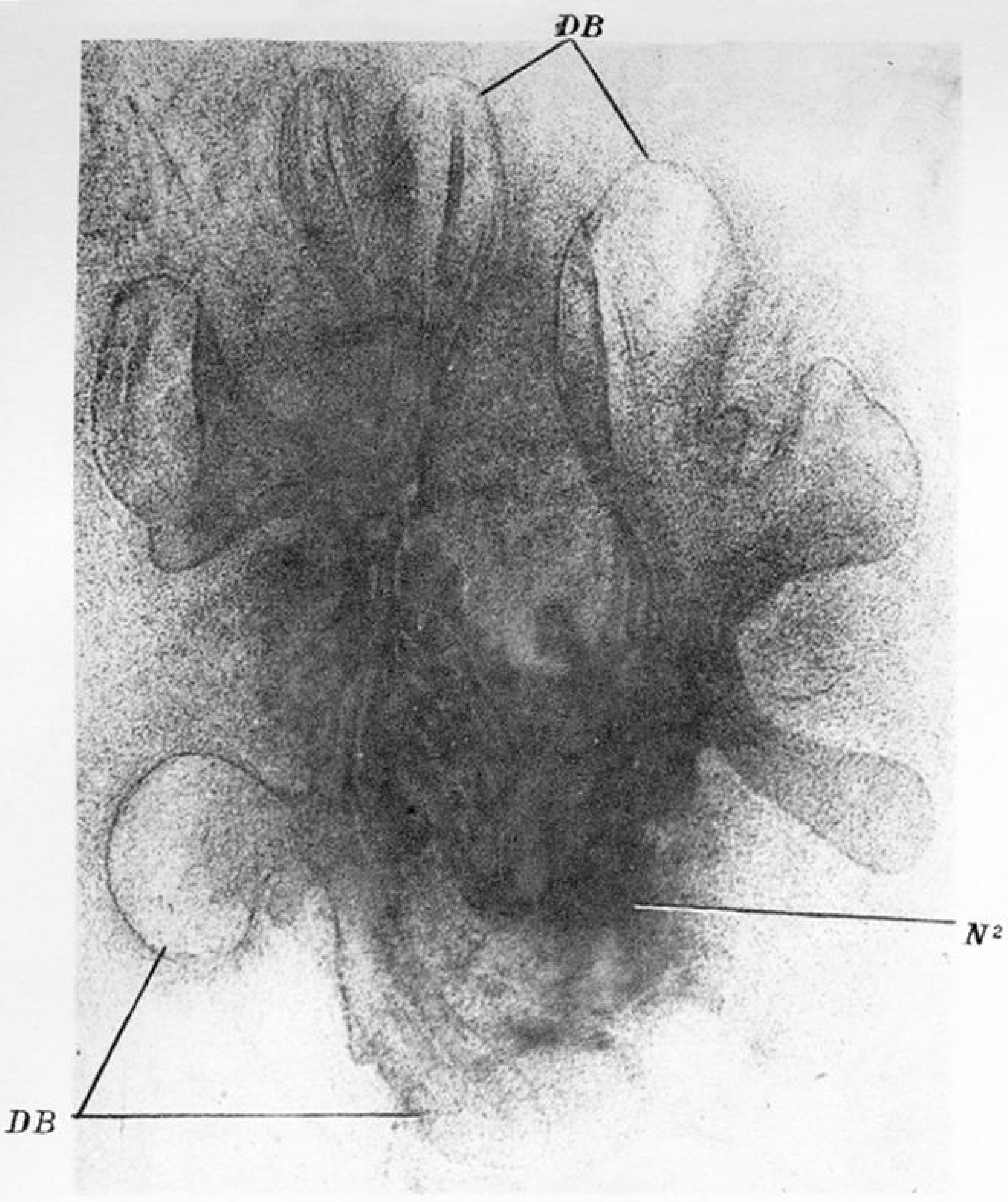

51

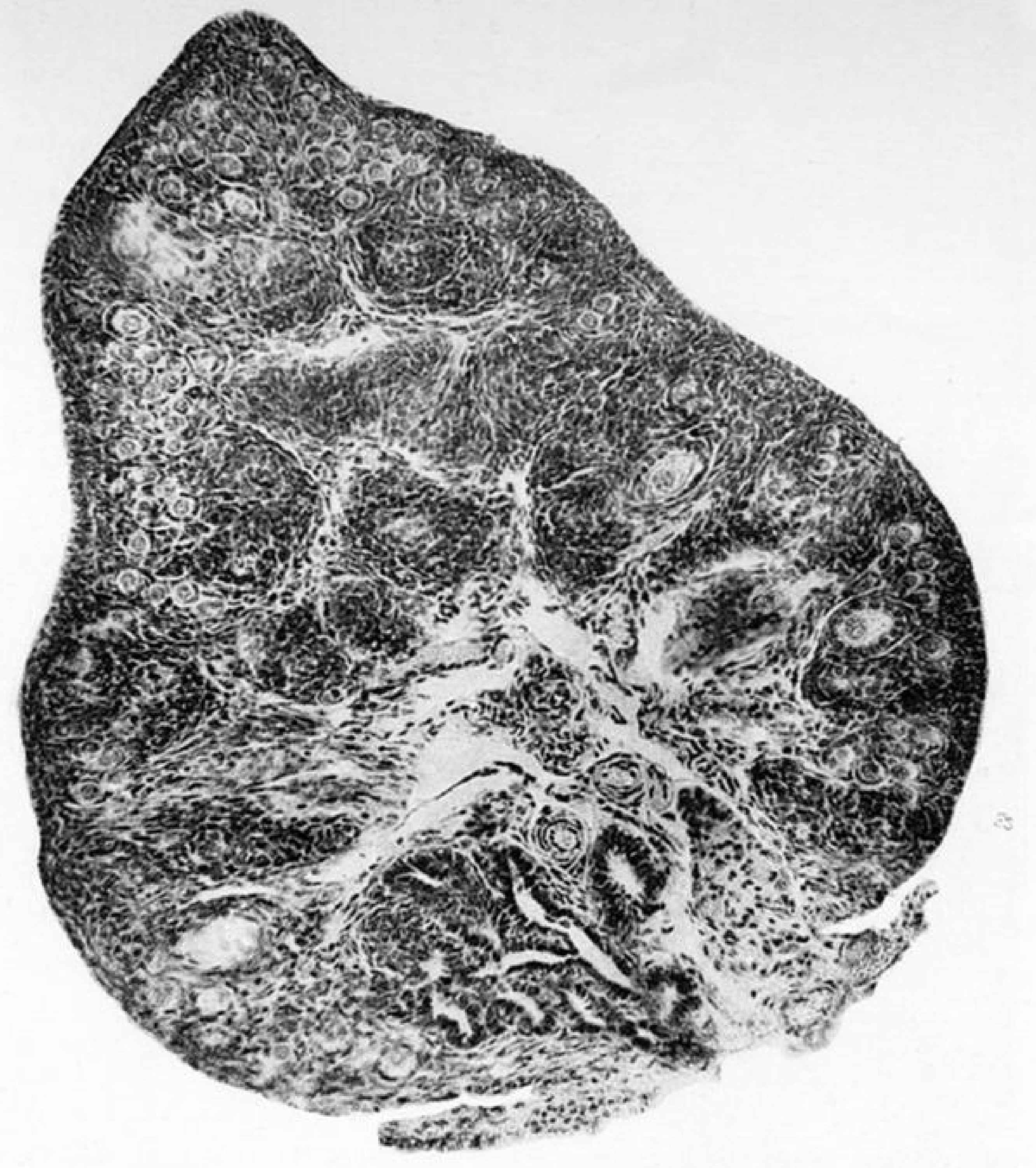

55



54

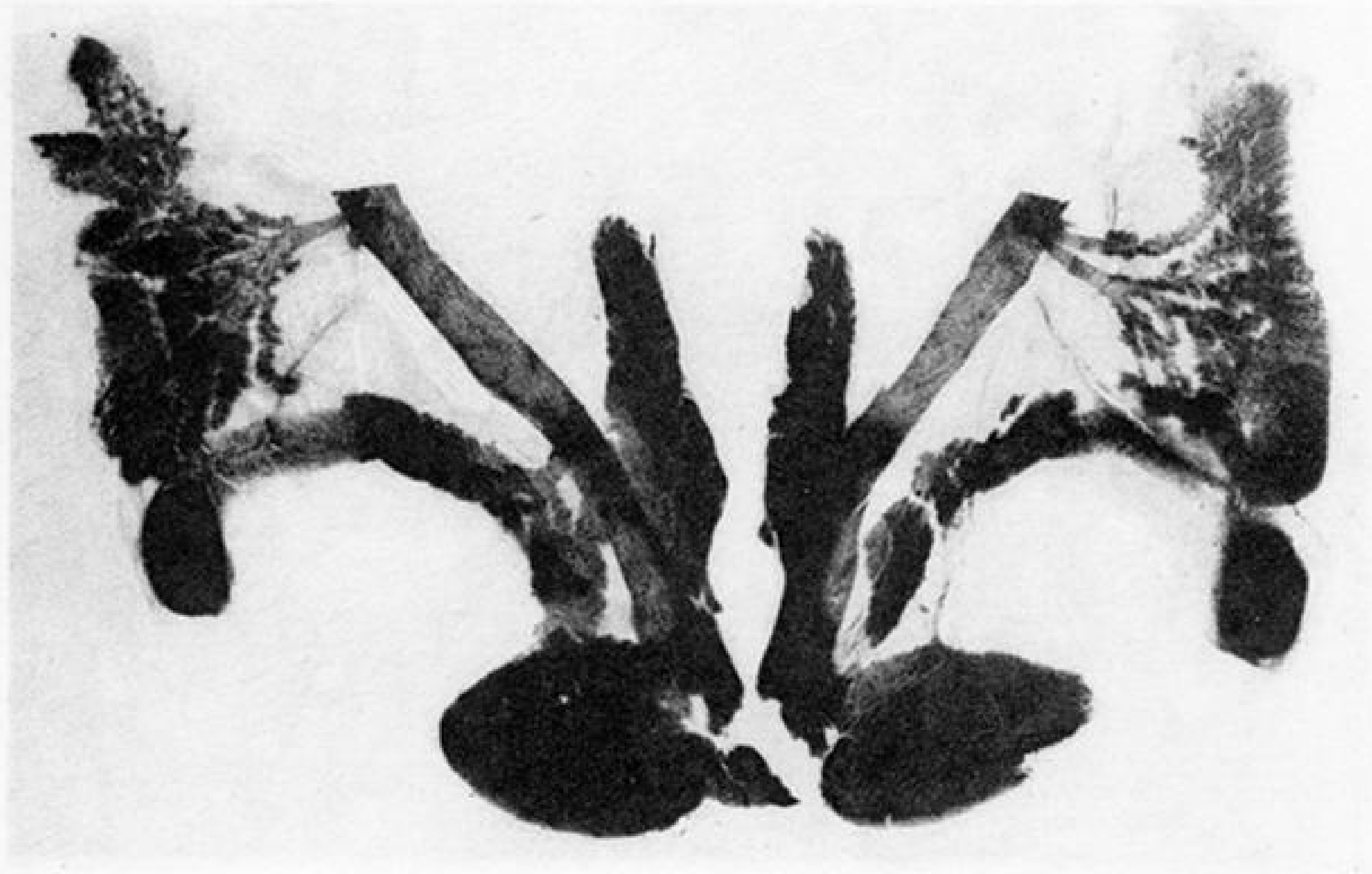

52

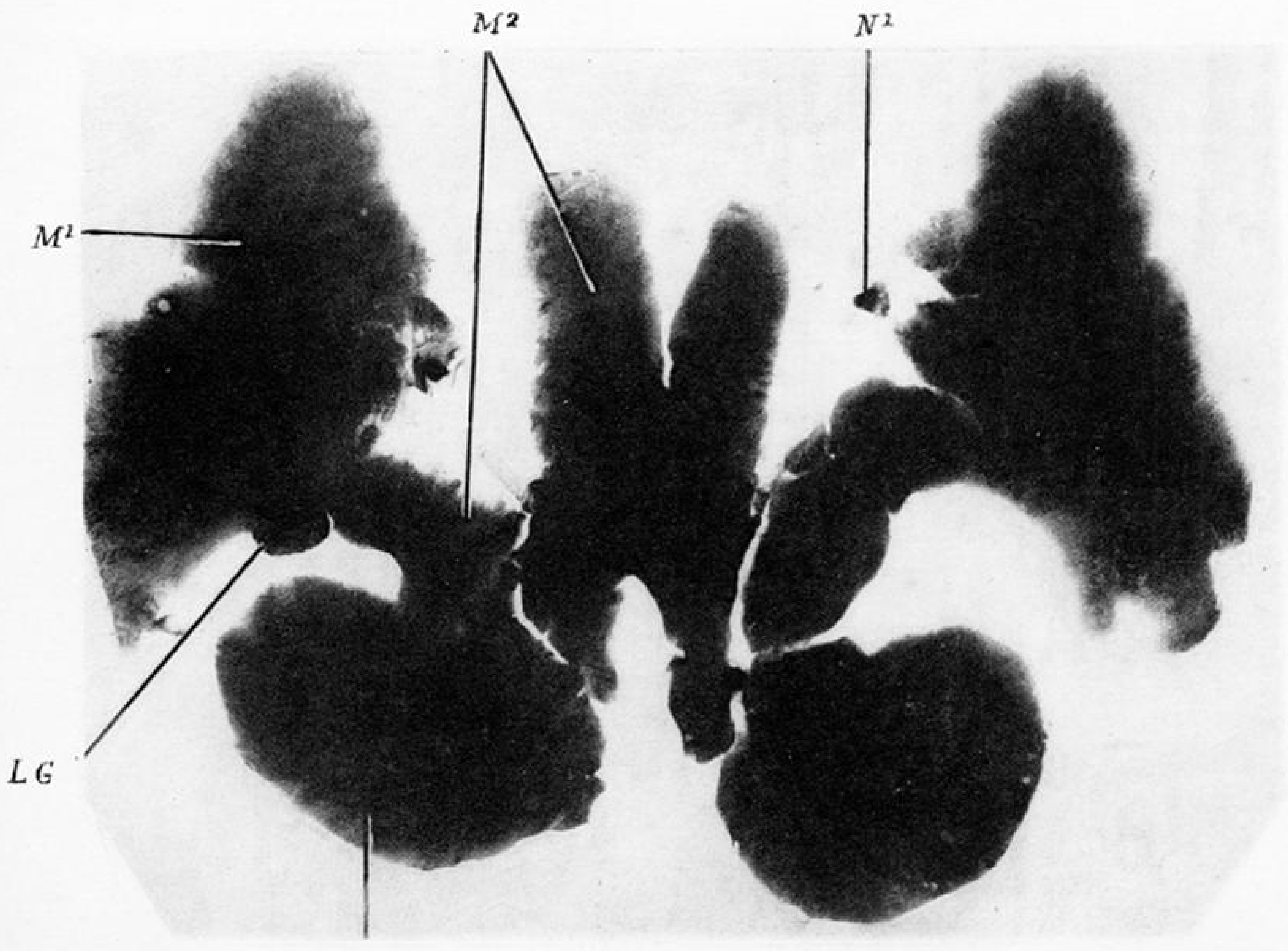

53

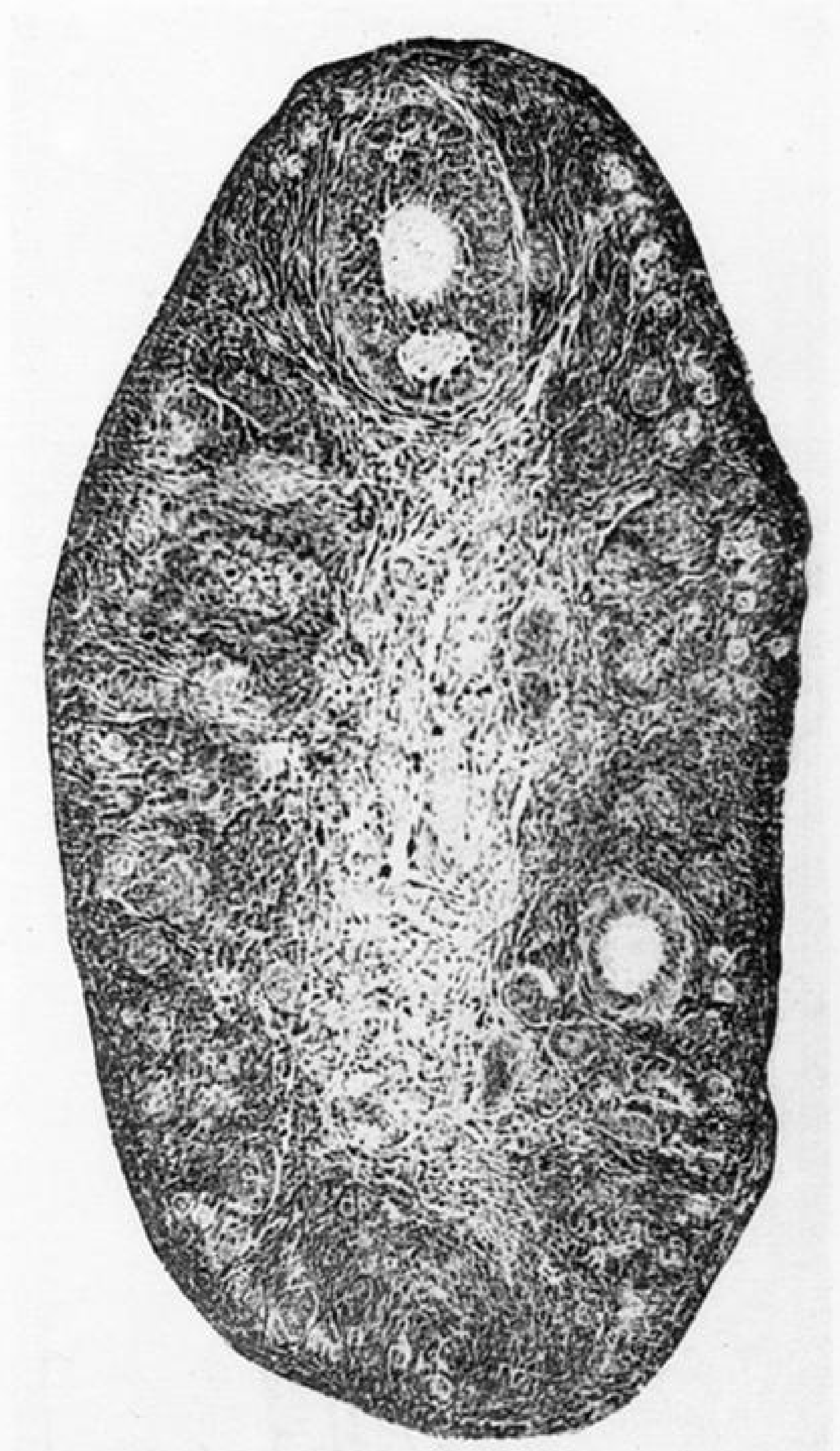

56

PLATE 8

FIG. 51—Photomicrograph of a whole mount of the second mammary gland of a non-parous animal (S. 940) with 8-cell stages of the Fallopian tubes. The bulbous endings (*DB*) of the ducts can be seen. The ducts have only extended some 2 mm from the nipple (N^2). × 33.

FIG. 52—Photograph of a whole mount of the mammary glands of a non-parous animal (S. 989) during late pregnancy. The alveoli can be distinguished in the first pair of glands. × 1·8.

FIG. 53—Photograph of a whole mount of the mammary glands during the height of lactation (S. 1062). M^1 = anterior gland. M^2 = median gland. M^3 = posterior gland. N^1 = nipple of anterior gland. *LG* = lymphatic gland. × 1·9.

FIG. 54—Photograph of a whole mount of the mammary glands of a parous non-lactating shrew (S. 1159) during late pregnancy. The glands have retrogressed but can be distinguished from those of non-parous pregnant animals by their homogeneous appearance. × 1·7.

FIG. 55—Photomicrograph of the ovary of an immature shrew (S. 330) in November showing the pockets of primordial follicles in the cortex. All larger follicles have disappeared. × 147.

FIG. 56—Photomicrograph of the ovary during winter anœstrus (S. 646, February). The ovary is very small and there are very few follicles larger than primordial follicles. × 117.